

## Ability assessment of the craniofacial structures radiological anatomy on panoramic radiography among dental student during pandemic of COVID-19. Ability assessment on OPG among dental student during pandemic of COVID-19

JAKUB MAJEWSKI<sup>1</sup>, DOMINIKA QARASHOULI<sup>2</sup>, ZUZANNA KAZIBUDZKA<sup>2</sup>,  
KLAUDIA CIACH<sup>1</sup>, PATRYCJA KURZAWA<sup>1</sup>, KLAUDIA ORŁOWSKA<sup>1</sup>, JULIA JANAS<sup>3</sup>,  
BARTOSZ CIAPĘŁA<sup>4</sup>, JOLANTA E. LOSTER<sup>2</sup>, ANETA WIECZOREK<sup>2</sup>

<sup>1</sup> Student Research Group, Department of Prosthodontics and Orthodontics, Faculty of Medicine, Jagiellonian University Medical College, Kraków, Poland

<sup>2</sup> Department of Prosthodontics and Orthodontics, Faculty of Medicine, Jagiellonian University Medical College, Kraków, Poland

<sup>3</sup> Student Scientific Society, Department of Integrated Dentistry, Faculty of Medicine, Jagiellonian University Medical College, Kraków, Poland

<sup>4</sup> Department of Integrated Dentistry, Faculty of Medicine, Jagiellonian University Medical College, Kraków, Poland

**Corresponding author:** Aneta Wieczorek, D.D.S., Ph.D.

Department of Prosthodontics and Orthodontics, Institute of Dentistry, Faculty of Medicine  
Jagiellonian University Medical College  
ul. Montelupich 4, 31-155 Kraków, Poland

Phone: +48 12 424 55 36; E-mail: aneta.wieczorek@uj.edu.pl

**Abstract:** Orthopantomography (OPG) is a routine imaging method in dental practice and an essential diagnostic tool in dentistry. However, OPGs are challenging to interpret due to many overlapping structures. Graduates of dental schools should be aware of image distortions caused by various factors and be able to distinguish them from typical structures to make an accurate diagnosis. The aim was to determine the correlation between the knowledge regarding the location of craniofacial structures of the 1st through 3rd-year dental students and the ability to recognize them on OPGs. The study was conducted in 2021 on 131 dental students using the Microsoft Teams program. Each participant had to determine the location of 4 anthropometric points on 4 OPGs. Using proprietary software, the authors determined the Articular angle between them. The researchers performed the statistical analysis. The Bioethics Committee approved the research. The results of students from particular years of studies did not show statistical significance. There was no statistically significant difference between males and females. Only the answers from third-year male students regarding the one Articular angle showed statistically significant differences compared to the rest of the participants.



Recognizing joint structures on OPG is very important from the clinical point of view, although it is often overlooked in diagnostics. Students in the first years of dental school acquire the ability to assess and analyze TMJ on OPGs properly. OPGs have many advantages, including high availability, low cost and low radiation dose. In conclusion we can say that in the first three years of studies, dental students' image assessment skills in the craniofacial radiology field remain the same.

**Keywords:** Orthopantomogram, Dental Radiology, articular angle, panoramic technique errors, education, university.

**Submitted:** 20-May-2024; **Accepted in the final form:** 30-Aug-2024; **Published:** 15-Sep-2024.

## Introduction

Panoramic radiography is the basis for proper medical diagnosis in modern dentistry. The ability to correctly interpret an panoramic radiography requires knowledge of anatomy and all other specialties.

The discussed topic is important for the dentists, in their professional work, evaluate panoramic radiography (PG) images during a dental consultation without the help of qualified radiologists and it should be crucial for dentists to acquire extensive competence in their studies. Panoramic radiography is a standard imaging modality in dental practice and an essential diagnostic tool in dentistry. The PG is usually taken on the first dental appointment [1]. The PG, providing information about the condition of the teeth and surrounding tissues can also be used to assess the temporomandibular joints (TMJs) anatomy [2]. This is important in diagnosing TMJ dysfunction [3]. Nevertheless, PGs are challenging to interpret [1, 4–6]. Overlapping anatomical structures, air or soft tissue shadows, panoramic technique errors during image capture, and artefacts may cause diagnostic errors [1, 7]. Dental graduates should know about image distortions caused by various factors and be able to distinguish them from anatomic structures.

Research studies measuring students' knowledge of radiology head and neck anatomy are rare in the literature. Individual papers on this topic include an ability assessment in some universities worldwide [8]. We needed to conduct such a study at our University and compare the results obtained with international reports. We should determine students' competence level and distinguish factors influencing it. In the future, this study may influence the modification of the curriculum and increase teaching effectiveness in this area. At our University, attempts were made to assess the competence of analyzing joint structures on PGs in the context of determining the articular angles among prosthodontists, doctors specializing in the field of dental prosthetics and general dentists as well as among students of the fifth year of dental studies [9, 10]. We decided it is also worth examining students' competencies in the first, second and third years of dental studies.

Previous research indicate disparities in the ability to recognize anatomical structures among students at subsequent stages of learning. Students' knowledge constantly evolves due to the learning curve. This extended process of learning theoretical concepts and acquiring practical skills is reflected in the ability to interpret panoramic radiographs. At our University, anatomy is taught from the first year of dental studies. First-year students learn the basics of normal anatomy. Then, in the second year of studies, they become familiar with the principles of operation of X-ray machines during medical biophysics classes. Later, in the third year of studies, they participate in dental radiology classes and interpret PGs. We wanted to know their skills in panoramic radiography assessment students acquired in the classes mentioned above.

## Study objective

Our study aimed to determine the correlation between the knowledge of 1st–3rd year students of our Faculty of Medicine and Dentistry of the University about the location of the structures of the facial part of the skull and the ability to recognize them on PGs.

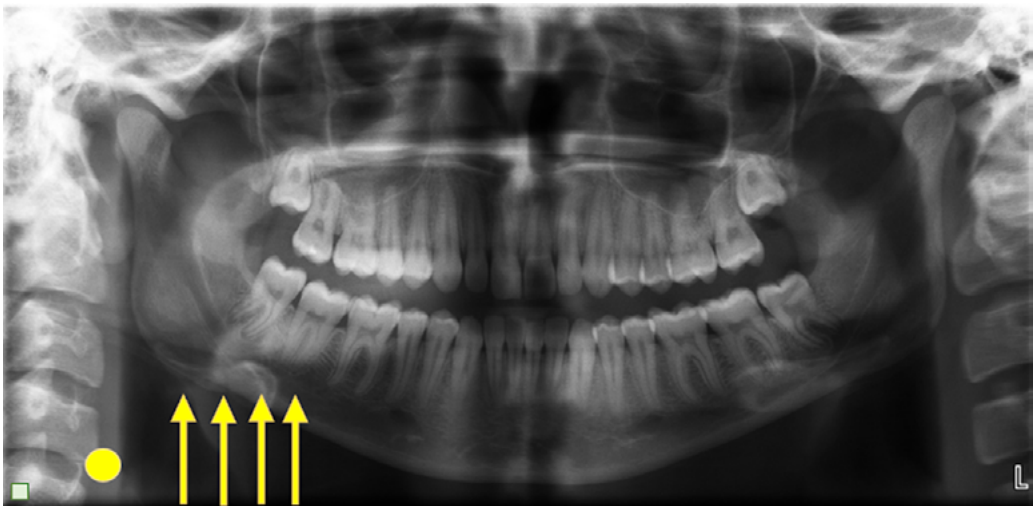
## Material and Methods

The study was carried out in March and April 2021 after prior approval of the Bioethics Committee No. 1072.6120.337.2020.

The study material consisted of students of the medical and dental faculty of the Faculty of our University from the first till third year of studies in the academic year 2020/2021. The study was conducted in three rounds. Participation in the study was voluntary. Participants were informed about the study's aims and objectives and gave written consent.

PGs of four individuals, male and female, approximately 18 years of age, without anatomic abnormalities within the TMJ, were randomly selected. The study was funded by the Ministry of Science and Education grant, financed by the Ministry of Science and Higher Education No. N N403 589138 [10, 11]. All photos were taken using the ProMax® scanner (Planmeca, Helsinki, Finland 2005) by the same technician, with the same parameters (electric current [14.0 mA] and voltage [70 kV]). Before taking the PG, the subjects were positioned according to their Frankfurt plane parallel to the floor.

Selected images were entered into Microsoft Word and locked so study participants could not edit them. Individual photos were placed on separate pages of Microsoft Word. The pages of the document were set horizontally. Four identical arrows and one yellow dot indicating the analysed side have been added to each panoramic radiography (Fig. 1). The Microsoft Word file consisted of 5 pages. Each participant was supposed to mark the Porion like points (the highest point of



**Fig. 1.** Sample PG prepared for students' assessment. The dot indicates the side of the head and neck to interpret. Arrows are used to mark their choices. Arrows could be moved freely by the participants.

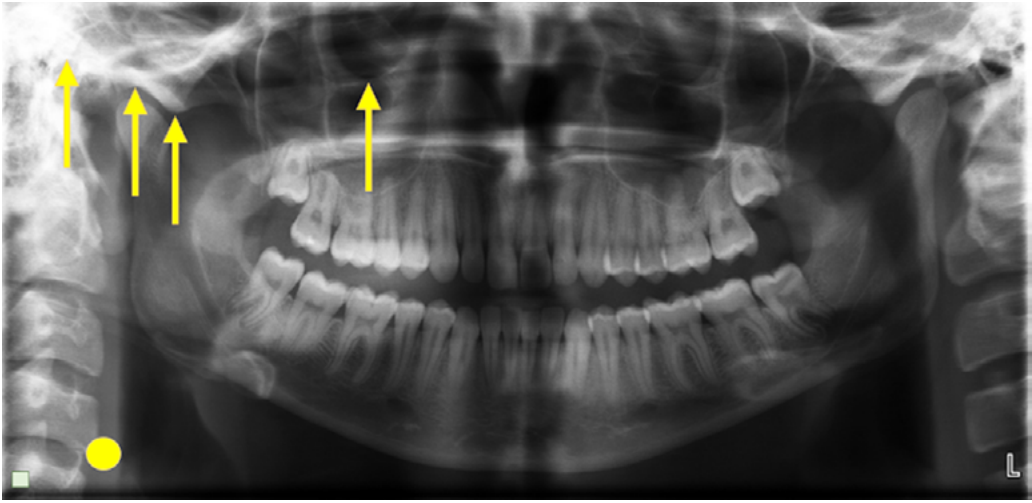


Fig. 2. Sample PG with points marked by a student.

the bony auditory opening), the Orbitale like points (the lowest point of the lower orbital rim), the deepest point of the mandibular fossa and the most convex point of the articular tubercle. We placed a yellow dot on the PG to indicate which side of the head and neck should be assessed. The yellow dot in each PG photo was on the side of the right TMJ. Yellow arrows were available for the participants to mark their choices.

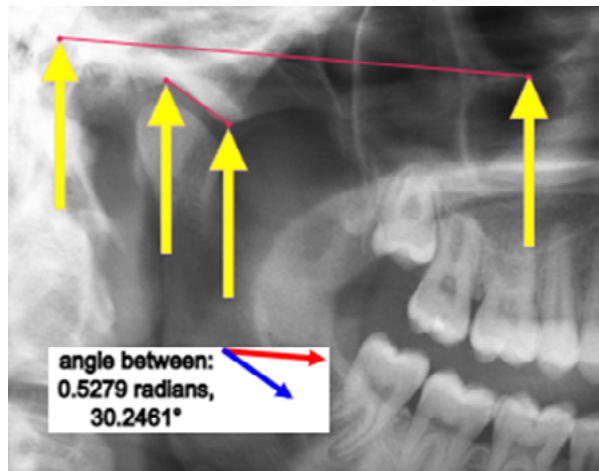
Participants contacted the researcher using the Microsoft Teams platform. Meetings followed a single protocol. Firstly, the researcher (JM) defined the points the participants had to mark on the PG. Sample photos were used to demonstrate the exercise. In the next step, the study participants were asked to complete the exercise by marking the indicated points, saving their image and sending it to the study's authors, for which ten minutes were allotted (Fig. 2).

The files obtained from the study participants were imported into an IT program prepared especially for this purpose. A web application was used, which was created using JavaScript and the popular p5.js library. We chose it because of the ability to upload any graphic file. This library allowed us to select four points and determine the size of the articular angle between two straight lines created by them. It allowed us to obtain the results that were the basis of our statistical analysis. The researchers drew one straight line between the Porion like point and Orbitale like points, designated by the participants. The second straight line connected the deepest point of the mandibular fossa and the lowest point of the articular eminence. The program determined and calculated the articular angles between the two straight lines (Fig. 3). The obtained articular angles were numbered from 1 to 4 according to the numbering of the PGs.

At the same time, the study's authors (JM, KO) performed the experiment by marking their answers on the assessed images three times, connecting the points with straight lines and calculating the obtained articular angles. These scores were averaged and used as a benchmark for student evaluation. Previously, these indicated points were verified by project supervisors (AW and JEL).

The results were summarized in a table and statistically analyzed using the R program, version 4.1.2.

**Fig. 3.** An example of an articular angle determined by the program.



The data of the research was analyzed in 6 steps. The below relationship were analyzed:

1. The results of people from the 1st, 2nd and 3rd year, and the results of the authors.
2. Women's results from the 1st, 2nd and 3rd year, and the results of the authors.
3. The results of men from the 1st, 2nd and 3rd year, and the results of the authors.
4. The results of all women versus the authors' results.
5. The results of all men versus the authors' results.
6. The results of all persons and the results of the authors.

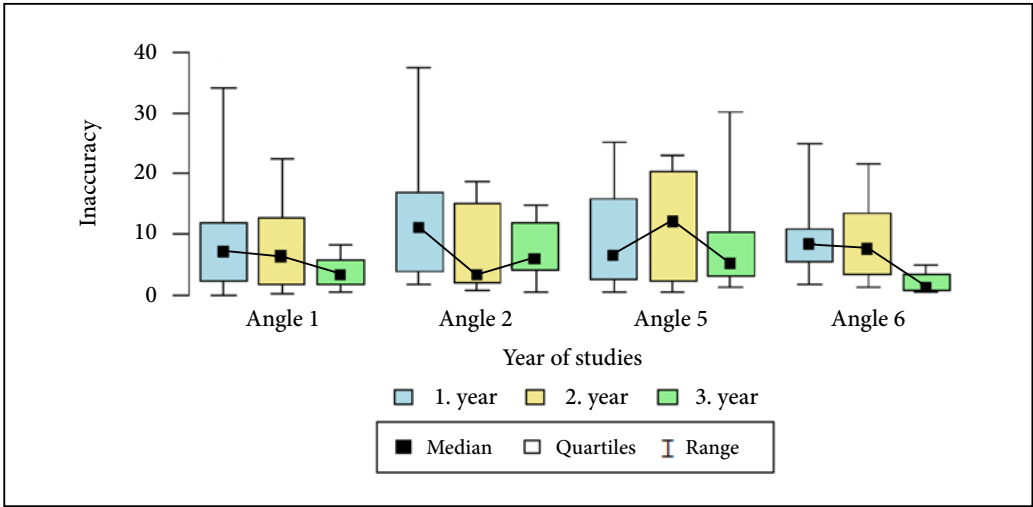
A significance level of 0.05 was adopted in the analysis. The statistic software of R, v. 4.1.2 [12]. The following statistical tests were performed: Chi-square test, Kruskal–Wallis test, and Mann–Whitney test.

## Results

The study involved 131 students of dentistry at the Faculty of Medicine from the first three years of study in the academic year 2020/2021. Forty-two people (32.06% of the respondents) participated in the first year of studies, 48 people (36.64% of the respondents) from the second year, and 41 people (31.30% of the respondents) from the third year. Study participants consisted of 100 women (76.34% of the respondents) and 29 men (22.14% of the respondents). 2 participants did not agree to give their gender (1.53% of the respondents).

The total results of all women and all men from the first, second and third years of studies did not show a statistically significant difference. Our results in the Kruskal–Wallis test were, respectively,  $p = 0.61$ ,  $p = 0.5$ ,  $p = 0.094$ , and  $p = 0.283$  for subsequent articular angles (Fig. 4).

Considering the articular angles obtained only by women participating in the study, no statistically significant differences were found from individual years of dental studies (Table 1). However, in the analysis of men from particular years, it was shown that students from the 3rd year obtained statistically different results than those of the first and second years (Table 2). Also, the panoramic technique error in determining articular angle 4 was statistically significantly lower in men from the third year than in women from year 3, which shows that the results of the group mentioned above differed most significantly from the results of people from the entire study (Table 3).



**Fig. 4.** The graph shows the combined results of all women and all men who participated in the study. Kruskal–Wallis test  $p < 0.05$ . Articular angle 1 —  $p = 0.61$ , Articular angle 2 —  $p = 0.5$ , Articular angle 3 —  $p = 0.094$ , Articular angle 4 —  $p = 0.283$  for consecutive articular angles.

**Table 1.** Results of all women who participated in the study for articular angles 1, 2, 3, and 4. Kruskal–Wallis test  $p < 0.05$ .

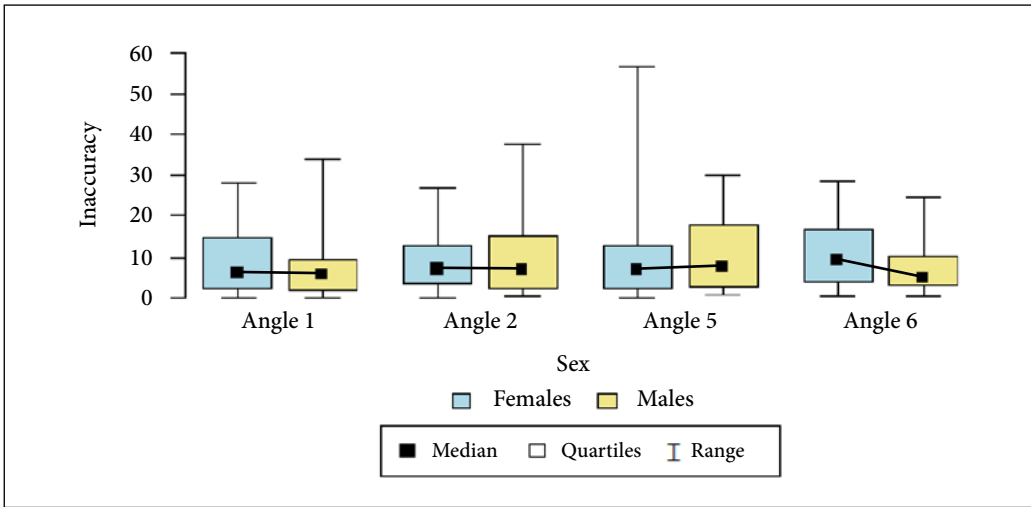
Inaccuracy		Year of studies			p
		1. year (N = 22)	2. year (N = 38)	3. year (N = 34)	
Angle 1	mean ± SD	9.51 ± 6.84	9.43 ± 7.79	8.13 ± 7.46	p = 0.735
	median	9.4	9	5	
	quartiles	2.69–15.47	2.3–14.49	2.46–11.96	
Angle 2	mean ± SD	8.6 ± 5.04	8.29 ± 7.16	9.62 ± 7.31	p = 0.627
	median	7.14	6.68	8.19	
	quartiles	4.78–13.81	2.57–10.89	3.59–15.53	
Angle 5	mean ± SD	7.84 ± 8.39	13.26 ± 13.59	8.56 ± 9.12	p = 0.102
	median	6.26	10.92	5.15	
	quartiles	1.25–11.88	4.09–15.15	2.15–12.45	
Angle 6	mean ± SD	7.42 ± 6.24	11.82 ± 8.39	10.63 ± 6.52	p = 0.122
	median	5.27	13.37	9.54	
	quartiles	3.04–10.8	4.31–17.97	6.07–15.09	

**Table 2.** Results of all men who participated in the study for articular angles 1, 2, 3, and 4. Kruskal–Wallis test and post-hoc analysis (Dunn test)  $p < 0.05$ .

Inaccuracy		Year of studies			p
		1. year — A (N = 11)	2. year — B (N = 8)	3. year — C (N = 7)	
Angle 1	mean ± SD	10.28 ± 10.87	8.64 ± 8.66	3.92 ± 2.8	p = 0.42
	median	7.03	6.34	3.29	
	quartiles	2.48–11.96	1.71–12.73	1.9–5.85	
Angle 2	mean ± SD	12.23 ± 10.54	7.71 ± 7.9	7.63 ± 5.39	p = 0.534
	median	10.86	3.22	6	
	quartiles	4.06–16.87	2.05–14.98	4.2–11.98	
Angle 5	mean ± SD	9.23 ± 8.71	11.62 ± 9.26	9.01 ± 10.01	p = 0.835
	median	6.4	12.01	5.07	
	quartiles	2.73–15.77	2.33–20.47	3.04–10.31	
Angle 6	mean ± SD	9.99 ± 6.82	9.43 ± 7.8	2.1 ± 1.78	p = 0.006 *
	median	8.4	7.42	1.07	
	quartiles	5.56–10.86	3.28–13.52	0.72–3.4	

**Table 3.** Results of all third-year students who participated in the study — articular angles 1, 2, 3, and 4. Kruskal–Wallis test  $p < 0.05$ .

Inaccuracy		Sex		p
		Females (N = 34)	Males (N = 7)	
Angle 1	mean ± SD	8.13 ± 7.46	3.92 ± 2.8	p = 0.238
	median	5	3.29	
	quartiles	2.46–11.96	1.9–5.85	
Angle 2	mean ± SD	9.62 ± 7.31	7.63 ± 5.39	p = 0.575
	median	8.19	6	
	quartiles	3.59–15.53	4.2–11.98	
Angle 5	mean ± SD	8.56 ± 9.12	9.01 ± 10.01	p = 0.852
	median	5.15	5.07	
	quartiles	2.15–12.45	3.04–10.31	
Angle 6	mean ± SD	10.63 ± 6.52	2.1 ± 1.78	p < 0.001*
	median	9.54	1.07	
	quartiles	6.07–15.09	0.72–3.4	



**Fig. 5.** The graph shows the results of all men and women who participated in the study for Articular angles 1, 2, 3, and 4. Kruskal–Wallis test  $p < 0.05$ .

If we consider comparing the results of all men with all women in the analysis, no statistically significant difference was obtained either (Fig. 5). Comparison of men and women only among persons from 1st and 2nd year also gave the same result.

## Discussion

The results obtained in our study show that in the first three years of dental studies, students' skills in assessing panoramic radiography of the facial part of the skull remain at the same level. We consider several reasons that caused the results mentioned above. One of them is that students' knowledge in the first three years of dental studies is constantly evolving due to assimilating information. At the our University, the first three years of studies in medicine and dentistry provide much new knowledge. In the first year of studies, students learn the basics of normal anatomy and distinguish the anatomical structures of TMJ for the first time on drawings in anatomical atlases and during exercises on cadavers. In the second year, medical biophysics classes teach about the construction and operation of X-ray machines and all the techniques. In contrast, in the third year of studies, students analyse and describe various X-ray images, including PGs, during dental radiology classes. During the first years of studies students do not yet have the experience to notice all the essential details. Students learning the analysis of PG photos likely pay insufficient attention to the appearance of the TMJ, focusing all their interest on other structures visible in the photo, such as teeth, periodontium and surrounding bone structure. Another challenge the students face is that the PG is a complex projection of the oral cavity, with overlapping anatomical structures and image distortions, which various panoramic technique errors may aggravate. These include but are not limited to: incorrect positioning of the patient (anterior teeth set behind the groove in the bite block, chin protruding/retracted/too low/too high, head twisted, patient set too forward / backwards, tongue set too low, patient not keeping still), presence of a foreign body



(jewellery in ears/nose/lip/tongue/eyebrows, glasses, dentures or incorrectly placed lead apron), panoramic technique errors (double exposure, underexposure, incorrect setting of the radiation recorder/X-ray tube, incorrect setting of exposure parameters) [8, 13].

A similar study was carried out at Yeditepe University in Istanbul to assess dental students' knowledge of panoramic radiographs [8]. The authors referred to the guidelines of the American Commission on Dental Accreditation, according to which "Dental graduates must be competent in the interpretation of periapical and panoramic radiographs" [14]. The study's authors opted for medical school authorities to develop strategies to implement this approach in the regular curriculum, as individual university syllabi should be compatible with international standards. We also use this approach at our university. In their study, the authors from Istanbul asked to mark the articular eminence and the condylar process among the articular structures. The results turned out to be surprising because the articular eminence was marked correctly by 31.6% of third-year students and by 0% of fourth- and fifth-year students. The condylar process was correctly marked by as many as 94.7% of third-year students, 43.5% of 4th-year students and 75.6% of 5th-year students and all results were statistically significant in the Kruskal–Wallis test. Due to the impressive results of third-year students, the authors put forward the thesis that students are more successful in interpreting PGs with information obtained recently. Dental radiology classes at the University of Istanbul, like at our University are held during the third year of studies. Compared to our results, it can be concluded that students' knowledge of interpreting PG photos during the first three years of study does not change. This may be a signal to modify the teaching plan for dental radiology classes.

Authors from the United States also drew attention to the joint structures in the PGs. Razmus *et al.* conducted a study on the knowledge of dental graduates from 22 American medical universities from different regions of the USA [15]. The authors asked the participants, to mark the articular eminence and the condylar process on the photographs. The frequency of references by various researchers to joint structures in PGs suggests striving for pantographic images to be analysed more thoroughly. From a general medical perspective, PG can be used to assess the condition of the teeth and surrounding tissues, joints, sinuses, eye sockets, etc.

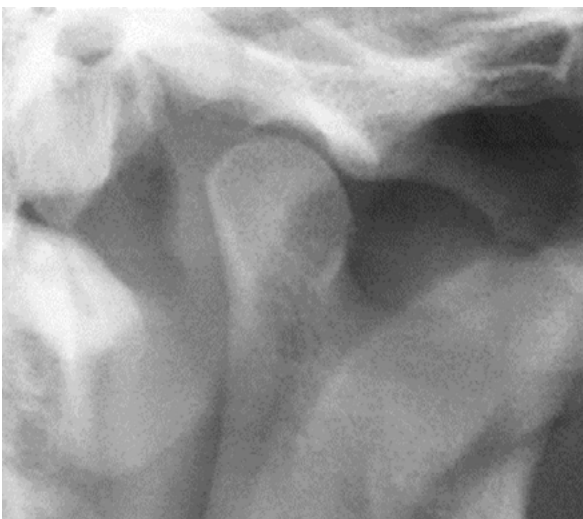The temporomandibular joint is often overlooked in the diagnosis. This is a big mistake because radiographic imaging can be used to confirm or rule out conditions in this joint and to gather additional information when the clinical diagnosis is ambiguous or unclear. Hunter and Kalathingal presented the advantages and disadvantages of each type of TMJ imaging and examples of diseases that X-ray can diagnose [16]. The PG image is the base of diagnostics in dentistry. It is a screening examination of the facial part of the skull. Thanks to its analysis, combined with a reliable clinical examination and instrumental analysis, we can make an accurate diagnosis of joint diseases or possibly decide to extend the diagnostics by CBCT imaging, USG or MRI. This was confirmed by tests conducted at the Department of Prosthodontics of the Jagiellonian University Medical College [3]. On the PG image, we can primarily assess the morphology of bone structures. The articular tubercle is assessed as high/low/steep/flat, the shape of the condylar process as convex/flat/angular/round, and the joint cavity as shallow/deep. In addition, PGs may also show pathological changes such as thickening of the cortical layer, sclerosis and thinning of the bone structure, bone defects, changes like erosions and bone cysts, and bone deformations on the edges of joint surfaces [17]. However, we must remember that pathological changes in bone structures are most often visible on PG only when they are moderate or severe and that the image, depending on the type of X-ray apparatus, is magnified 1.3–1.5 times. Another disadvantage is that to have

the best visibility the head of the mandible on the functional PG, the patient must open the mouth as much as possible, which is difficult to achieve in patients with trismus and TMJ disorders [11]. According to the research results, functional PGs are not very reliable because no statistically significant correlation was found between the positions of condylar processes from available PGs and clinical measurements of the extent of mandibular abduction [18].

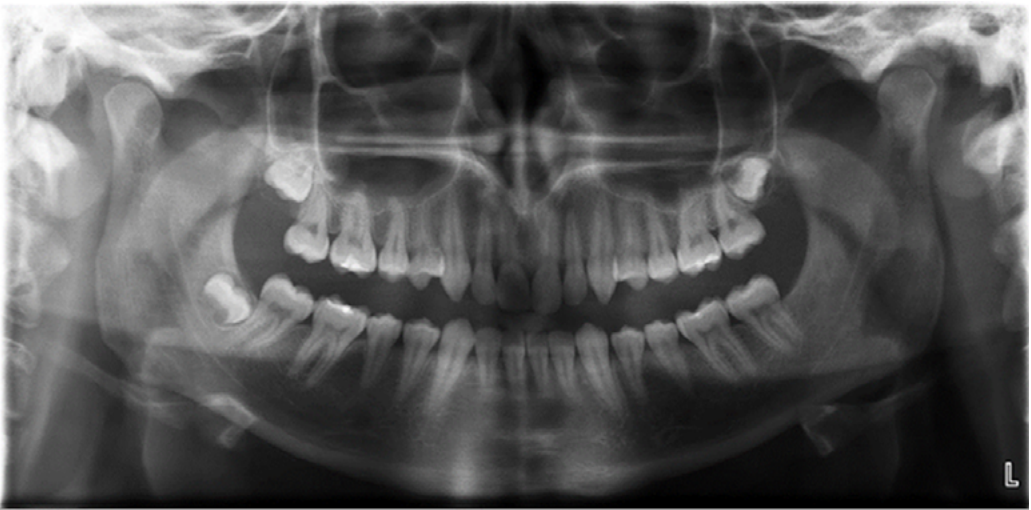
In addition, two similar studies were carried out regarding assessing the repeatability of the method of obtaining values of articular angles from PGs. One study [9] involved 21 dentists — prosthodontists and general practitioners — while the other [10] involved 78 fifth-year dental students at the end of an imaging seminar on radiology in dentistry. Participants in both studies were asked to mark four dots on either side of a printed PG. These were the same points we asked the students to mark in our study, i.e. Porion like point, Orbitale like point, the deepest point of the mandibular fossa and the lowest point of the articular tubercle. The results of both studies showed that using PGs to obtain the values of the articular angles is not recommended in dental practice due to the possibility of obtaining results that significantly change the occlusal relationships. The reason for the inaccuracy in the values of the articular angles in both studies was the lack of accuracy in marking the points by the participants. The most challenging task was marking the deepest point of the mandibular fossa and the lowest point of the articular tubercle because these structures are not very well visible on PGs. Both studies marked the Porion like point and Orbital like points with satisfactory accuracy. After analysing the students' results from our study, we can conclude that, in this case, the students had the most difficulty marking the deepest point of the mandibular fossa and the lowest point of the articular tubercle. This is because there were the most significant discrepancies between these points to the gold standard established by the researchers. In contrast, most students marked the Porion and the Orbitals quite carefully.

It is worth analysing the results of each group of students from our study. We must consider why only the results of men from the third year of studies showed statistically significant differences compared to the remainder of the respondents. A possible reason for this could be the small number of men ratio to women — 29 men and 100 women participated in the study. Furthermore, there was an uneven distribution of men in individual years of study. However,

all these factors were independent of the researchers. In addition, it is also necessary to consider why only one articular angle turned out to be particularly important in our research — the probable reason could be that the joint structures in PG No 4 are very well formed and demarcated a round shape, which is relatively rare, because the round type of condylar process of the mandible occurs only in 3% of cases according to Yale — Fig. 6, 7 [19].



**Fig. 6.** Condylar process of the mandible from photo PG No. 4 analysed by students.



**Fig. 7.** Photo of PG No. 4 analysed by students.

In summary, recognizing joint structures on PGs is very important from the clinical point of view, although it is often overlooked in diagnostics. Emphasis should be placed on the fact that students in the first years of dental school acquire the ability to assess and analyse TMJ on PGs properly. PGs have many advantages, including high availability, low cost and low radiation dose. Still, the most significant disadvantages of TMJ diseases are that they do not show changes in bone tissue. We must also remember that although PG tool may be equipped with special programs for imaging TMJ — this is not the primary method of diagnosis in patients with TMJ dysfunctions but only an additional element. A detailed clinical examination and instrumental analysis are crucial in the diagnose of the TMJ disorders.

### **Conclusion**

In the first three years of dental studies, dental students' skills in assessing panoramic radiography of the facial part of the skull remain at the same level.

### **Conflict of interest**

None declared.

### **Funding**

Grant financed by the Ministry of Science and Higher Education No. N N403 589138.

## References

1. *Perschbacher S.*: Interpretation of panoramic radiographs. *Aust Dent J.* 2012; 57 (Suppl): 140–145. doi: 10.1111/j.1834-7819.2011.01655.x.
2. *Shaikh A.H., Ahmed S., Ahmed A.R., et al.*: Assessment of radiographic morphology of mandibular condyles: a radiographic study. *Folia Morphol (Warsz).* 2022; 81 (2): 481–486. doi: 10.5603/FM.a2021.0049.
3. *Wieczorek A., Loster J., Majewski S.*: Assessment of suitability of orthopantomographs in dental diagnostics of temporomandibular joints. *J Stoma.* 2012; 65 (6): 845–854.
4. *Cosson J.*: Interpreting an orthopantomogram. *Aust J Gen Pract.* 2020; 49 (9): 550–555. doi: 10.31128/AJGP-07-20-5536.
5. *Habets L.L., Bezuur J.N., van Ooij C.P., Hansson T.L.*: The orthopantomogram, an aid in diagnosis of temporomandibular joint problems. I. The factor of vertical magnification. *J Oral Rehabil.* 1987; 14 (5): 475–480. doi: 10.1111/j.1365-2842.1987.tb00742.x.
6. *Habets L.L., Bezuur J.N., Naeiji M., Hansson T.L.*: The orthopantomogram, an aid in diagnosis of temporomandibular joint problems. II. The vertical symmetry. *J Oral Rehabil.* 1988; 15 (5): 465–471. doi: 10.1111/j.1365-2842.1988.tb00182.x.
7. *Gilboa I., Cardash H.S., Kaffe I., Gross M.D.*: Condylar guidance: correlation between articular morphology and panoramic radiographic images in dry human skulls. *J Prosthet Dent.* 2008; 99 (6): 477–482. doi: 10.1016/S0022-3913(08)60112-2.
8. *İlgüy D., İlgüy M., Dölekoğlu Z.S., Ersan N., Fişekçioglu E.*: Evaluation of radiological anatomy knowledge among dental students. *Yeditepe J Dent.* 2017; 13 (3): 31–36.
9. *Loster J.E., Wieczorek A., Ryniewicz W.I.*: Condylar guidance angles obtained from panoramic radiographic images: An evaluation of their reproducibility. *Dental and Medical Problems.* 2017; 54 (1): 35–40.
10. *Loster J.E., Ryniewicz W., Ryniewicz J., Wieczorek A.*: Assessment of the repeatability of condylar guidance angles obtained from panoramic radiographic images. *J Stoma.* 2014; 67 (6): 841–849. doi: 10.5604/00114553.1137108.
11. *Loster J.E., Groch M., Wieczorek A., Muzalewska M., Skarka W.*: An evaluation of the relationship between the range of mandibular opening and the condyle positions in functional panoramic radiographs. *Dental and Medical Problems.* 2017; 54 (4): 347–351.
12. *R Core Team*: A language and environment for statistical computing. R Foundation for Statistical Computing. Vienna, Austria. 2022.
13. *Różyło-Kalinowska I., Michalska A., Różyło T.K.*: A small atlas of technical errors and artefacts in intra-oral radiography. *Magazyn Stomatologiczny.* 2010; 4: 58–64.
14. ADA. Commission on Dental Accreditation. Accreditation standards for dental education facilities. 1988; 16.
15. *Razmus T.F., Williamson G.F., Van Dis M.L.*: Assessment of the knowledge of graduating American dental students about the panoramic image. *Oral Surg Oral Med Oral Pathol.* 1993; 76 (3): 397–402. doi: 10.1016/0030-4220(93)90278-c.
16. *Hunter A., Kalathingal S.*: Diagnostic imaging for temporomandibular disorders and orofacial pain. *Dent Clin North Am.* 2013; 57 (3): 405–418. doi: 10.1016/j.cden.2013.04.008.
17. *Mierzwińska-Nastalska E.*: Diagnostyka układu ruchowego narządu żucia. Zasady rekonstrukcji zwarcia. 1st ed. Otwock 2016.
18. *Okeson J.P.*: Leczenie dysfunkcji skroniowo-żuchwowych i zaburzeń zwarcia. 2nd ed. Lublin 2018.
19. *Yale S.H., Allison B.D., Hauptfuehrer J.D.*: An epidemiological assessment of mandibular condyle morphology. *Oral Surg Oral Med Oral Pathol.* 1966; 21 (2): 169–177. doi: 10.1016/0030-4220(66)90238-6.