

DOI 10.2478/v10181-011-0049-0

*Review*

# Laparoscopic procedures in dogs and cats

**H. Matyjasik<sup>1</sup>, Z. Adamiak<sup>1</sup>, W. Pesta<sup>2</sup>, Y. Zhalniarovich<sup>1</sup>**

<sup>1</sup> Department of Surgery and Radiology, Faculty of Veterinary Medicine, University of Warmia and Mazury, Oczapowskiego 14, 10-719 Olsztyn, Poland

<sup>2</sup> Department of General Surgery, Faculty of Medical Sciences, University of Varmia and Masuria, 37 Wojska Polskiego Avenue, 10-228 Olsztyn, Poland

## Abstract

Laparoscopic procedures are gaining wider application in veterinary medicine. The following article contains description of indispensable equipment for performing surgical procedures with use of laparoscopic technique and reviews some laparoscopic procedures which found application in veterinary medicine.

**Key words:** laparoscopy, endoscopy, dogs, cats

## Introduction

Operational techniques based on laparoscopy have been widely applied in human, and recently also in veterinary medicine. The following article is a review of basic laparoscopic procedures that have found their ways to veterinary medicine, contributing thus to its development.

Surgical operations performed with laparoscopic methods are characterized by their low invasiveness, small percentage of complications and low mortality. Application of the modern laparoscopic techniques makes it possible to shorten significantly patients' hospitalization time, guaranteeing thus their faster recovery and entailing a higher level of satisfaction in their owners.

The most common indications to laparoscopy in animals are: biopsy of abdominal organs or abdominal tissue masses, as well as surgical operations such as: ovariohysterectomy, vasoligation, nefrectomy, cholecystectomy, or pyloroplastics. Some data in the

subject literature also show possibilities of application of laparoscopy in cholecystic punctures for diagnostic purposes and in canine lymphadenography (Brisson et al. 2006). In addition, some attempts of application of laparoscopic procedures in feline insemination have been described (Howard et al. 1992). Table 1 shows some of laparoscopic procedures performed in dogs and cats.

Although laparoscopy is a low-invasive procedure, not every patient can be subjected to it. Human patients with diaphragmatic hernia, extensive intra-abdominal adhesions cannot undergo laparoscopy. Laparoscopic operations should not also be performed in obese animals, ones with abdominal dropsy, or in general bad condition. Pyometra is also listed as a contraindication to laparoscopy (Rothuizen 1985). Nonetheless, successful cases of laparoscopy-assisted ovariohysterectomy in two pyometric bitches have been described (Minami et al. 1997). Laparoscopy should not be performed in patients that require conventional medical operations.

Table 1. Table of laparoscopic procedures that have been performed in dogs and cats. (x) procedure has been performed. (–) procedure has not been performed.

Procedure	Dog	Cat	Potential application
Liver biopsy	x	x	advisable for routine use
Kidney biopsy	x	x	advisable for routine use
Intestine biopsy	x	x	advisable for routine use
Laparoscopy – assisted insertion of jejunostomy feeding tube	x	–	advisable for routine use
Ovariohysterectomy	x	x	advisable for routine use
Cryptorchidectomy	x	x	advisable for routine use
Laparoscopic assisted cryptorchidectomy	x	–	advisable for routine use
Gastropexy	x	–	complex procedure
Laparoscopic removal of foreign bodies from the stomach	x	–	only for experimental use
Bilroth II gastrectomy	x	–	only for experimental use
Urinary calculi removal	x	–	only for experimental use
Inflammatory polyp removal by laparoscopy – assisted cystoscopy	x	–	only for experimental use
Cystopexy	x	–	complex procedure



Fig. 1. Laparoscopic unit. From top to bottom: monitor, printer, camera, insufflator, DVD recorder, source of light.

### Elements of equipment constituting the laparoscopic unit

Basic elements of equipment necessary to perform laparoscopic operations include: a laparoscope (a telescope), a trocar, a source of light, a Veress needle, an insufflator (a laparoflator), and a video camera (Magne and Tams 1999) (Fig. 1).

Laparoscopes used in dogs and cats are usually 1.7 mm to 10 mm in diameter (Rothuizen J 1985, Magne ML and Tams TR 1999). A proper choice of a laparoscope diameter is of crucial significance for laparoscopes of 10-millimetre diameters provide a wider visual area, however, due to their dimensions and the length of the incision required for introduction of such instruments (2 cm), they can be used only in animals weighting at least 10 kg. Laparoscopes with diameters ranging from 5 to 7 mm are the most versatile ones and can be used in dogs and cats of almost every size. Laparoscopes with diameters from 1.7 to 2.7 mm are advisable for the smallest animals. The smaller diameter of a laparoscope, the stronger source of light should be provided. Smaller diameters of the instruments can contain smaller numbers of optical fibres.

The available laparoscopes provide viewing angles of 0° to 180°. Laparoscopes with viewing angles of 0°-45° are used most frequently.

Insertion of a laparoscope into the abdominal cavity is possible due to the application of trocars with appropriate diameters. A trocar consists of

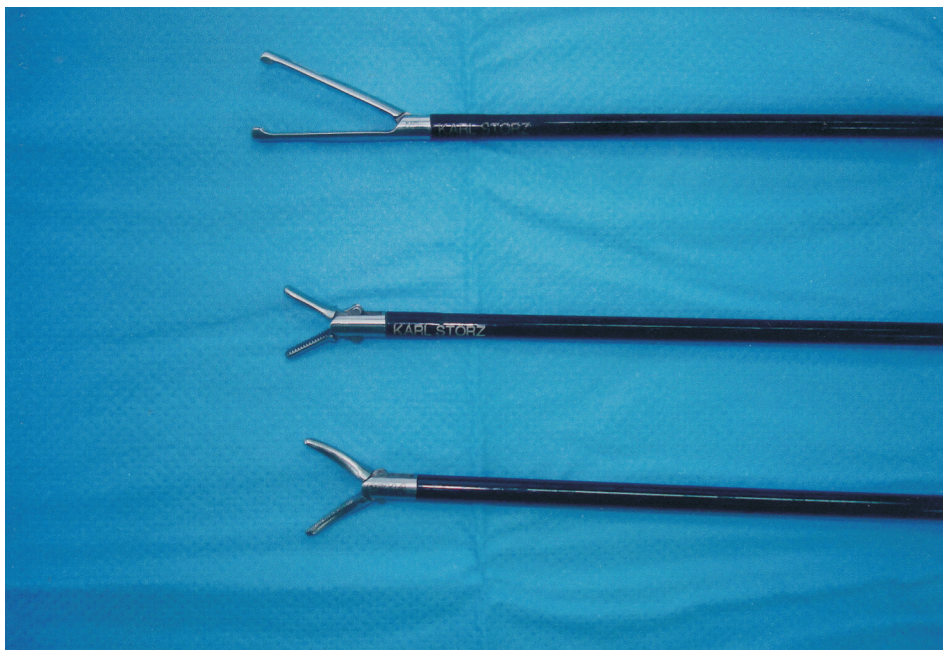

Fig. 2. Laparoscopic graspers. From the top to bottom: Babcock forceps, Reddic-Olsen forceps, Kelly forceps.

a blade for puncturing tissues of the abdominal integument and a cover (a tube) for introducing the laparoscope and laparoscopic tools. The blade may be ended conically or pyramidally, which is more advisable for such cutting edges that make penetration of the abdominal cavity walls much easier (Howard et al. 1992). Most trocars are equipped with a Luer lock extension that enables constant insufflation of gas into the abdominal cavity excluding the Veress needle.

The source of light consists of a supply that provides a so-called cold light source, a cooling system, a basic light source – a halogen or xenon lightning bulb, an optical system focusing the beam of light, and a regulatory system for the power and intensity of light. The optical fibre enables passing the beam of light to the laparoscope. A source of light with a 150 W lighting bulb is enough for diagnostic purposes. However, for operations as well as for photographic and video documentations a 300 W lighting bulb is necessary.

The Veress needle is a cannula with an internal spring and a bluntly ended mandrel preventing internal organs from harm during its insertion into the peritoneal cavity through the abdominal integument. It is also equipped with an adapter to which an insufflator pipe is connected.

The insufflator is used for production of pneumoperitoneum as a result of pumping gas into the peritoneal cavity through a rubber pipe and an inserted Veress needle. Carbon dioxide (CO<sub>2</sub>) is the most frequent gas used in laparoscopy, nitrous oxide (N<sub>2</sub>O) occurs less frequently. Application of nitrous oxide, apart from causing pneumoperitoneum, has

also its influence on sustaining anaesthesia, however, being an inflammable gas, it raises the risk of explosion during electrocoagulation (Rothuizen 1985). During an operation, a maximum pressure of 12-13 mm Hg in case of cats and 15 mm Hg in case of dogs should not be exceeded (Magne and Tams 1999).

A direct transmission of vision to a monitor is possible due to the usage of a video camera. It makes the operation easier for a doctor who does not have to look through a narrow hole of the laparoscope and lets any other members of a team follow the advances in the operation. It is of particular importance in operations where it is necessary to apply a larger number of endoscopic instruments and members of the operational team must synchronize their activities.

### Basic laparoscopic instruments

Modern laparoscopic surgeries require a wide range of endoscopic instruments, designed for particular activities. Preparation, grasping, and biopsy forceps, atraumatic instruments and scissors are only a few of the tools used in laparoscopy.

The most often used instruments include: forceps – so-called “graspers” – used for catching objects, preparation forceps (preparators) (Fig. 2) and scissors. It is often possible to connect the aforementioned instruments to an electrocoagulator. Such a set makes it possible to diathermically cut and prepare tissues with their simultaneous electrocoagulation.

Atraumatic instruments of various shapes, called retractors, are also widely used in laparoscopic oper-



ations. They make it possible e.g. to improve the visual field during an operation by moving apart and holding the organs or tissues that block out the target organ and are not directly involved in the operation.

To collect tissue samples for histopathologic examination, biopsy forceps are necessary.

It is also possible to improve significantly an ongoing operation using a rinsing and sucking device that enables rinsing of the operational field and ensures its transparency by removing blood clots, small fragments of tissues and the smoke created during electrocoagulation. It also enables irrigation of the abdominal cavity interior with therapeutic solutions.

### **Creation of pneumoperitoneum and insertion of instruments**

Before inserting trocars and endoscopic instruments to the abdominal cavity, pneumoperitoneum should be created. To achieve that, a Veress needle, through which a gas from an insufflator is to be let into the abdominal cavity, should be introduced at first through the abdominal integuments. To facilitate the insertion of the needle through the wall of the abdominal cavity, an incision of the skin should be made that would be approximate to the Veress needle diameter. To insert the Veress needle to the abdominal cavity, its stem must be grasped and pushed simultaneously through the previously made incision in the abdominal wall. At this point, the bluntly ended internal part of the needle is retracted while the external part punctures the abdominal wall. When the Veress needle is placed inside the abdominal cavity, its bluntly ended internal part moves forward to the front of the external one as to prevent internal organs from harm. To ensure that the end of the needle is not placed inside any organ, a syringe should be connected to the needle and some material should be aspirated. During the aspiration no intestine content, urine, blood, or gas should enter the inside of the syringe. After that, a solution of physiological saline should be injected into the peritoneal cavity. The solution should not make any resistance during that slow injection. The material should be aspirated once again. There may be a small amount of the liquid in the syringe after the second aspiration. If there is a larger amount of physiological solution in the syringe, it means that the end of the needle is placed in the lumen of an intestine or in the urinary bladder.

When the Veress needle is placed in the peritoneal cavity, a rubber insufflator pipe is connected to it and carbon dioxide is pumped in so that an appropriate level of pressure is obtained in the abdominal cavity. If the insufflator gauge indicates no gas flow, it should be suspected that the end of the needle has been placed under the skin, has been covered by a net,

or has been driven inside one of the internal organs. This being the case, the needle should be moved back and forth so that the net would slide down the needle. If there is still no gas flow, the Veress needle should be removed and introduced anew. After pneumoperitoneum has been created, the abdomen feels tympanic when palpated.

When pneumoperitoneum of desired pressure has been created, an incision of the skin and the hypodermic tissue is made at the point where a visual trocar is to be introduced. The trocar is inserted into the abdominal cavity with a rotary movement, by holding the tube circa 3 cm from the end of the trocar as to prevent an involuntary insertion of the trocar too deep into the abdominal cavity. A gas hiss or a sound similar to that of a cork driven out of a bottle is heard at the moment when the trocar enters the peritoneal cavity. The blade should be then retracted into the tube and pulled out of the abdominal cavity. A laparoscope, with an optical fibre connected to it, is inserted into the abdominal cavity through the tube. If a video camera is used, it should be placed on the ocular. The abdominal cavity, and the puncture areas of the Veress needle in particular, should be examined.

The insufflator pipe is disconnected from the Veress needle and connected to the trocar through which the laparoscope is introduced. The Veress needle is then removed, which is controlled by the laparoscope. It happens that during an operation the lens of the laparoscope may be covered with blood, fragments of tissues or condensed steam. The lens can be cleaned by rubbing it against intestines. If that does not work, the laparoscope should be pulled out of the abdominal cavity and the lens should be wiped with dry gauze or gauze moistened with saline solution or alcohol. It also happens that the net wraps around the laparoscope on its insertion into the abdominal cavity. In such a situation, the laparoscope should be retracted into the tube as long as the net drops out of it.

When the laparoscope is placed inside the abdominal cavity, a place for insertion of the second trocar should be selected. It is advisable to lighten the wall of the abdominal cavity with the laparoscope at the place of insertion of the second trocar to make its hypodermic blood vessels visible. It helps to avoid damaging them and to minimise a blood loss. The selected and lightened place should be pressed from its outside with a finger and observed from the inside to determine the exact point for the insertion of the trocar.

The second trocar is inserted using the same technique that has been described at the introduction of the first one. A required instrument is inserted into the place of the removed blade of the trocar. Each introduction of an instrument through the tube of the trocar should be observed from the inside as to avoid damaging the internal organs.



On finishing the operation, the instruments of the laparoscope and the trocars are removed from the abdominal cavity and the gas is let out of the peritoneal cavity. Later on, the abdominal integument sewn up with two or three layers of sutures at the places where the tubes of the trocars were placed.

Alternative method creation of pneumoperitoneum is Hasson's technique in which Veress needle is not used. In this technique minilaparotomy is performed and trocar is introduced into the abdominal cavity under direct vision. The trocar is used both to create pneumoperitoneum and to insert laparoscope into the abdominal cavity. Hasson's technique decrease abdominal organs trauma during placing first trocar, it also makes easier introduction of first trocar in case of intra-abdominal adhesions. Drawback of this method is bigger skin scar.

### **Diagnostic laparoscopy**

In veterinary medicine, diagnostic laparoscopy is used most often when other diagnostic methods do not allow a precise identification of causes of the animal's disease or when unnecessary exploratory laparotomy is avoided. It may also be used to identify the stage of a neoplasm development (staging) (Johnson and Twedt 1977, Wild 1980). All the methods of non-invasive identification of neoplasm development stages include a high percentage of false identification – the higher percentage, the smaller the identified neoplastic lesion is. It should be remembered that in identification of lesions smaller than 1 cm regular computer-assisted tomography (CAT) and magnetic resonance imaging (MRI) are characterized with diagnostic sensitivities equal to 49% and 31%, respectively (Werneke et al. 1991). Laparoscopy is the most sensitive method of identification of small metastases to the liver and peritoneum. The method enables observation of even tiny changes to the blood supply of tissues, which may indicate a development of cancerous diseases. Due to its small incisions, it is possible to start chemotherapy earlier than in case of laparotomy. Apart from this, it enables insertion of tubes for ventral nutrition if needed.

During diagnostic laparoscopy, a biopsy may be performed and a liquid content of the gall bladder may be collected for bacteriological test. It is also possible to forward directly from diagnostic laparoscopy to a laparoscopic surgical operation if such a situation occurs.

### **Ovariohysterectomy**

Ovariohysterectomy makes it possible to control the animal population and makes an element of prophylactics and treatment of some diseases e.g.: en-

dometritis, pyometra, diabetes, or behavioural disturbances connected with hyperoestrogenism (Stone and Barsanti 1992). One of the advantages of laparoscopic ovariohysterectomy is made by its better visualisation that limits the risk of an incomplete ovarian resection (Bailey et al. 1998).

On former preparation, the patient is placed on an operating table in a Trendelenburg position (the head situated circa 30° below the sacral bone). A Veress needle should be inserted into the abdominal cavity before the navel and pneumoperitoneum should be created. A trocar, through which a laparoscope is introduced, is fixed at the place of the Veress needle insertion. Then, two working trocars are inserted into the paramedian line at the height of the inguinal folds. A grasper is introduced through one of the working cannulae to move the intestines towards median positions so that one of uterine horns, a proper ovarian ligament, an ovary, and a suspensory ovarian ligament are visible. The proper ovarian ligament is grasped and lifted with the second grasper, introduced through the opposite cannula, to cause tightening of the suspensory ovarian ligament. On removal of the grasper for relocation of the intestines, a harmonic knife is introduced into the peritoneal cavity through the empty cannula. The suspensory ovarian ligament, crura that lead vessels to the ovary, and the broad uterine ligament are cut using the knife. Then, both middle uterine arteries and the body of the uterus are coagulated and cut with the same instrument at circa 1 cm from the cervix. On locating the second uterine horn, the same actions as on the first one are performed on it. Next, the uterus is grasped with endoscopic forceps and pulled out through one of the previously widened paramedian incisions. It should be verified that there is no bleeding from the uterine stump or vessels that used to supply blood to the ovaries. On letting the gas out of the peritoneal cavity, the wounds should be sutured.

### **Cryptorchidectomy**

Laparoscopic-assisted cryptorchidectomy may be carried out both in cats and dogs. A patient is placed on a table so that it would be possible to change the angle of the tabletop into a dorsal position to place the head below the sacral bone and in the angle of circa 20° to it. It is also advisable to turn the patient slightly towards the opposite direction that cryptorchism has been diagnosed (Miller et al. 2004). Such a position of the patient causes relocation of the intestines, and thus improvement of visibility in the area examined.

On former creation of pneumoperitoneum, a trocar is introduced through the abdominal integuments, just behind the navel. On removing the blade,

a laparoscope is inserted into the peritoneal cavity. When the testicle situated in the abdominal cavity is found, the second trocar is inserted ventrally and slightly laterally towards the observed testicle, which is directly observed through the laparoscope. The testicle is grasped with endoscopic forceps inserted through the tube of the second trocar. Then, the hole in the abdominal cavity through which the second trocar has been inserted should be widened. On performing these actions, the testicle is pulled out through the widened hole and the deferent canal and spermatic cord are ligated with a single suture made of absorbable 3-0 or 2-0 thick threads. It should be checked if there is no bleeding from the ligated structures.

If there is another testicle in the abdominal cavity, the trocar is reinserted into the widened hole and its direct neighbourhood is covered with moistened gauze to prevent the gas in the abdominal cavity from escaping during its re-insufflation. The second testicle may be removed using the same hole that the first one has been removed through (Miller et al. 2004).

The advantage of laparoscopy-assisted cryptorchidectomy over laparoscopic cryptorchidectomy is that it requires inserting only two trocars, which limits the number of injuries to the abdominal cavity, reducing thus the patient's pain and aiding the achievement of a better cosmetic result due to a smaller amount of scars.

Laparoscopic cryptorchidectomy is performed in dogs more frequently (Richardson and Mullen 1993). To carry out the operation, a dog should be placed on an operational table in a dorsal position. On creation of pneumoperitoneum, three trocars are situated in places marked by the points of an isosceles triangle. The point made by the two equal lines is the place to insert the optical trocar – it is situated on the linea alba, circa 2 cm behind the navel. The remaining two trocars are placed on the left and the right side, caudally from the first port, near the linea alba, circa 10 cm from the optical trocar. The distances between the trocars may vary depending on the size of the patient. On finding an undescended testicle in the abdominal cavity, it is grasped with endoscopic forceps, pulled forward and placed so that the deferent canal as well as the testicular artery and vein can be seen (Lew et al. 2005). Then, the lumens of the deferent canal and the vessels of the spermatic cord are closed. Several ligation techniques for those structures have been described (Brock 1996, Thiele et al. 1996, Nudelman 1997, Bergeron et al. 1998, Pena et al. 1998, Shyu and Liu 1998, Lew et al. 2005).

A ligation employing a surgeon's knot and an absorbable thread may be done in two ways. A technique described by (Thiele et al. 1996) consists of preparing a Roeder slipknot outside the abdominal cavity and then tightening it on the spermatic cord (Bailey et al. 1998).

The whole procedure of ligating the spermatic cord may be also carried out inside the abdominal cavity (Lew et al. 2005). A special set of laparoscopic instruments for placing surgical sutures is necessary for that purpose: a Parrot-Jaw needle holder and auxiliary Flamingo-Jaw forceps. Two bands are placed onto the spermatic cord so that a cut between them would be possible.

The ligation of the spermatic cord may also be done by double placing of intestinal staplers (Peña et al. 1998). It is a method that ensures a fast and strong ligation, however, an expensive one and thus unprofitable.

The method of tying knots inside the abdominal cavity is the most difficult one out of the aforementioned techniques of spermatic cord ligation, however, it is also the cheapest one (Lew et al. 2005).

When the bands have been put onto the spermatic cord, it is cut with endoscopic scissors between the bands. On total ablation of the testicle, it is grasped with endoscopic forceps and pulled outside the abdominal cavity, after micro-laparotomy at the place where the trocar that the forceps have been inserted through was situated.

The spermatic cord may also be subjected to occlusion using dielectric heating (Bergeron et al. 1998, Shyu and Liu 1998).

Additionally, laparoscopy may also be applied for removal of cancerously changed testicles from the abdominal cavity (Peña et al. 1998, Lew et al. 2005). Apart from the aforementioned actions, during the laparoscopic cryptorchidectomy connected with a cancerously changed testicle, it is advisable to place the testicle inside a laparoscopic sack just before pulling it out of the abdominal cavity so that its contact with the abdominal tissues is minimised (Lew et al. 2005).

## Gastropexy

Gastropexy is an operation that prevents gastric dilatation-volvulus (Ellison 1993, Hosgood 1994). Laparoscopic methods of gastropexy have been developed to reduce postoperative pains (Rawlings et al. 2001, Rawlings 2002).

A dog is put into a dorsal position. The first trocar is situated in the median line, circa 2-3 cm behind the navel and a laparoscope is inserted through it. The second trocar is inserted at the right margin of the rectus abdominis muscle, circa 3 cm behind the last rib. That trocar is used for introducing the Babcock forceps that grasp the pyloric antrum in the middle between the greater and lesser curvatures, circa 5-7 cm from the pylorus in a cranial direction. On grasping the stomach, the Babcock forceps are pulled out, holding the organ at the same time. After the removal of the cannula, the incision in the abdominal muscula-

ture is widened to circa 4 cm parallelly to the last rib. Pulling the pylorus out of the abdominal cavity should be performed in a careful way that prevents the pyloric antrum from twisting. Sutures used as reins are placed on the pyloric antrum on the sides of a gastropexic joint, after which an elongated 4-centimetre-long incision is made that includes serous and muscular layers of the organ. The edges of the incision should be separated from the mucous membrane as to be sure that the placed sutures include only the serous and muscular layers. The serous and muscular layers are sutured to the transversus abdominis muscle with a continuous suture made of absorbable monofilament material sized from 2-0 to 0. The stomach should be viewed with the laparoscope to make sure that there is no twist of the pyloric antrum (Rawlings et al. 2001, Rawlings 2002). On removing the cannulae, the transversus abdominis muscles should be sewn using an interrupted cross suture.

Gastropexy may also be performed with the use of laparoscopic instruments applied for fixing staplers (Rawlings 2002). When the trocars and the instruments are inserted into the abdominal cavity, a tunnel under the muscular layer of the stomach and a tunnel in the muscles of the abdominal wall are created. A linear endoscopic stapler with cutting ability is inserted into the both tunnels. With its every push, the stapler places four rows of clamps making at the same time a cut between the two internal rows (Rawlings 2002). The operation that employs those instruments requires three trocars and a significant skilfulness of the operating doctor, and thus it is more difficult than the method described before. Moreover, the instruments for placing staplers are expensive, which significantly raises the costs.

### **Laparoscopic removal of foreign bodies from the stomach**

Foreign bodies make a frequent problem in veterinary medicine reported for young animals. They are often removed with endoscopic loops, baskets and nets. If such an object cannot be removed using an endoscopic access, and leaving a foreign body possesses a threat of damage to the digestive tract, a surgical intervention is required. The technique of laparoscopic removal of foreign bodies in dogs has been described so far (Lew et al. 2005).

Three working ports are placed in the wall of the abdominal cavity, in the median line frontally from the navel. The frontal port is inserted caudally 2 cm from the xiphisternum, the rear one 2 cm cranially from the navel, and the third one – in the mid-length of the former two. A visual port is placed on the section of the sagittal line situated halfway between the midline and the axillary line as well as the line running

perpendicularly to it through the port that is situated between the frontal and real working ports. Endoscopic forceps are introduced into the frontal and real working ports to slip down the net from the stomach. Reins that are to suspend and stretch the stomach are fixed to it. A monofilament thread and a simple atraumatic needle are used for these purposes. The places of reins suspensions are located to the front and to the back from the place of the primal location of the stomach in the sagittal line, 10-15 cm from the midline, opposite the visual port. Depending on the length of the animal, they are situated circa 10-15 cm from each other. On inserting the thread through the previously marked points, the stomach is punctured with a needle in places situated in the greater curvature in the distances of  $1/3$  and  $1/2$  between the cardia and the pylorus. The reins are pulled in the opposite directions and placed outside the abdominal cavity. When the stomach is properly stretched, the reins are clipped together by their ends with forceps. Gastrotomy is performed with scissors inserted through the frontal port, in a 4-5-cm-long line, halfway between the greater and the lesser curvatures. A laparoscopic sack is inserted through the middle port and directed towards the hole in the stomach. The foreign body is removed from the stomach and placed inside the laparoscopic sack. The sack with its content is removed outside after lengthening the hole of the middle working trocar. The temporally created hole may be closed with the Backhaus forceps to keep the pneumoperitoneum. The place of gastrotomy is closed with sutures or a linear stapler. Then, the reins are removed and the stomach is covered with the net.

### **Billroth II gastrectomy**

Billroth II gastrectomy performed with laparoscopy has been used in dogs (Soper et al. 1994). Before the operation, a stomach decompression should be induced with a probe introduced through the oral cavity. On placing a patient in a dorsal position and creation of pneumoperitoneum, a visual trocar is inserted behind the navel. Next, five additional ports are introduced. The vessels that supply the part of the stomach that is to be resected are closed. Then, 1 cm from the pylorus, the duodenum is divided with a linear stapler. The stomach is divided in the same way – by several launches of the linear stapler. The cut-out fragment is placed on the body of the liver. A closer part of the small intestine is identified and such a point is selected, distally from the duodenum, so that the intestine can be moved towards the rear stomach wall not creating any tensions to the tissues. Enterostomy is performed along contra-mesenteric margin of the intestine, after which the edge of the incision is grasped with an endoscopic Allis clamp. Gastrotomy is per-



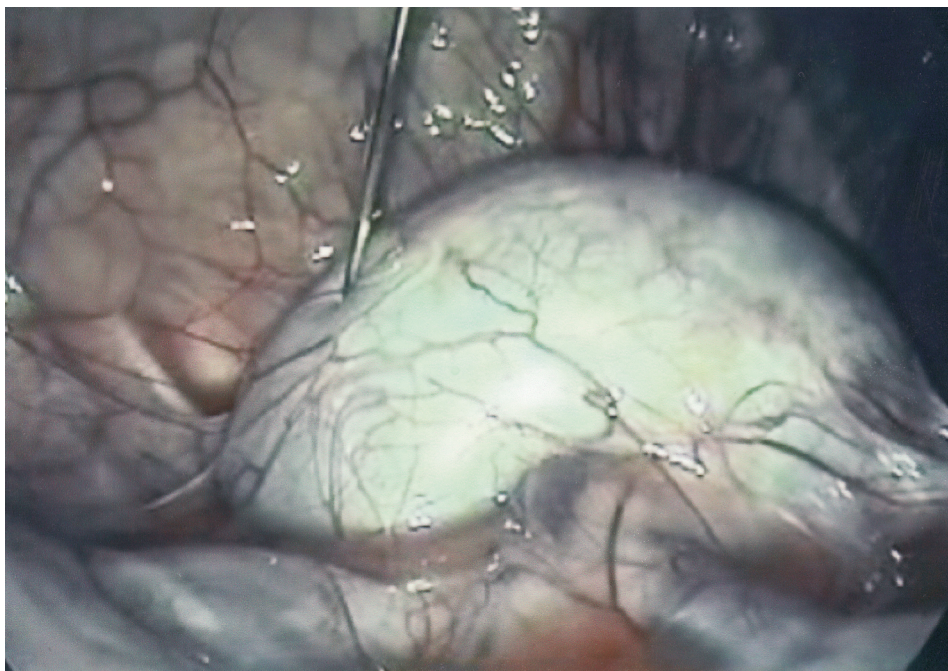


Fig. 3. Kidney needle biopsy.

formed in the back wall of the stomach, at the height of circa 1 cm from the place where the staplers have been fixed, and the edge of the incision is grasped with an endoscopic Allis clamp. The open jaws of the lineal stapler are inserted into the place of enterostomy and gastrotomy in a horizontal position, after which they are tightened creating an anastomosis side to side. Then the elongated hole in the intestine is closed with the stapler so that not to cause any narrowing to its lumen. The cut-out fragment of the stomach, together with a part of the duodenum, is placed in a nylon sack and is pulled out of the abdominal cavity through the widened hole of one of the trocars (Soper et al. 1994).

### Kidney biopsy

Kidney biopsy is performed when glomerular diseases are suspected to determine prognosis and to enable formulating treatment recommendations. A possibility of direct observation and diagnosis of kidney condition by inserting a laparoscope makes a significant advantage of the laparoscopic kidney biopsy over other biopsy techniques of this organ. Observing the kidney before its biopsy increases the possibility of collecting samples from its focal lesions. An animal is placed on an operating table according to the kidney that the biopsy is to be performed on. If it is the left kidney, the patient is put to the right-lateral position and if it is the right one, the opposite position is required. On former creation of pneumoperitoneum,

a visual trocar is inserted circa 5 cm behind the last rib, ventrally from 3 to 5 cm from the margin of the psoas muscle (Grauer et al. 1983). An incision of 2 cm is made in another place and a biopsy needle is introduced into the abdominal cavity. To make the selection of the skin incision point easier, the location of the kidney may be discovered by palpation of the abdominal cavity caudally from the last rib (Monnet and Twedt 2003). Next, at one of the poles of the organ, the renal sac is punctured so that the needle is driven into the core of the kidney (Fig. 3). When the needle is in its appropriate position, it is launched, after which it is removed from the abdominal cavity. On collecting the sample, the kidney should be observed in terms of its possible bleeding (Grauer et al. 1983, Monnet and Twedt 2003). The second trocar may be placed in the wall of the abdominal cavity close to the kidney. It is used for inserting a palpation probe for tamponade of the biopsy place. If needed, the palpation probe is put to the biopsy place and a light pressure is created for a few minutes. The right kidney is less movable for the caudate lobe of the liver is situated cranially from it, which makes it difficult to move the kidney forward (Grauer et al. 1983, Monnet and Twedt 2003).

Performing biopsy of the left kidney from the left-lateral access is more difficult for the place frequently used for insertion of a trocar is occupied by the spleen (Monnet and Twedt 2003). Due to that fact, if there is no indication to perform biopsy of the left kidney, it is better to choose the right kidney for these purposes.

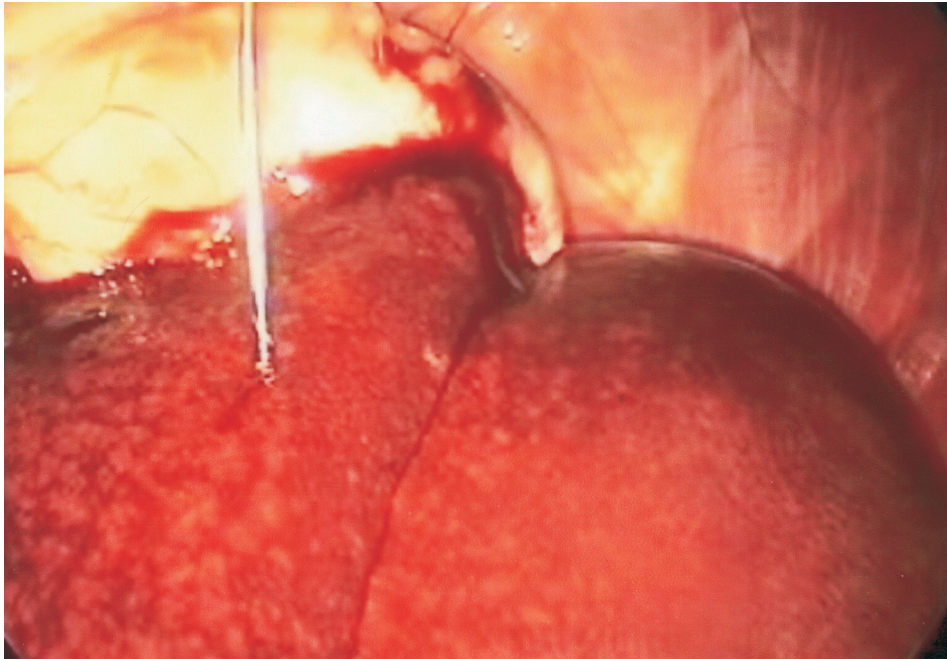


Fig. 4. Liver needle biopsy.

### Liver biopsy

Liver biopsy is often indicated in suspected liver disease and in histopathologic evaluation of focal and diffuse lesions of the organ. Laparoscopy is a technique that allows a direct biopsy of the liver. Samples may be collected performing a fine needle aspiration biopsy, a needle biopsy (Fig. 4), or a laparoscopic biopsy aided with biopsy forceps. The fine needle aspiration biopsy provides poor possibilities of diagnosis of inflammatory changes and vascular anomalies (Richter 2001). Spoon or clamshell biopsy forceps enable collection of quite large fragments of tissues at minimal injuries to the tissues and small bleeding (Richter 2001).

A right-lateral access makes it possible to diagnose the liver, the extrahepatic bile ducts and the pancreas. With that access, it is possible to perform a biopsy of the hepatic tissue and diagnose circa 85% of the liver area (Twedt 1999). Samples may be collected both from the margin of the liver and from its area. It is advisable to perform the biopsy of the organ in three or four places of several lobes, not only in changed places but also in those that look normally (Richter 2001, Monnet and Twedt 2003, Webb 2008). Biopsies of both dorsal and ventral sides of the liver may be performed (Richter 2001). Any possible bleeding is easier to identify and control from the ventral side, however a haemorrhage on the dorsal side may be stopped by the weight of the organ itself (Richter 2001). All the lobes should be lifted and examined so that no lesion is omitted. The lobes may be lifted with closed biopsy forceps that should be

slowly opened and retracted later on, until the margin of the lobe falls inside the open jaws of the forceps (Webb 2008). It is advisable for the liver tissue to take up to circa half of the forceps jaws for in the case when it takes up the whole length of the jaws, it becomes more difficult to separate the probed fragment from the organ, which increases the possibility of bleeding (Webb 2008). The forceps should be closed and kept closed for 10-30 seconds, and then the closed forceps should be retracted to the trocar (Monnet and Twedt 2003, Webb 2008). Some doctors twist the closed instrument during its retraction (Richter 2001, Webb 2008).

If it is necessary to collect tissue samples from deeper areas of the organ, closed biopsy forceps are placed inside the liver and inserted into a required depth. The forceps are opened and then inserted deeper, after which the jaws are closed and the instrument is twisted during its removal (Richter 2001).

### Intestine biopsy

Laparoscopy enables a biopsy of intestines that includes all their layers which is very important for diagnosing lesions in the intestinal wall. It does not make it possible to examine the intestines by palpation, but it helps to avoid manipulation with the entrails, and thus minimises stress, risk of harm and pain. In patients with ascites, the laparoscopic biopsy minimises losses of fluids and proteins (Rawlings et al. 2002).

On creation of pneumoperitoneum with a Veress needle, the first trocar is placed inside the medial line, 2-3 cm behind the navel. A laparoscope is inserted, after which the second trocar is placed laterally from the rectus abdominis muscle and the Babcock forceps are inserted through it. If there is a need to search for an appropriate place for the biopsy, it is advisable to insert the third trocar laterally from the rectus abdominis muscle so that efficient relocation of the intestines is possible. When the biopsy place has been selected, a loop of intestines is grasped and pulled to the place where the second or the third sleeve of the trocar is situated. The cannulae and the forceps are pulled out and the incision of the abdominal integuments where the trocar has been placed is widened. Sustaining sutures are placed on both sides of the place that the biopsy is to be performed. A sample is collected by making a crosswise cut towards the long axis of the intestine using the size 11 scalpel. The biopsy place is sewn up with a cross or single interrupted suture with an absorbable thread so that the mucous membrane is turned inside the intestine lumen. Then, the intestine is reinserted into the abdominal cavity.

If there is a need to perform a few biopsies, the intestinal serous membrane may be used as a leaf to aid adhesion in the place of the biopsy. To do so, after collecting a sample of the intestine, the suspending sutures should not be removed. On selection of another biopsy place, the chosen fragment of the intestine should be pulled up to the previously widened hole. The previously used thread is reused for fixing the suspending sutures. The biopsying procedure is repeated. On placing cross sutures, the ends of the suspending suture are tied together so that both biopsy places would stick to each other. If the serous membrane leaf is applied, it is important not to place both biopsy places too close to each other (Rawlings et al. 2002).

#### **Laparoscopy-assisted insertion of jejunostomy feeding tube**

Feeding tube placement is a palliative procedure used for providing nutritional support when the stomach has to be bypassed. A laparoscopy-assisted insertion of an jejunostomy feeding tube into the duodenum and the jejunum in dogs has already been described (Rawlings et al. 2002, Hewitt et al. 2004). A patient should be placed in a dorsal position. The trocar that the laparoscope is placed in should be inserted through a skin incision in the median line, 2-3 cm behind the navel. The second trocar is inserted into the abdominal cavity laterally to the right rectus abdominis muscle, slightly caudally towards the visual port. On inserting forceps through the second port,

the duodenum is grasped in the middle of its length and pulled towards the place that the second port is inserted. If there is such a need, the incision at the second trocar may be dilated so that the contra-mesenteric margin of the duodenum is visible. The duodenum is sewn to the rectus abdominis muscle with four knotted sutures so that they form a square. Then, a purse-string suture is placed in the middle of that square, after which a catheter is inserted through the middle of that suture into the lumen of an intestine. An jejunostomy feeding tube is introduced through the previously placed catheter, after which the purse-string suture is tightened and tied and another one is put on. The authors of the method recommend putting three levels of sutures. The tube should be secured from pulling out by the animal.

Insertion of an jejunostomy feeding tube into the jejunum is performed using a left-lateral access (Hewitt et al. 2004). A visual trocar is inserted ventrally from the dorsal muscles. Working trocars are inserted cranio-ventrally behind the last rib and caudo-ventrally frontally from the pubic symphysis. On introduction the Babcock forceps to the both ports, the jejunum should be found. Two instruments enable moving parts of the small intestine hand-over-hand so that it is easier to find the jejunum. On finding the organ, it is grasped and pulled towards the rear working trocar (Hewitt et al. 2004). Further actions may be the same as those described above. An jejunostomy feeding tube may be inserted into the jejunum through a hole in it made with a scalpel without former usage of a catheter (Hewitt et al. 2004).

#### **Urinary calculi removal**

Removal of bladder stones with laparotomy is an operation frequently applied to dogs and cats (Stone et al. 1993, Fossum et al. 1997). Laparoscopy-assisted cystoscopy enables minimisation of an injury to the abdominal cavity and a precise diagnosis of the mucous membrane in the urinary bladder. So far, the operation has been performed in dogs only (Rawlings et al. 2003, Rawlings 2007).

A patient is placed on a table in a Trendelenburg position. On creating pneumoperitoneum, a trocar is placed in the median line, 2-3 cm behind the navel. A working trocar is placed caudally from the visual trocar in the linea alba in bitches, and in paramedian line in dogs. In male dogs, precautions should be taken as not to damage the rear superficial hypogastric vessels. On inserting the Babcock forceps into the working trocar, the urinary bladder is grasped in its cranial-ventral part and pulled towards the sleeve of the trocar. The hole of the trocar is elongated so that suspending sutures can be placed. Four suspending sutures, 3-0 or 2-0 thick, are fixed to secure the place



of cystotomy so that it is large enough to remove the stones. On incision of the urinary bladder, a cystoscope is inserted into it to remove the urine. Then, the bladder is rinsed with an isotonic solution of NaCl until a transparent medium is obtained. The mucous membrane is observed and the size, shape and number of the stones are estimated. Surgical forceps, laparoscopic graspers and basket catheters may be used to remove the stones. Small stones, situated in the urethra, may be removed through a catheter by rinsing with a solution of physiological saline. After the removal of the stones, the physiological liquid is also removed from the urinary bladder and the serous-muscular layer is sutured.

### Cystopexy

Cystopexy is performed in male dogs with perineal hernia to avoid urinary bladder retroflexion (Huber et al. 1997) and in bitches to treat urinary incontinence in the pelvic bladder (Massat et al. 1993, White 2001). Laparoscopy-assisted cystopexy makes it possible to avoid some complications connected with laparotomy performed before cystopexy.

A dog is placed on a table in a Trendelenburg position. A visual trocar is placed in the paramedian line, 2-3 cm behind the navel. In male dogs, the second trocar, used for introducing the laparoscopic Babcock forceps, is inserted laterally from the rectus abdominis muscle in the retrogastrum. The urinary bladder is grasped with the laparoscopic Babcock forceps in its ventral part and pulled cranially along the right ventral part of the abdominal cavity. A 2.5 cm long incision of the skin, the hypodermic tissues, and the muscles is made just above the urinary bladder. Then, reins are fixed on the bladder. They are used to hold the bladder in a place and stretch it so that a 2.5-3 cm long incision of its serous and muscular layer can be made. A simple running suture made of absorbable material is fixed so that the paramedian edge of the bladder incision can be connected to the same incision in the aponeurosis of the abdominal internal and external oblique muscles. After that, a similar operation is performed on the lateral edges.

In bitches, a working trocar is located at the back of a visual trocar, laterally just by the rectus abdominis muscle. The urinary bladder is grasped with the Babcock forceps and pulled cranially. An elongated 3 cm long incision is made in the wall of the abdominal cavity at one of its sides laterally from the superficial epigastric vessels. To make relocation of the bladder towards the incision in the abdominal cavity easier, the second Babcock forceps may be introduced through it using a trocar or not. Fixing the urinary bladder to the wall of the abdominal cavity is performed in the same way as described in male dogs. On finishing the cystopexy, the urinary bladder should be diagnosed laparoscopically.

### Inflammatory polyp removal by laparoscopy-assisted cystoscopy

Removing inflammatory polyps using a laparoscopy-assisted cystoscope in dogs has already been described (Rawlings 2007). A patient is put to a Trendelenburg position in the angle of 5°. On creating pneumoperitoneum, the first trocar is inserted into the median line, 2-3 cm behind the navel. On introducing a laparoscope to the port, the second trocar is inserted ventrally into the median line from the cranial margin of the slightly bloated bladder. The frontal ventral margin of the urinary bladder is grasped with the Babcock forceps. Then the incision, that the working trocar has been inserted into, is extended and the bladder is pulled towards it so that suspending sutures can be fixed close to the planned incision of the urinary bladder. The bladder is pulled from the abdominal cavity so that there is an access to the polyp. The cystoscope is inserted through a small incision in the cranial-ventral part of the urinary bladder. The urine is removed from the bladder with the cystoscope and the bladder is rinsed with a physiological saline solution so that the medium is optically transparent and the bladder is dilated. The mucous membrane is observed to find lesions and bladder stones. The edges of the polyp are identified with the cystoscope so that resection of the polyp is possible. The wall of the bladder that contains the polyp is cut out with a scalpel, by cutting it alongside the edges of the polyp. The wall of the urinary bladder is closed and the bladder itself is reintroduced into the abdominal cavity.

### Summary

Laparoscopy is a technique of a minimal invasiveness that provides possibilities of performing numerous diagnostic and surgical procedures. When applied by an experienced surgeon, laparoscopy is a simple, safe and efficient technique to perform surgical operations in animals. Operating with laparoscopic techniques provides an alternative for conventional methods. Their low invasiveness and short time of hospitalization and recovery of animals make laparoscopic methods become more and more interesting not only for veterinary doctors but also for owners of the animals.

### References

- Austin B, Lanz OI, Hamilton SM; Broadstone RV, Martin RA (2003) Laparoscopic ovariohysterectomy in nine dogs. *J Am Anim Hosp Assoc* 39: 391-396.
- Bailey JE, Freeman L, Hardie RJ (1998) Endosurgery. In: Bojrab MJ (4<sup>th</sup> ed.) *Current techniques in small animal surgery*. Baltimore, Williams & Wilkins, pp 729-745.

- Bergerom JA, Hendricksom DA, McCue PM (1998) Valiability of an inguinal testis after laparoscopic cauterization and transection of its blood supply. *J Am Vet Med Assoc* 213: 1303-1304.
- Brisson BA, Holmberg DL, House M (2006) Comparison of mesenteric lymphadenography performed via surgical and laparoscopic approaches in dogs. *Am J Vet Res* 67: 168-173.
- Davidson EB, Moll HD, Payton ME (2004) Comparison of laparoscopic ovariohysterectomy and ovariohysterectomy in dogs. *Vet Surg* 33: 62-69.
- Ellison GW (1993) Gastric dilatation volvulus. Surgical prevention. *Vet Clin North Am Small Anim Pract* 23: 513-530.
- Fossum TW (2002) Surgery of the bladder and uretra. In: Fossum TW, Hedlund CS, Hulse DA, Jahnsen AL, Seim HB, Willard MD, Carrol GL (2nd ed) *Small animal surgery*. St Luis, Mosby, pp 572-609.
- Grauer GF, Twedt DC, Mero KN (1983) Evaluation of laparoscopy for obtaining renal biopsy specimens from dogs and cats. *J Am Vet Med Assoc* 183: 677-679.
- Hewitt SA, Brisson BA, Sinclair MD, Foster RA, Swayne SL (2004) Evaluation of laparoscopic-assisted placement of jejunostomy feeding tubes in dogs. *J Am Vet Med Assoc* 225: 65-71.
- Hosgood G (1994) Gastric dilatation-volvulus in dogs. *J Am Vet Med Assoc* 204: 1742-1747.
- Howard J G, Barone MA, Donaghue AM, Wildt DE (1992) The effect of pre-ovulatory anaesthesia on ovulation in laparoscopically inseminated domestic cats. *J Reprod Fertil* 96: 175-186.
- Huber DJ (1997) Cystopexy and colopexy for the management of large or recurrent perineal herniai in the dog. *Vet Surg* 26: 218-222.
- Johnson GF, Twedt DC (1977) Endoscopy and laparoscopy in the diagnosis and management of neoplasia in small animals. *Vet Clin North Am* 7: 77-92.
- Lew M, Jałynski M, Brzeski W (2005) Laparoscopic removal of gastric foreign bodies in dogs-comparison of manual suturing and stapling viscerosynthesis. *Pol J Vet Sci* 8: 147-153.
- Lew M, Jałynski M, Kasprowicz A, Brzeski W (2005) Laparoscopic cryptorchidectomy in dogs – report of 15 cases. *Pol J Vet Sci*. 8: 251-254.
- Magne ML, Tams TR, (1999) Laparoscopy: Instrumentation and Technique. In: Tams TR (ed) *Small animal endoscopy*. 2nd ed., Mosby, St. Luis, pp 397-408.
- Massat BJ, Gregory CR, Ling GV, Cardinet GH, Lewis EL (1993) Cystourethropexy to correct refractory urinary incontinence due to urethral sphincter mechanism incompetence. Preliminary results in ten bitches. *Vet Surg* 22: 260-268.
- Miller NA, Van Lue SJ, Rawlings CA (2004) Use of laparoscopic-assisted cryptorchidectomy in dogs and cats. *J Am Vet Med Assoc* 224: 875-878.
- Minami S, Okamoto Y, Eguchi H, Kato K (1997) Successful laparoscopy assisted ovariohysterectomy in two dogs with pyometra. *J Vet Med Sci*. 59: 845-847.
- Monnet E, Twedt DC (2003) Laparoscopy. *Vet Clin North Am Small Anim Pract* 33: 1147-1163.
- Peña FJ, Anel L, Domtnguez JC, Alegre B, Alvarez M, Celorrio I, Anel E (1998) Laparoscopic surgery in a clinical case of seminoma in a cryptorchid dog. *Vet Rec* 142: 671-672.
- Rawlings CA (2007) Resection of inflammatory polyps in dogs using laparoscopic-assisted cystoscopy. *J Am Anim Hosp Assoc* 43: 342-346.
- Rawlings CA (2002) Laparoscopic-assisted gastropexy. *J Am Anim Hosp Assoc*. 38: 15-19.
- Rawlings CA, Foutz TL, Mahaffey MB, Howerth EW, Bement S, Canalis C (2001) A rapid and strong laparoscopic-assisted gastropexy in dogs. *Am J Vet Res* 62: 871-875.
- Rawlings CA, Howerth EW, Bement S, Canalis C (2002) Laparoscopic-assisted enterostomy tube placement and full-thickness biopsy of the jejunum with serosal patching in dogs. *Am J Vet Res* 63: 1313-1319.
- Rawlings CA, Mahaffey MB, Barsanti JA, Canalis C (2003) Use of laparoscopic-assisted cystoscopy for removal of urinary calculi in dogs. *J Am Vet Med Assoc* 222: 759-761.
- Richardson EF, Mullen H (1993) Cryptorchidism in cats. *Compendium on Continuing Education for the Practicing Veterinarian*. 15: 1342-1369
- Richter KP (2001) Laparoscopy in dogs and cats. *Vet Clin North Am Small Anim Pract*. 31: 707-27.
- Rothuizen J (1985) Laparoscopy in small animal medicine. *Vet Q* 7: 225-228
- Shyu JJ, Liu PC (1998) Castration of male dogs using laparoscopic electro-coagulation. *J Chin Soc Vet Sci* 24: 169-178
- Soper NJ, Brunt ML, Brewer JD, Meininger TA (1994) Laparoscopic Bilroth II gastrectomy in the canine model. *Surg Endosc* 8: 1395-1398
- Stone EA (1992) Ovariohysterectomy. In: Stone EA, Barsanti JA (ed) *Urologic surgery of dog and cat*. Philadelphia, Lea Febiger, pp 161-182.
- Stone EA, Cantrell CG, Sharp NJH (1993) Ovary and uterus. In Slatter D (eds) *Textbook of small animal surgery*. Philadelphia, WB Saunders, pp 1293-1307.
- Thiele S, Kelch G, Frank KG (1996) Endoscopy of body cavities and minimal invasive surgery in small animals. *Berl Munch Tierarztl Wochenschr* 109: 288-291.
- Twedt DC (1999) Laparoscopy of the liver biopsy and pancreas. In: Tams TR (ed) *Small animal endoscopy*. 2nd ed., Mosby, St. Luis, pp 409-414.
- Webb CB (2008) Feline laparoscopy for gastrointestinal disease. *Top Companion Anim Med* 23: 193-199.
- Wernecke K, Rummeny E, Bongartz G, Vassallo P, Kivelitz D, Wiesmann W, Peters PE, Reers B, Reiser M, Pircher W (1991) Detection of hepatic masses in patients with wihah carcinoma: comparative sensitivities of sonography, CT, and MR imaging. *AJR Am J Rentgenol* 157: 731-739.
- White RN (2001) Urethropexy for the management of urethral sphincter mechanism incompetence in the bitch. *J Small Anim Pract* 42: 481-486
- Wild DE (1980) Laparoscopy in the dog and cat. In: Harrison RM, Wildt DE (eds) *Animal Laparoscopy*. Baltimore, Williams & Wilkins, pp 31-72.