

DOI 10.1515/pjvs-2015-0083

*Original article*

# The experimental osteoporosis in sheep – clinical approach

**Z. Kielbowicz<sup>1</sup>, A. Piątek<sup>1</sup>, J. Bieżyński<sup>1</sup>, P. Skrzypczak<sup>1</sup>, P. Kuropka<sup>2</sup>,  
J. Kuryszko<sup>2</sup>, A. Nikodem<sup>3</sup>, P. Kafarski<sup>4</sup>, C. Pezowicz<sup>3</sup>**

<sup>1</sup> Department and Surgery Clinic, Faculty of Veterinary Medicine,  
University of Environmental and Life Sciences in Wrocław, Poland

<sup>2</sup> Department of Biostructure and Animal Physiology, Faculty of Veterinary Medicine,  
University of Environmental and Life Sciences in Wrocław, Poland

<sup>3</sup> Department of Biomedical Engineering and Experimental Mechanics, Wrocław University of Technology

<sup>4</sup> Department of Bioorganic Chemistry, Faculty of Chemistry,  
Wrocław University of Technology, 50-370 Wrocław, Poland

## Abstract

The implementation of new methods of osteoporotic therapy requires tests on an animal model. One of the best is the sheep, whose numerous advantages over other models are described in the literature. The aim of this study was induction of osteoporosis using steroids and ovariectomy methods in sheep and description of the change in parameters with regard to healthy sheep. The study was performed on female „merino” breed sheep divided into three groups: Negative control (NC) healthy animals, positive control (PC) ovariectomised animals and steroid group (SC) where methylprednisolone was implemented. Blood tests, diagnostic arthroscopy, quantitative computed tomography and X-Ray micro-tomography of bone were carried out. Blood tests revealed a decreased level of estrogens, progesterone and increased parathormone and cortisol levels in the SC group. A decrease in bone turnover markers and an increase in bone resorption markers in all groups were also noted. Diagnostic arthroscopy revealed osteoarthritis in PC and SC groups. Radiological density tests showed a slight decrease in PC and NC groups whereas there was more than a triple decrease in SC. Results obtained from microCT showed quickly developing osteoporosis in the SC group, which is reflected in numerous parameters analysed in this study. The best effects for osteoporosis induction were obtained using ovariectomised sheep with methylprednisolone injections.

**Key words:** osteoporosis, animal model, indentation, mapping of elements, mechanical examinations, glucocorticosteroids

## Introduction

Osteoporosis is a social disease which – due to the ever-aging population – affects a wide number of people, particularly women, over 50 years of age. It is estimated that in Poland there are 3-5 million people affected by increased risks of fractures due to osteoporosis. In 25-30% of patients – as a result of complications after fractures – it can lead to permanent disabilities and even death within one year after injury (Rabiega et al. 2000). These fractures are also perceived in socio-economic terms due to rising health-care costs. Therefore, it is important to make an early diagnosis and provide appropriate treatment, which can significantly reduce the prevalence of negative outcomes. Changes in the micro-architecture of bone tissue are linked with changes in its mechanical properties (strength) leading to changes within its structure. Osteoporosis has been the subject of studies undertaken by numerous clinical and research centres around the world. The aetiology of this disease has not been fully recognised yet; however, there are numerous hypotheses concerning its formation. One of these states that changes in the structure of spongy bone tissue are caused by imbalances in the process of its resorption and formation. These processes of bone remodelling are controlled by a number of biological and chemical factors such as: level of hormones, quantity of mineral components and nutrients and mechanical stimuli. Disorders within particular stages of bone remodelling are caused by changes in individual pathways of bone metabolism, including excessive bone resorption by osteoclasts.

The experiments are most often conducted on animal models. The sheep model seems to be the best one, due to its appropriate rate of metabolism of bone tissue together with the size and anatomy of its skeleton (Newton et al. 2004, Oheim et al. 2012). Osteoporosis, as defined above, does not directly affect animals, therefore one of the first stages of examination performed in vivo on animal models is to provide conditions which are clinically similar to osteoporosis. This is a rapid loss of bone mass by 30%. There are numerous methods to induce osteoporosis such as: ovariectomy, removal of female gonads, diet change to low protein and micro- and macroelement content, application of corticosteroid medications, limitation of physical activity or immobilisation of animals. The fastest results are achieved through a procedure of ovariectomy, which causes the inhibition of production of estrogens and thus hormonal disorders. In addition, a limited level of physical activity of animals is kept, thus reducing mechanical stimuli which leads to the slowing down of their metabolism. In addition, access to daylight is limited, which causes

metabolic disorders of vitamin D. All of these actions cause a gradual decline of bone tissue density. During the experiments on animals, the best procedure to intensify the decline in bone tissue mass is to introduce an additional steroidal therapy. Therefore, the aim of this study was to induce osteoporosis in sheep and describe the influence of different factors on sheep bone structure.

## Materials and Methods

The study material consisted of 49 „merino” breed sheep (n=49), female, aged 5-6 years, weighing 50-60 kg. Every sheep was weighed before the start of the experiment. The animals were divided into three groups. The first group consisted of sheep which had undergone ovariectomy and a steroidal therapy (SC) (n=35). The second and third groups were treated as a reference (PC n=7 and NC n=7). In the NC group (negative control) neither ovariectomy had been performed nor a steroidal therapy applied at a later stage. The PC group (positive control) consisted of sheep which had undergone only ovariectomy. All the animals during the experiment were kept in the same conditions. In order to reduce their physical activity, they were placed in 10 m<sup>2</sup> boxes, three animals per box. In order to maintain a low protein and mineral components diet throughout the experiment, the sheep were fed only with hay twice a day (water without limit). After their two-week acclimatization period the SC and PC group animals underwent ovariectomy.

In the SC group 30 days after the ovariectomy, methylprednisolone aT dose of 150 mg/sheep was applied four times at 20-day intervals. 21 days after the last application of steroidal treatment the animals were subjected to euthanasia. At the final stage, the sheep were subjected to dissection and their epiphyses were taken for further study. The samples, until examinations, were stored at a temperature of -20°C in double plastic packaging.

## Blood tests

Blood samples were tested twice. The first blood samples were taken from sheep 14 days after the start of the experiment (accommodation time) and the second time on the day of their euthanasia. In each case blood was taken from the jugular vein (Latin: *vena jugularis*). It was subjected to hormones -estradiol, cortisol, progesterone, parathormone, and bone turnover markers: alkaline phosphatase (b-ALP) and CTX level determination tests

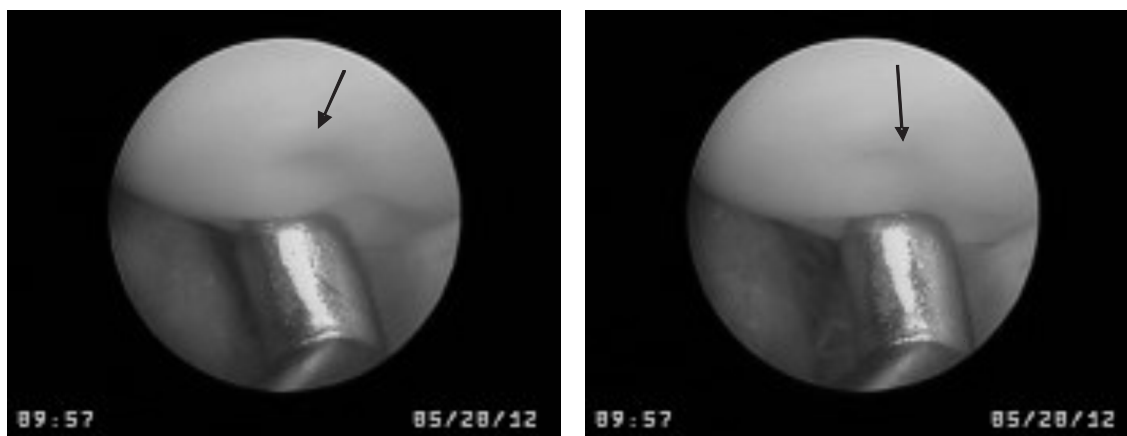


Fig. 1. Examination of the articular surface by the probe during reconnaissance arthroscopy – arrows indicate the deformation of the cartilage after application of the probe.

### Clinical tests

#### Diagnostic arthroscopy

Diagnostic arthroscopy of the knee-joint, with a special focus on the structure of patella surfaces, was the first stage of examinations performed *in vivo*. The treatment of arthroscopy was conducted using rigid-optics with a diameter of 2.7 mm and an angle of 30° made by Karl Storz®. The animals, after general anaesthesia, were placed in the dorsal-ventral position, with a flexion of their pelvic limb knee-joint at an angle of 30°. After inputting an arthroscope into the knee-joint, articular surfaces of the following epiphyses: distal femoral, proximal tibial and patella articular surfaces were recorded. With the use of the probe articular cartilage was examined by pressing its surface. The examination was recorded with the use of an arthroscope camera (Fig. 1).

#### Quantitative computed tomography (QCT)

The use of quantitative computed tomography (QCT) was a subsequent stage of the structural examination. QCT was aimed at visualising the structure of biopats and determination of their radiological density (HU). The biopats were taken from the animal's iliac crests using diamond trephine drills. The examinations were performed with the use of a 64-row DISCOVERY 690 CT scanner made by GE®. Pictures with a layer thickness of 0.625 mm were taken at a resolution of 512x512 pixels. Additionally, a special bone filter (BONE PLUS) was used.

#### X-Ray micro-tomography ( $\mu$ CT)

In order to quantitatively determine the structure of sheep bone tissue, measurements with the use of x-ray micro-tomography were performed. A SkyScan 1172, 100kV, Bruker® micro-tomograph was used for the examinations. An x-ray tube with a spot size <5  $\mu$ m was the source of radiation for the micro-tomograph. The voltage range was 20-100 kV and current range 0-250  $\mu$ A. A CCD: 11 MPx (4000x2100) camera was the x-ray radiation detector. The examinations covered material originating from the following epiphyses: proximal coxal (hip articulation), humeral (shoulder articulation), the glenoid fossa of the scapula and patella. As a result of scanning every 13.5  $\mu$ m of all the samples with dimensions of 10x10x10 [mm], a series of cross-sections at a resolution of 512x512 was obtained. With the use of  $\mu$ TK system software, a level of 3D structural parameters was then determined. The operating parameters analysed in the study include: BV/TV, BS/BV, porosity (open Po.op, closed Po.cl, total Po.tot), structural anisotropy DA, types of examined structures SMI, geometry of bone trabeculae: Tb.N, Tb.Th, Tb. Sp and consistency of examined structures: Conn.Dn.

The study protocol was approved by a local Ethics Commission.

### Results

Blood sample analysis revealed that the level of estradiol decreased in the SC group in relation to the beginning of the experiment. Increases in this parameter were then reported in the both control groups, NC and PC. For progesterone, a major decrease was noted in the SC group and only a minor increase in

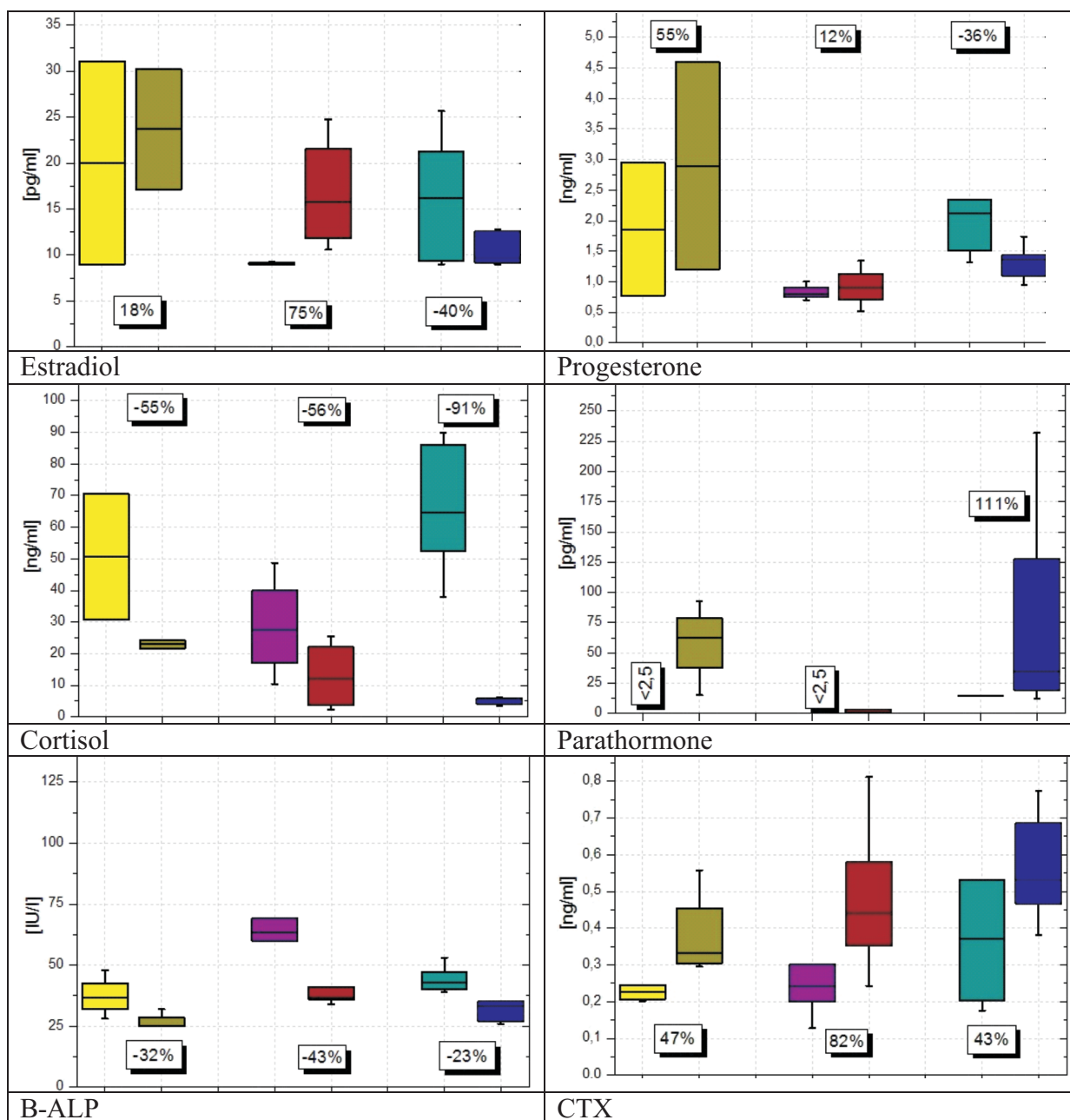


Fig. 2. Level of hormones and bone turnover markers in blood samples at the beginning and at end of the study. Results shown in columns in pairs: before-after. Yellow – Green – NC group, Violet – Red- PC group, Turquoise – Navy blue – SN group.

the PC group. The analysis of cortisol and its levels provided evidence that there were large decrease in the PC and SC groups. The maximal level of cortisol occurred in the group of animals which were given corticosteroids -91% (SC group). The parathormone level was below 2.5 pq/ml in the NC and PC groups – both at the beginning of the experiment and at the end. However, there was an abrupt increase (of 111%) in the SC group. In the analysis of bone turnover markers, it was observed that there was a decline of the bone-formation marker alkaline phosphatase

(b-ALP) by similar values in each of the experimental groups. The most extensive decline occurred in the PC group (43%), while in the SC group the decline was 23%. For the bone resorption marker CTX, the maximal increase in level was observed in the PC group (up to 82%), while added steroidal medications caused a rise of 43% (Fig. 2).

Analysing the results of the first stage of the structural examinations including the diagnostic arthroscopy of the sheep knee-joint, osteoarthritis was present in animals from the PC and SC groups. Among

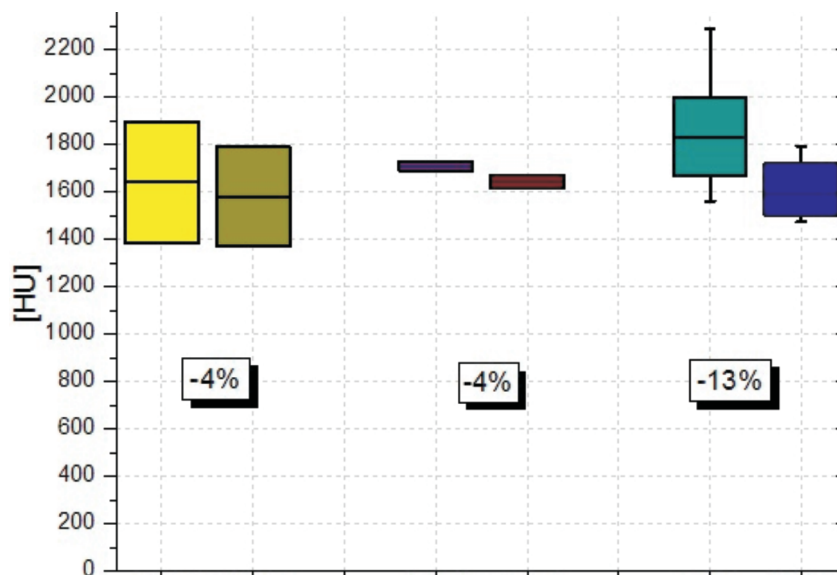


Fig. 3. Radiological density. Results shown in columns in pairs: before-after. Yellow – Green – NC group, Violet – Red- PC group, Turquoise – Navy blue – SN group.

others, it was related to the conditions in which the animals were kept for the duration of the experiment. Small boxes limited animal movements which resulted in reduced movements of their joints. This led to an unequal and inadequate level of nutrition of articular cartilage by nutritional compounds contained in the synovial fluid. However, the major cause of the development of osteoarthritis was the inhibition of production of estrogens after removal of the female gonads (ovariectomy).

There was a slight decrease in bone radiological density (4%) in the positive and negative control groups. In the group of sheep which additionally received steroidal medications, a more than triple decline of bone radiological density was perceived (13%) (Fig. 3).

On the basis of the results obtained it can be observed that – in comparison with the negative control group – the samples of proximal femoral bone epiphysis in the group treated with ovariectomy (PC) are characterised by higher values of their structural parameters related to an increase in volume of tissue and a decrease in porosity. These samples are characterised by a larger number of trabeculae (28%) and consistency (38%) and additionally by increased thickness (1.5%). Changes in the values of these parameters cause the nature of the tissue (into more plate-based) to change as well (SMI parameter). In addition, by introducing a therapy with steroidal medications, bone tissue of the proximal femoral bone epiphyses changes its structural properties becoming more porous (increased porosity by 19%). Changes in its porosity are related to a reduction in the number of

bone trabeculae (21%), consistency (34%) and thickness (5%). The samples from the SC group change their nature (they become more mixed). By analysing the results obtained it can be stated that bone tissue of humeral bones, similarly as for glenoid fossa of the scapula, are characterised by a very high level of porosity (up to 80%), which still increase in sheep treated with ovariectomy (PC and SC). The porosity rises in spite of an increasing average number of bone trabeculae (32%) and their combinations (54%). Tissues are characterised by their firmly plate-based nature. In both groups there is a thinning of bone trabeculae (PC 26%, SC 5%), which leads to changes in the total porosity of the samples (0.5%).

In the case of the samples taken from the patellae for analysis, it can be observed that there was an increase in density and a decrease in porosity both in the PC group in relation to the negative control group and in the SC group in relation to the positive control group. The samples from the PC group are characterised by a 26% increase in thickness with their decreased number (14%) and lowered consistency (64%). Following the introduction of steroidal medications, the porosity of bone tissue at the patellae decreases even further and the consistency (103% up) and number of bone trabeculae increase (2.5% up) while their thickness decreases (3% down). By analysing the results obtained it can be observed that there is an increase of factual density in the group of sheep treated with ovariectomy in relation to the negative control group (16% up). The introduction of steroidal medications causes a drop in the parameter (7.5% down) in relation to the ovariectomy group.

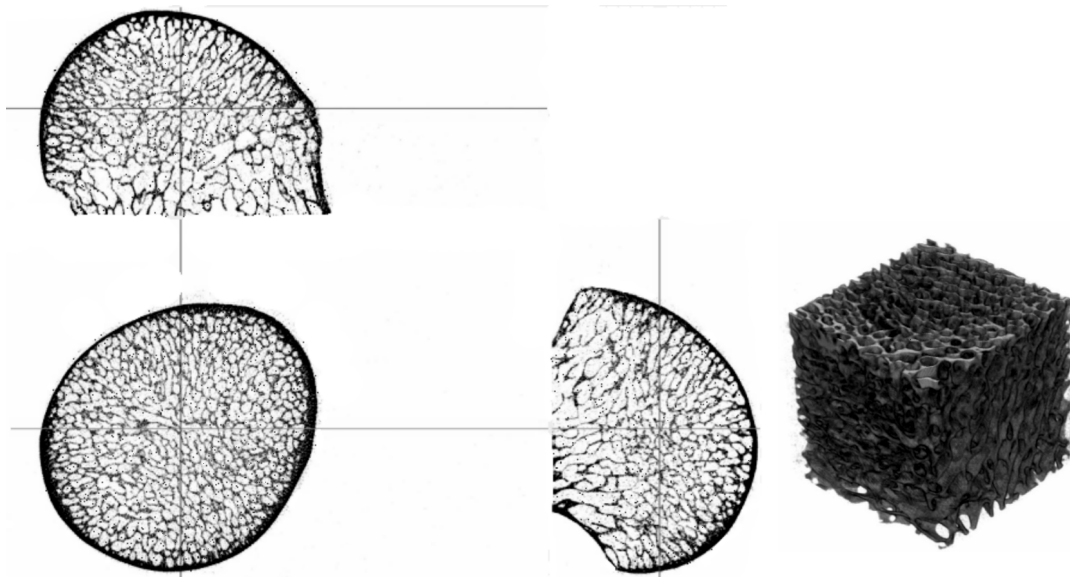


Fig. 4. MicroCT sample of bone from femur head before micro CT analysis from SC group.

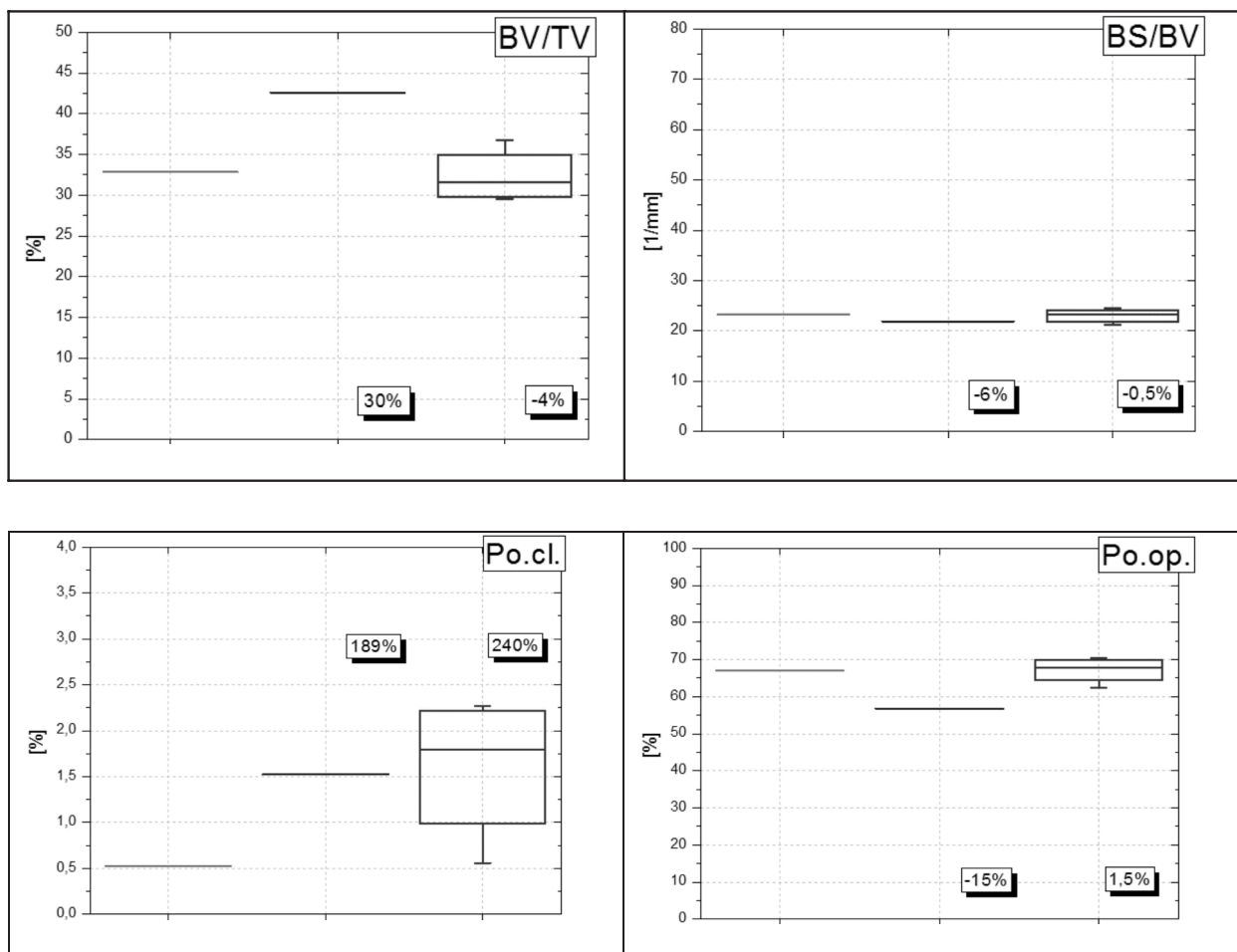
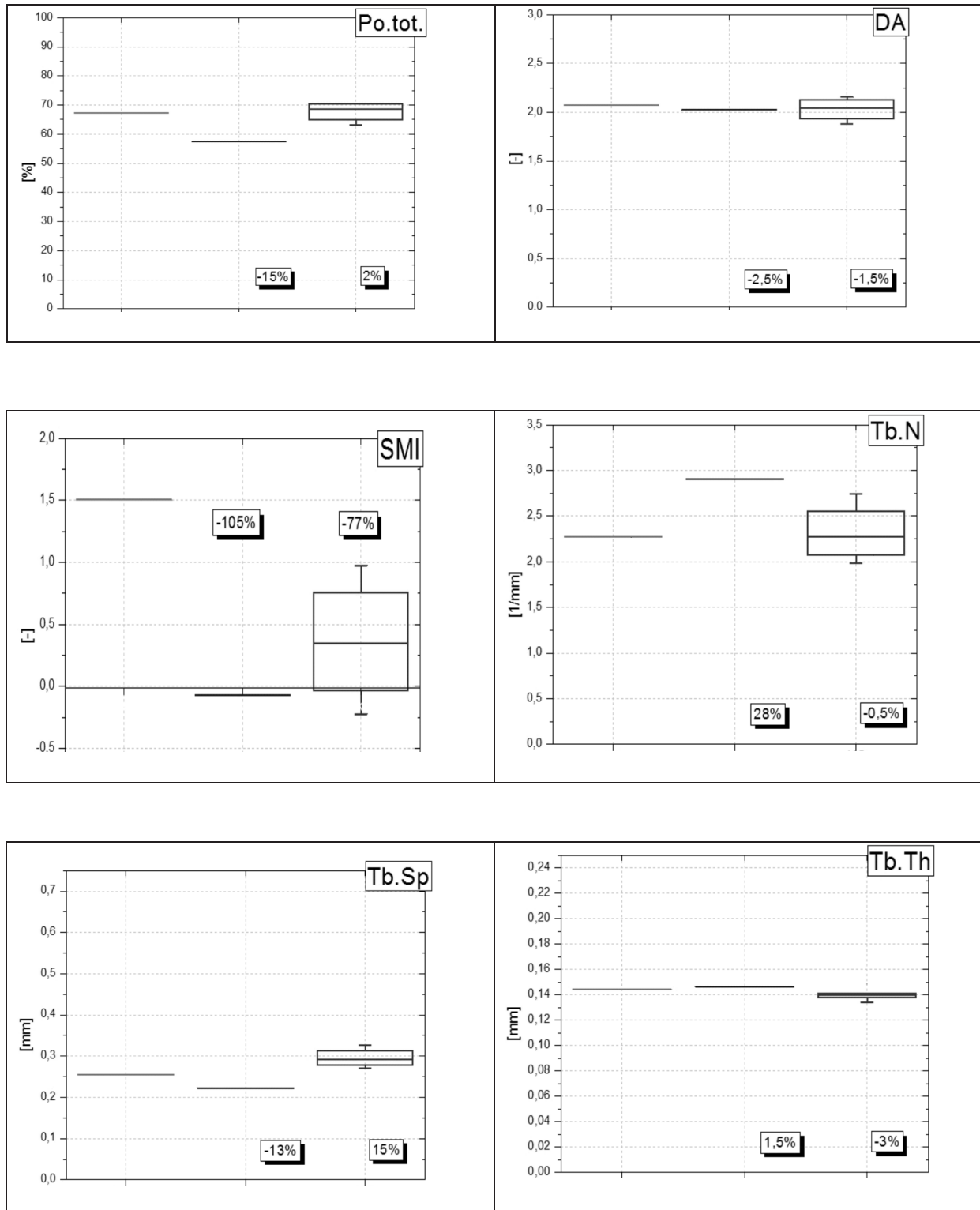
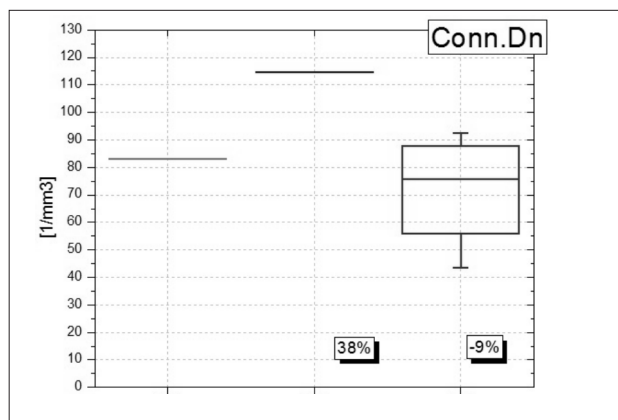


Fig. 5



cont. Fig. 5



cont. Fig. 5. Morphometrical results of bone samples (femoral head) obtained by microCT analysis Green- NC group, Navy blue- PC group, Violet- SC group.

While agreeing with Sigrist et al. (2007) that the measurement of density of bone is not sufficient to determine the strength of bones and the scope of their reconstruction, histomorphometric examinations of bone samples were performed with the use of microCT. The parameters specifying changes of bone density (BV/TV, Tb.N, Tb.Th, Conn.Dn) and changes of porosity (Po.tot, Po.cl, Po.op, BS/BV) were determined. Similar parameters were monitored by Turner et al. (1995) and Schorlemmer et al. (2003). By analysing the obtained results, it can be observed that in the group of sheep treated with ovariectomy (PC) in relation to the negative control group (NC), based on the samples from the proximal femoral bone epiphyses, the group is characterised by a general increase in bone density parameters and a decrease in porosity, including total density of 15%. Samples from the SC sheep, based on samples from the proximal femoral bone epiphyses, indicate that there was a decrease in bone density parameters and an increase in porosity in relation to the PC group. Thus, it may be concluded that the application of steroidal medication significantly affects bones and their micro-architecture, which leads to the thinning of bone trabeculae (Tb.Th 5%), reduced level of bone trabeculae (Tb.N 22%), decreased bone tissue in volume per sample (BV/TV 26%), lowered consistency (ConnD 34%). In addition, these medications also increase bone porosity (Po.tot 19%, Po.cl 18%, Po.op 20%, BS/BV 6%). These results are confirmed by Lill et al. (2002) where they state that glucocorticosteroids in sheep lead to a reduced number of bone trabeculae (Tb.N), and decreased consistency and number of connections (ConnD down). In contrast, in humans they reduce the thickness of bone trabeculae (Tb.Th down) and do not cause changes in their consistency (Fig. 4, 5).

## Discussion

Data from the literature indicate that bone turnover markers can be useful to determine and assess rates of bone reconstruction and to monitor changes taking place in the course of osteoarthritis. Their concentration is the result of activities of all reconstruction processes occurring in the skeletal system within a given period of time (de Ridder et Delemarre-van de Waal 1998). As there are not many reports related to the study of bone turnover markers and their levels in animals in the world literature, the present study includes the examination of CTX and its level as a marker of bone resorption, and b-ALP and its level as a marker of bone formation in order to establish (or exclude) the relevance of these parameters in further examinations and studies. Peichl et al. (2001) indicated that CTX shows positive correlations with bone mass loss in patients affected with osteoporosis – it may serve as an indicator of fracture risk. Gajewska et al. (1999) – in order to assess bone formation processes – used a bone fraction of alkaline phosphatase which is synthesized by osteoblasts and released into the blood at the middle stage of bone formation. The examinations performed in sheep demonstrated an increased level of CTX bone resorption marker in sheep from the PC group, and a higher level in sheep from the SC group. In the case of b-ALP bone-formation marker, its decrease can be observed in each of the experimental groups. In practical terms this means that there are ongoing processes of bone remodeling with predominant processes of bone resorption (increased levels of CTX in all the examined groups), and decreased levels of b-ALP indicate a retardation or disruption in the process of mineralisation of bones in which it plays an important role. The results of these test indicate that the monitoring of markers of bone turnover is strongly recommended for diagnosis of osteoporosis. (Fig. 2).

Osteoarthritis connected with a lack (deficiency) of estrogens was studied by Roman-Bias et al. (2009) who disagreed with the statement that – in contrast to other tissues such as the endometrium, mammary gland and brain – articular cartilage tissue is not responsive to estrogens and their deficiency. In their examinations on rabbits, they proved that ovariectomy significantly affects osteoarthritis, and additional supplies of glucocorticosteroids accelerate its occurrence and increases the scope of the disorder. Examinations conducted in sheep confirmed the results obtained by Roman-Bias et al. (2009). Sheep from the PC group were affected with osteoarthritis at the first level according to the Outerbridge classification, while sheep from the SC group developed degen-



erative articular cartilage diseases at the first and second level. Pathology of the cartilage was seen particularly well at articular surfaces of their patellae when examined by means of probing. In the case of osteoarthritis induced by a deficiency of estrogens it should be remembered that the effect of glucocorticosteroids on articular cartilage is dependent on the particular dose of medication applied. Taking into account their dual role (their trophic impact on chondrocytes and their anti-inflammatory properties) such a dose of medication can be determined which will elicit therapeutic effects in the course of osteoarthritis Canas et al. (2014).

Many authors observed minor and insignificant declines of bone mass. Lill et al. (2002) in their studies noted 5.5% decline in bone density in the group of sheep treated with ovariectomy. Also Turner et al. (1995), Turner (2002) and Newman et al. (1995) noted a reduced level of bone density of 3% – 8%. Another study (Sigrist et al. 2007) indicates that within 4 months after the treatment of ovariectomy the decline of bone mass within 13%. Examinations conducted 4 months after the treatment of ovariectomy gave similar results to those obtained by Lill et al. (2002), Turner et al. (1995), Turner (2002) and Sigrist et al. (2007).

We noticed a decline of radiological density of 4% in relation to the baseline level in the PC group. Guided by other researchers' insights, examinations of radiological density of bones were also made in the group of sheep treated with steroidal medications (SC). Schorlemmer et al. (2003) in their studies proved that treatment with steroidal medications for a long time would lead to secondary osteoporosis and would intensify changes taking place in the skeletal system. After a six-month application of glucocorticosteroids, a biopsy of tibial bones showed a decrease in bone density of 19%. QCT examinations of sheep from the SC group confirmed that through the application of glucocorticosteroids, after 4 months, there was a decline in radiological density of 13% in relation to the baseline. Results obtained from measurements of the radiological density of bones, indicate that ovariectomy itself did not lead to sufficient loss of bone mass. In contrast, the add-in application of glucocorticosteroids resulted in a more than 3-fold decrease in the value of the parameter.

Comparison of the results obtained in the  $\mu$ CT examinations in the PC group with the results achieved by Newman et al. (1995) who studied the impact of ovariectomy on bones and their micro-structure, indicate that the divergences probably arise from variances in the maintenance of the animals and the duration of the study. As for the SC group, we find confirmation of the results in the literature; Lill et al.

(2002) in their studies on the effects of steroids on bone tissue obtained very similar results.

The effect of steroids on the structure of bone and cartilage tissues of epiphyses is complex and results, among others, from disturbances in the metabolism of calcium, reduced activity of sex hormones and the direct impact of glucocorticosteroids on bone and cartilage tissue cells. A model of sheep as a large animal for the study of osteoporosis illustrates reduced bone turnover and suppressed mineralisation of bone tissue. Low rates of bone formation and resorption reduce the mechanical strength of the skeleton. The rate of metabolic bone turnover is inversely proportional to the level of estrogens which determines its impact on bone mass in postmenopausal periods in humans. With increasing age there is a dominance of resorption processes over bone-formation and increased loss of bone mass. The assessment of bone turnover and its rates could be made through „bone turnover markers” with its concentration determined in sheep blood and analysed in this study. The biochemical levels of the bone turnover markers are the result of all the reconstruction processes taking place in a given time within the whole skeleton. Their levels allows for prompt assessment of rates of growth of bone-formation and resorption processes, which is very important in foreseeing fractures and bone mass changes when under treatment. The use of numerous research methods in this study in order to diagnose osteoporosis presents an extensive range of diagnostic capabilities to be applied for early detection of osteoporosis being currently available in medicine. Each of the applied methods brings us closer to providing correct and reliable diagnoses. It is concluded that in the diagnosis of osteoporosis, the assessment of changes and their range taking place in the body requires the application of methods aimed at assessing the structural and – simultaneously – mechanical properties of bone tissue.

### Acknowledgements

The work Was supported by Wroclaw Research Centre EIT+ within the project „Biotechnologies and advanced medical technologies” – BioMed (PZIG.01.01,02-02-003/08) co-financed by the European Regional Development Fund (operational Programme Innovative Economy, 1. 1. 2).

### References

An YH, Gruber HE (2003) Introduction to Experimental Bone and Cartilage Histology. In: An YH, Martin KL

- (eds) Handbook of Histology Methods for Bone and Cartilage, 1st ed., Totowa, NJ, Human Press Inc, pp 3-31.
- Canas CA, Osorio JC, Coronel N, Cepeda CM, Izquierdo HJ, Bonill-Abadia F (2014) Efficacy and safety of oral low-dose glucocorticoids in patients with estrogen-dependent primary osteoarthritis. *Rheumatol Int* 34: 733-735.
- de Ridder CM, Delemarre-van de Waal HA (1998) Clinical utility of markers of bone turnover in children and. *Curr Opin Pediatr* 10: 441-448.
- Gajewska J, Ambroszkiewicz J, Laskowska-Klita T (1999) Biochemical markers of bone turnover and their use. *Med Wieku Rozwoj* 3: 421-432.
- Hacker SA, Suh JK, Marui T, Woo SL (1992) Compressive properties of the human meniscus. *Trans Orthop Res* 17: 627.
- Lill CA, Fluegel AK, Schneider E (2002) Effect of ovariectomy, malnutrition and glucocorticoid application on bone properties in sheep: a pilot study. *Osteoporosis Int* 13: 480-486.
- Newman E, Turner AS, Wark JD (1995) The potential of sheep for the study of osteopenia: current status and comparison with other animals models. *Bone* 16: 277-284.
- Newton J, Cooper RC, Gilbert JA, Johnson RB, Zardiachas LD (2004) The ovariectomized sheep as a model for human bone loss. *J Comp Path* 130: 323-326.
- Oheim R, Amling M, Ignatius A, Pogoda P (2012) Large animal model for osteoporosis in humans: the ewe. *Eur Cell Mater* 24: 372-385.
- Peichl P, Griesmacher A, Marteau R, Hejc S, Kumpan W, Muller MM, Broll H (2001) Serum crosslaps in comparison to serum osteocalcin and urinary bone resorption markers. *Clin Biochem* 34: 131-139.
- Proctor CS, Schmidt MB, Whipple RR, Kelly MA, Mow VC (1989) Material properties of the normal medial bovine meniscus. *J Orthop Res* 7: 771-782.
- Rabiega D, Woźniak J, Olejniczak T, Opala T (2000) Osteoporosis – epidemiology, pathogenesis, diagnostics and treatment. *Przew Lek* 9: 39-46.
- Roman-Bias JA, Castaneda S, Largo R, Herrero-Beaumont G (2009) Osteoarthritis associated with estrogen deficiency. *Arthritis Res Ther* 11: 241.
- Schorlemmer S, Gohl Ch, Iwabu S, Ignatius A, Claes Lutz, Augat P (2003) Glucocorticoid Treatment of Ovariectomized Sheep Affects Mineral Density, Structure, and Mechanical Properties of Cancellous Bone. *Bone Miner Res* 18: 1010-1015.
- Sigrist IM, Gerhardt C, Alini M, Schneider E, Egermann M (2007) The long-term effects of ovariectomy on bone metabolism in sheep. *J Bone Miner Metab* 25: 28-35.
- Sweigart MA, Athanasiou KA (2004) Biomechanical characteristics of the normal medial and lateral porcine knee menisci. *Proc I Mech E* 219 Part H: JEngineering in Medicine.
- Turner AS, Alvis M, Myers W, Stevens ML, Lundy MW (1995) Changes in bone mineral density and bone-alkaline phosphatase in ovariectomized ewes. *Bone* 17: 395-402.
- Turner AS (2002) The sheep as a model for osteoporosis in humans. *The Veterinary Journal* 163: 232-239.
- Uklejewski R, Winiński M, Rogala P (2006) Zgodność strukturalno-adaptacyjna połączeń kości z porowatymi implantami na podstawie tradycyjnego jednofazowego i współczesnego dwufazowego porosprężystego modelu biomechanicznego tkanki kostnej. *Engineering of Biomaterials* 1-13: 54-55