

DOI 10.24425/pjvs.2021.139970

Original article

# Morphometric and cytological disturbances of pancreatic islets evoked by congenital portosystemic shunt in dogs

J. Frymus<sup>1</sup>, P. Trębacz<sup>1</sup>, M. Sobczak-Filipiak<sup>2</sup>, M. Czopowicz<sup>3</sup>, M. Galanty<sup>1</sup>

<sup>1</sup>Department of Small Animal Diseases with Clinic,

<sup>2</sup>Department of Pathology and Veterinary Diagnostics,

<sup>3</sup>Division of Veterinary Epidemiology and Economics, Institute of Veterinary Medicine, Warsaw University of Life Sciences – SGGW, Nowoursynowska 159c, 02-776 Warszawa, Poland

## Abstract

In 46 dogs with congenital portosystemic shunt (cPSS) histopathological examination of the pancreas, including measuring of the islet area, was performed, and the results were compared with those obtained in 6 control dogs without cPSS. Pancreatic islets were found in 43 (94%) dogs with cPSS and in all control animals. Mean area of the pancreatic islets was significantly lower in cPSS patients (median of 2219.4  $\mu\text{m}^2$ , interquartile range [IQR] from 1559.0 to 3146.2  $\mu\text{m}^2$ , range from 485.4 to 10333.4  $\mu\text{m}^2$ ) than in control dogs (median of 8705.5  $\mu\text{m}^2$ , IQR from 8284.4 to 9329.2  $\mu\text{m}^2$ , range from 7689.9 to 9624.2  $\mu\text{m}^2$ ) ( $p < 0.001$ ). The area of pancreatic islets was weakly, but significantly, positively correlated with the body weight of dogs ( $r = 0.32$ ,  $p = 0.026$ ), but not with the age or sex. Vacuoles were found in the cytoplasm of pancreatic islet cells in 37 (87%) dogs with cPSS and in none of the control animals ( $p < 0.001$ ). Their presence was not linked to the sex, breed, age or body weight. Extracellular homogenous eosinophilic masses were present in pancreatic islets in 5 (12%) cPSS patients and in none of control animals. Connective tissue hyperplasia was found in pancreatic islets of 4 (9%) dogs with cPSS and in none of the control dogs. These results indicate that cPSS severely affects the pancreas, as shown by significantly reduced area of the islets, and the presence of eosinophilic masses in the pancreas and/or intracellular vacuoles.

**Key words:** congenital portosystemic shunt, dogs, pancreatic islets

Table 1. Demographic characteristics of the patients with congenital portosystemic shunt (cPSS) and control dogs.

Characteristics	Group		p-value
	cPSS (n=46)	Control (n=6)	
Age [months] <sup>a</sup>	11, 5-18 (3-70)	12, 11-20 (11-24)	0.266 <sup>b</sup>
Body weight (BWT) [kg] <sup>a</sup>	3.3, 2.4-6.5 (1.0-32.0)	8.5, 4.0-12.0 (3.5-23.0)	0.039 <sup>b</sup>
Sex – n (%) of females	27 (58.7)	4 (66.7)	0.946 <sup>c</sup>
Pedigree dogs – n (%)	40 (87.0)	4 (66.7)	0.488 <sup>c</sup>
Breed size (of adult):			
Small (BWT <15 kg)	39 (84.8)	5 (83.3)	0.610 <sup>c</sup>
Large (BWT >15 kg)	7 (15.2)	1 (16.7)	
Breeds	Yorkshire terrier (n=13) Maltese (n=8) Crossbreed (n=6) Shih Tzu (n=5) Golden retriever (n=3) West Highland White Terrier (n=2) Miniature pinscher, Papillion, Dachs- hund, Bolognese, Chinese crested dog, Cane corso, Fila brasileiro, Hovawart, German shepherd (n=1)	Crossbreed (n=2) Beagle, Miniature pinscher, Yorkshire terrier, Maltese (n=1)	

<sup>a</sup> median, interquartile range (IQR), and range

<sup>b</sup> unpaired Student's t-test on logarithmically transformed data

<sup>c</sup> chi-square test with Yates continuity correction

## Introduction

Portosystemic shunt (PSS) is one of the most common congenital abnormalities in dogs (Tobias and Rohrbach 2003). It is a life-threatening vascular anomaly, allowing portal blood to bypass the liver and directly enter the systemic circulation (Mankin 2015). It results in the accumulation of toxic substances such as ammonia in the systemic circulation and may lead to hepatic encephalopathy (Perazzo et al. 2012). An increased blood manganese concentration, ammonium-urate urolithiasis, and a systemic inflammatory response syndrome (SIRS) may also result from this anomaly (Tivers et al. 2014, Gow 2017).

In dogs with congenital PSS (cPSS), vomiting and diarrhea are most prominent clinical signs, frequently accompanied by polydipsia, polyuria, urolithiasis, growth retardation and poor development (Frymus et al. 2015). Moreover, a variety of neurological disorders, resulting from hepatic encephalopathy, are frequently present.

Clinical signs of cPSS result not only from the direct flow of blood rich in potentially deleterious chemical substances from the portal to general circulation but also from hypoperfusion and decreased function of the liver. Therefore, the liver structure and function of such patients has been intensively studied, and many morphological and functional hepatic disorders have been identified (Baade et al. 2006, Sobczak-Filipiak et al. 2018b). As liver is the main site of glu-

cose metabolism, decreased hepatic function can result in hypoglycemia which is frequently observed in dogs with cPSS (Collings et al. 2012, Kraun et al. 2014). On the other hand, pancreas is the major organ responsible for regulation of glucose level in blood, and its dysfunction may be also responsible for hypoglycemia. However, hyperinsulinemia has been rarely observed in cPSS patients, and need of further studies on this topic has been indicated (Collings et al. 2012). A rare human condition, nesidoblastosis, characterized by pancreatic islet cell hyperplasia may lead to hypoglycemia, usually accompanied by central neurological disorders. Recent reports indicate that nesidoblastosis should be considered in humans with idiopathic hypoglycemia if the insulin level is inadequate to glycemia (Raffel et al. 2007, Przybylik-Mazurek et al. 2012). Until recently, studies in dogs with cPSS have focused mostly on liver disorders, and data on pancreas structure and function in such patients are hardly available. In a preliminary study on dogs with cPSS, we found abnormal structures in the pancreatic islets (Frymus et al. 2020). Furthermore, the length and width of the islets were smaller than considered as physiological in dogs. Nevertheless, this observation needs confirmation as no control group of healthy dogs was included. Therefore, this study aimed to verify if dogs suffering from cPSS had smaller pancreatic islets than control animals, and to characterize the details of pancreatic islet structure in such patients.

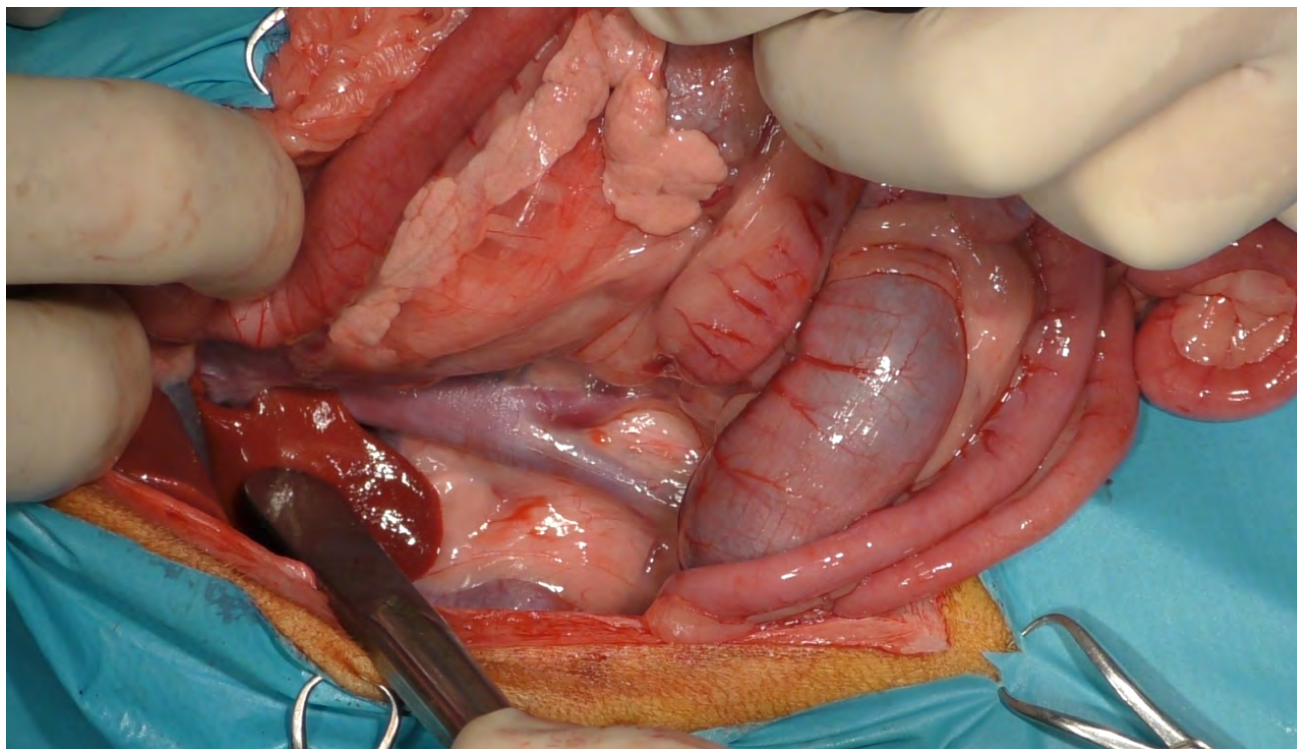


Fig. 1. Intraoperative view of the pancreas before collecting a sample for histopathological examination (caudal right lobe of the pancreas).

## Materials and Methods

**Animals and collection of pancreatic fragments.** The study was performed on 46 dogs with cPSS. Detailed characteristic of the study population is presented in Table 1. Due to common abnormal glucose level in such patients small fragments of the pancreas were collected for diagnostic purposes during the surgical closing of the pathological blood vessel bypassing the liver as described earlier (Frymus et al. 2020). As a control group we enrolled 6 dogs after traffic accidents. These animals did not have cPSS nor any other conditions besides the post-traumatic ones. If an explorative laparotomy confirmed incurable multi-organ damage and euthanasia was decided, pancreas fragments were collected before performing euthanasia. Thus, both in the study and control dogs the tissue fragments were obtained in deep general anesthesia as described earlier (Frymus et al. 2020). In both the cPSS and control dogs a small fragment of the caudal right lobe of the pancreas was removed using a guillotine knot technique (Fig. 1). The tissue fragment was immediately fixed in buffered 10% formaldehyde and sent for histopathological examination.

**Histopathological examination.** Samples were embedded in paraffin (Paraplast), ultrathin (4  $\mu\text{m}$ ) slices were cut using a rotational microtome, and stained routinely with hematoxylin/eosin (Varistain Gemini, Thermo Scientific). Histopathology was performed using

a light microscope Olympus BX 43 (Olympus Optical, Ltd, Tokyo, Japan) connected to a computer and SC30 camera. Using the closed polygon function of the CellSens Entry Olympus software as well as careful manual surrounding of the islet contours (with 40x objective magnification) the area ( $\mu\text{m}^2$ ) of randomly selected 2 (in 19 dogs) or 3 (in 30 animals) pancreatic islets was measured, and mean islet area of each dog was used in the statistical analysis.

**Statistical analysis.** As the distribution of all numerical variables (age, body weight, pancreatic islet area) was significantly right-hand asymmetric according to histograms and Shapiro-Wilk test, they were presented as the median, interquartile range (IQR) and range. For statistical analyses numerical variables were logarithmically transformed (natural logarithm). They were compared between groups using unpaired Student's t-test and correlation between numerical variables was examined using Pearson's linear correlation coefficient ( $r$ ). Pancreatic islet area was compared between cPSS and control dogs using the analysis of covariance (ANCOVA), and variables significantly linked both to the pancreatic islet area and to the group were included as covariates. Categorical variables were given as count and percentage in a group, and compared using the chi-square test with Yates continuity correction. All tests were two-tailed. A significance level ( $\alpha$ ) was set at 0.05. Statistical analysis was performed in TIBCO Statistica 13.3 (TIBCO Software Inc., Palo Alto, CA, USA).



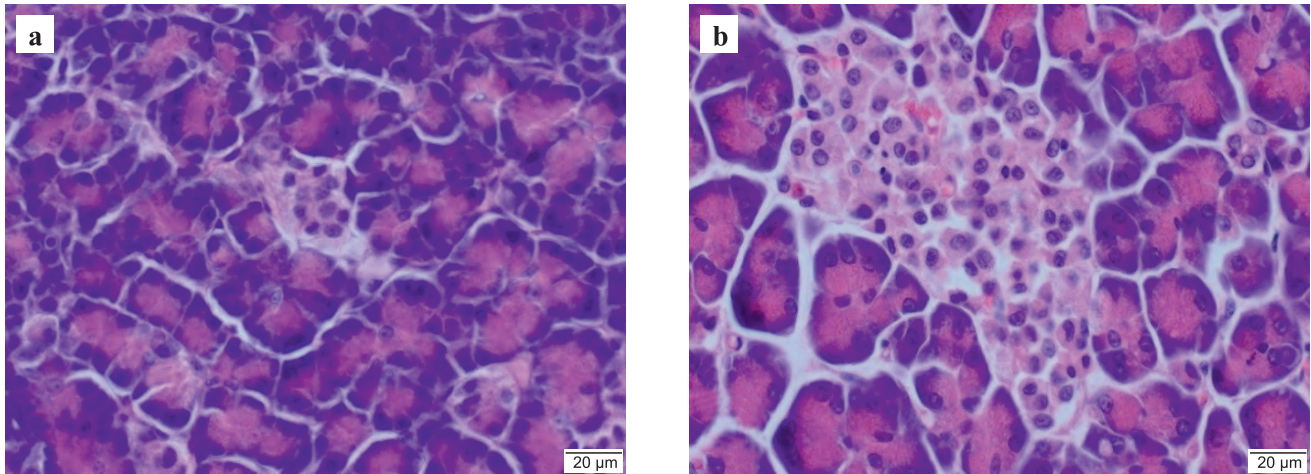


Fig. 2. Microscopic picture of pancreatic islets: left (a) – a dog with congenital portosystemic shunt, right (b) – a control dog.

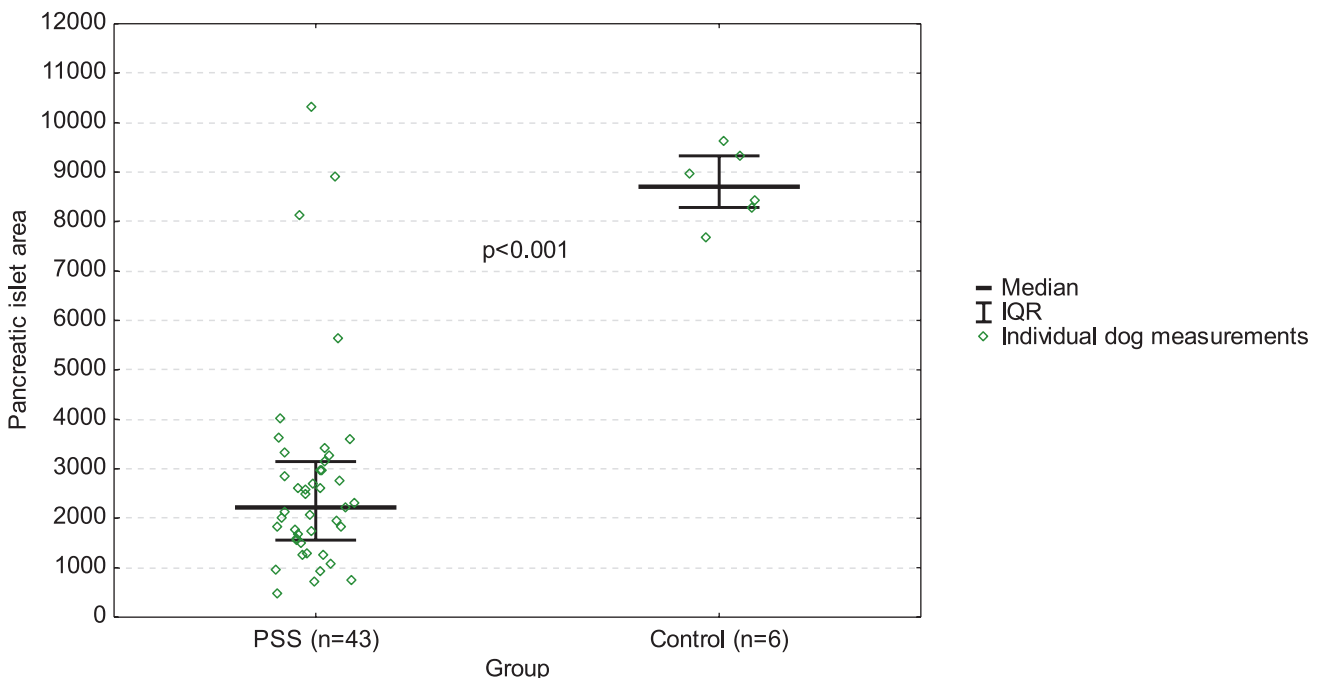


Fig. 3. Median pancreatic islet area ( $\mu\text{m}^2$ ) in 43 dogs with congenital portosystemic shunt (PSS) and 6 control dogs presented as the median, interquartile range (IQR), and individual dog measurements.

## Results

Pancreatic islets were found in 43 of 46 (94%) dogs with cPSS and in all control animals, and this difference was insignificant ( $p=0.775$ ).

The area of pancreatic islets was weakly, but significantly, positively correlated with the body weight of dogs ( $r=0.32$ ,  $p=0.026$ ) (Table 1). On the other hand, it did not differ significantly between males and females ( $p=0.894$ ), neither was it significantly correlated with age ( $r=0.27$ ,  $p=0.059$ ). As body weight of the dogs was the only characteristic which differed significantly between cPSS and control group ( $p=0.039$ ), it was included as a covariate in ANCOVA. Controlled for

body weight (the average body weight set at 4.4 kg) pancreatic islet area proved to be significantly lower in dogs with cPSS (median of  $2219.4 \mu\text{m}^2$ , IQR from  $1559.0$  to  $3146.2 \mu\text{m}^2$ , range from  $485.4$  to  $10333.4 \mu\text{m}^2$ , Fig. 2a) than in control dogs (median of  $8705.5 \mu\text{m}^2$ , IQR from  $8284.4$  to  $9329.2 \mu\text{m}^2$ , range from  $7689.9$  to  $9624.2 \mu\text{m}^2$ , Fig. 2b) ( $p < 0.001$ ) (Fig. 3).

Vacuoles (Fig. 4a and 4b) were found in the cytoplasm of pancreatic islet cells in 37 of 43 (87%) dogs with cPSS and in none of the control animals ( $p < 0.001$ ). Vacuoles were present equally often in males and in females with cPSS ( $p=0.367$ ) as well as in crossbreed and pedigree dogs ( $p=0.668$ ). Their presence was neither linked to the age ( $p=0.650$ ) nor to the body weight

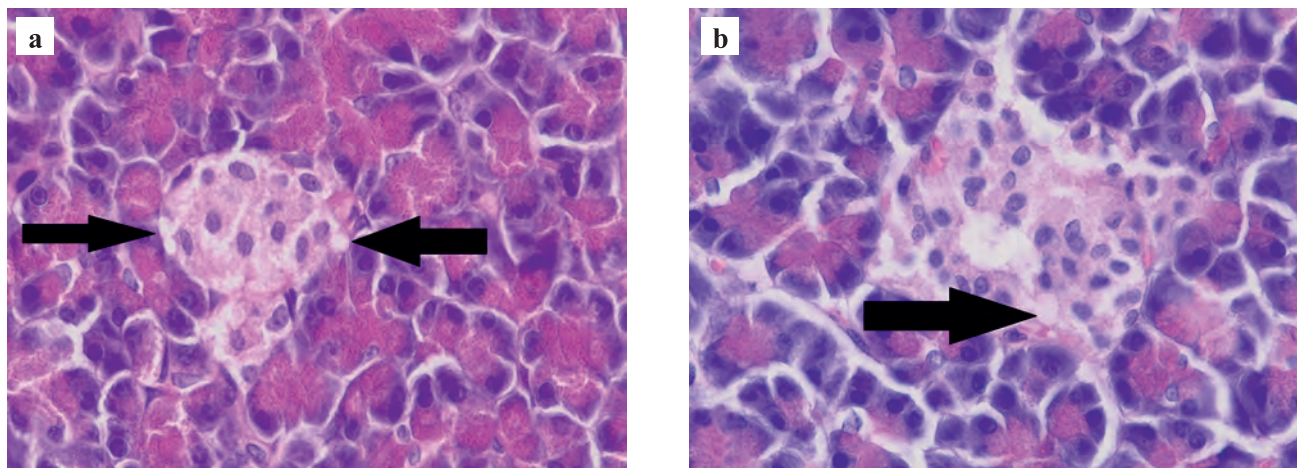


Fig. 4a and 4b. Vacuoles in the cytoplasm of the pancreatic islet cells of a dog with congenital portosystemic shunt. Cytoplasmic vacuoles (black arrow).

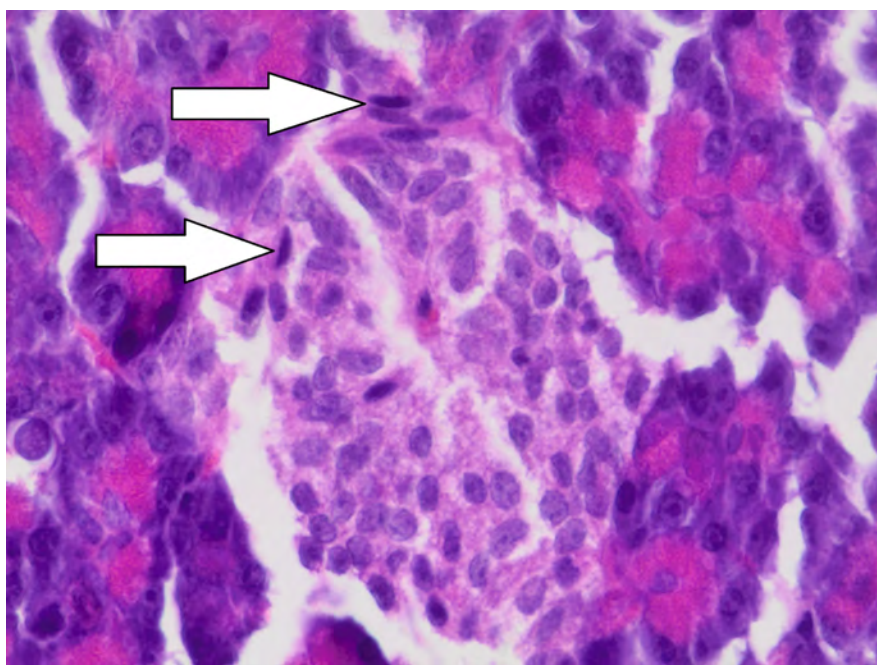


Fig. 5. Connective tissue hyperplasia in an pancreatic islet. Fibroblasts (white arrow).

( $p=0.087$ ). Extracellular homogenous eosinophilic masses were present in pancreatic islets in 5 of 43 (12%) dogs with cPSS and in none of control animals ( $p=0.872$ ). Connective tissue hyperplasia was found in pancreatic islets of 4 of 43 (9%) dogs with cPSS and in none of the control animals ( $p=0.987$ ) (Fig. 5). In one cPSS patient a few lymphocytes and plasma cells were present in pancreatic islets (Fig. 6).

## Discussion

In our preliminary study we found that in dogs with cPSS the length and width of the pancreatic islets were smaller than the literature data reported for normal dogs

(Frymus et al. 2020). However, these literature data were not only scant, but also did not consider the age and body weight of the dogs, whereas cPSS patients are often puppies. In the present study due to possibility to obtain pancreas fragments from dogs that were clinically healthy, a control group could be included. Tissue fragments were obtained from the cPSS and control animals under anesthesia and came from the same region of the pancreas. Both groups of dogs were comparable in terms of most of basic characteristics (Table 1) except the body weight, which was higher in control animals. This might have possibly accounted for bigger pancreatic islet area in these dogs. Therefore, the analysis was adjusted by the potential influence of the body weight, and the conclusion that dogs



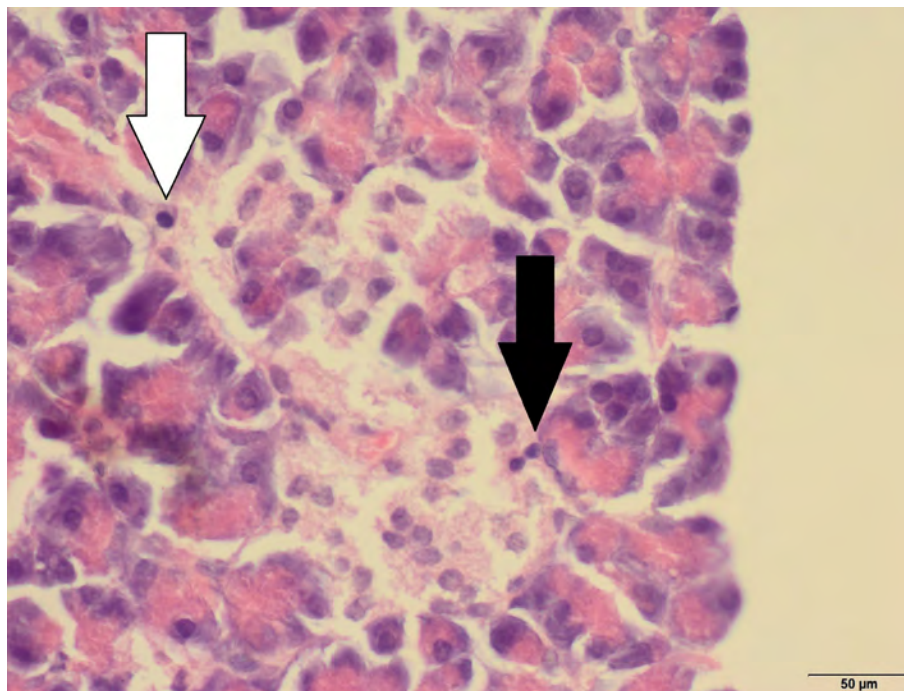


Fig. 6. A lymphocyte (black arrow) and a plasma cell (white arrow) in a pancreatic islet.

with cPSS have significantly smaller pancreatic islets (median of  $2219.4 \mu\text{m}^2$  versus  $8705.5 \mu\text{m}^2$ ,  $p < 0.001$ ) (Fig. 2a and 2b) appears to be justified. It is not clear, whether this is islet hypoplasia or atrophy. Interestingly, 3 out of 46 cPSS patients had no pancreatic islets at all. Evaluation on a bigger group of such dogs is needed to clear, if this reflected a more advanced stage of cPSS-induced disease. It should be stressed that pancreatic islets are not homogenous in terms of cell composition. They contain four types of cells with different secretory activity. The  $\alpha$ -cells are secreting glucagon,  $\beta$ -cells are producing insulin,  $\delta$ -cells secrete somatostatin, and PP-cells are producing a regulatory polypeptide. Up to 82% of all canine islet cells are classified as  $\beta$ -cells (Muranishi et al. 1999). Further studies are necessary to determine which type on cells is affected by the cytological disturbances presented in this study.

The mechanisms leading to the morphological and cytological abnormalities presented in this paper remain unknown. However, cPSS is well-known to lead to dramatic local circulatory disturbances. In many patients the portal venous system is hypoplastic (Sobczak-Filipiak et al. 2018a, 2019), and the blood pressure changes in these veins, and even reversed direction of blood flow (hepatofugal instead of hepatopetal) are not uncommon (Morandi et al. 2010). As the portal vein collects branches from the pancreas, circulatory abnormalities could be potentially responsible for the abnormal pancreatic structure. A very well recognized condition connected with significant reduction of the pancreatic islet size is diabetes mellitus (Noda

et al. 2010, Masjedi 2013, Erfani 2018). This condition is associated with hypoinsulinemia and hyperglycemia, whereas cPSS dogs are more likely to exhibit the opposite pattern of laboratory abnormalities (Collings et al. 2012). Reduced size of pancreatic islets has also been seen in several intoxications in experimental animals (Kikumoto et al. 2010, Yabe et al. 2019). Intoxication as a reason for smaller islets in cPSS dogs should be considered, as such patients show permanent hyperammonemia. Furthermore, in 5 of 43 dogs we found eosinophilic masses in pancreatic islets, and homogenous eosinophilic contents in islet cells have been seen in rats during gatifloxacin intoxication (Yabe et al. 2019). Furthermore, a connective tissue hyperplasia found in pancreatic islets of 4 cPSS dogs could result from the toxic effect, as some chronic intoxications have been shown to produce such lesions in other organs (Cui et al. 2011, Zhang et al. 2018).

Another sign indicating pancreatic involvement in cPSS pathogenesis are vacuoles in the cytoplasm of islet cells in most of our patients (Fig. 4a and 4b). No differences were found in their presence between males and females, or between crossbred and pedigree dogs. Neither was their presence linked to the age or body weight, but they were found in 37/43 (86%) dogs with cPSS and not in any control animals ( $p < 0.001$ ). Vacuoles in pancreatic cells are commonly found in diabetes mellitus (Masjedi et al. 2013, Erfani et al. 2018). The content of these vesicular lesions in dogs with cPSS is unknown, and further studies are needed to reveal this.

## Conclusion

The results indicate that cPSS severely affects the pancreas, as shown by significantly reduced area of the islets, the presence of eosinophilic masses in them, and/or intracellular vacuoles.

## References

- Baade S, Aupperle H, Grevel V, Schoon HA (2006) Histopathological and immunohistochemical investigations of hepatic lesions associated with congenital portosystemic shunt in dogs. *J Comp Pathol* 134: 80-90.
- Collings AJ, Gow AG, Marques A, Yool D, Furneaux R, Mellanby R, Watson PJ (2012) A prospective study of basal insulin concentrations in dogs with congenital portosystemic shunts. *J Small Anim Pract* 53: 228-233.
- Cui W, Cui H, Peng X, Fang J, Zuo Z, Liu X, Wu B (2011) Changes of relative weight and cell cycle, and lesions of bursa of Fabricius induced by dietary excess vanadium in broilers. *Biol Trace Elem Res* 143: 251-260.
- Frymus J, Trębacz P, Degórska B, Sterna J, Kowalczyk P, Tomkowicz A, Galanty M (2015) Portosystemic shunt in dogs and cats. Current diagnostic aspects. *Magazyn Wet* 24: 12-22
- Frymus J, Trębacz P, Sobczak-Filipiak M, Czopowicz M, Degórska B, Galanty M (2020) Histopathological picture of pancreatic islets in dogs with congenital portosystemic shunt. *Med Weter* 76: 103-106.
- Gow AG (2017) Hepatic encephalopathy. *Vet Clin North Am Small Anim Pract* 47: 585-599.
- Kikumoto Y, Sugiyama H, Inoue T, Morinaga H, Takiue K, Kitagawa M, Fukuoka N, Saeki M, Maeshima Y, Wang DH, Ogino K, Masuoka N, Makino H (2010) Sensitization to alloxan-induced diabetes and pancreatic cell apoptosis in acatalasemic mice. *Biochim Biophys Acta* 1802: 240-246.
- Kraun MB, Nelson LL, Hauptman JG, Nelson NC (2014) Analysis of the relationship of extrahepatic portosystemic shunt morphology with clinical variables in dogs: 53 cases (2009-2012). *J Am Vet Med Assoc* 245: 540-549.
- Majd N E, Tabandeh MR, Shahriari A, Soleimani Z (2018) Okra (*Abelmoschus esculentus*) improved islets structure, and down-regulated PPARs gene expression in pancreas of high-fat diet and streptozotocin-induced diabetic rats. *Cell J* 20: 31-40.
- Mankin KM (2015) Current concepts in congenital portosystemic shunts. *Vet Clin North Am Small Anim Pract* 45: 477-487.
- Masjedi F, Gol A, Dabiri S (2013) Preventive effect of garlic (*Allium sativum* L.) on serum biochemical factors and histopathology of pancreas and liver in streptozotocin-induced diabetic rats. *Iran J Pharm Res* 12: 325-338.
- Morandi F, Sura PA, Sharp D, Daniel GB (2010) Characterization of multiple acquired portosystemic shunts using transplenic portal scintigraphy. *Vet Radiol Ultrasound* 51: 466-471.
- Muranishi T, Takehana K, Hiratsuka T, Kobayashi A, Eerdunchaolu, Iwasa K, Abe M (1999) An investigation of the relationship between duct system and A cell-rich and PP cell-rich pancreatic islets in the canine pancreas. *J Vet Med Sci* 61: 737-742.
- Noda K, Melhorn ML, Zandi S, Frimmel S, Tayyari F, Hisatomi T, Almulki L, Pronczuk A, Hayes KC, Hafezi-Moghadam A (2010) An animal model of spontaneous metabolic syndrome: Nile grass rat. *FASEB J* 24: 2443-2453.
- Perazzo JC, Tallis S, Delfante A, Souto PA, Lemberg A, Eizayaga FX, Romay S (2012) Hepatic encephalopathy: an approach to its multiple pathophysiological features. *World J Hepathol* 4: 50-65.
- Przybylik-Mazurek E, Pach D, Hubalewska-Dydejczyk A, Sowa-Staszczak A, Gilis-Januszewska A, Kulig J, Matyja A, Chrapczyński P (2012) Symptoms and early diagnostic possibilities of pancreatic endocrine cells hyperplasia (nesidioblastosis). *Przegląd Lekarski* 69: 9-14.
- Raffel A, Krausch MM, Anlauf M, Wieben D, Braunstein S, Klöppel G, Röher HD, Knoefel WT (2007) Diffuse nesidioblastosis as a cause of hyperinsulinemic, hypoglycemia in adults: a diagnostic and therapeutic challenge. *Surgery* 141: 179-184.
- Sobczak-Filipiak M, Szarek J, Czopowicz M, Galanty M, Dolka I, Trębacz P, Frymus J, Lechowski R (2018a) Stellate cells in livers of dogs with portal vein hypoperfusion. *Med Weter* 74: 392-397
- Sobczak-Filipiak M, Męcik-Kronenberg T, Czopowicz M, Galanty M, Trębacz P, Frymus J, Badurek I, Szarek J (2018b) Lipogranulomas and pigment granulomas in livers of dogs with portosystemic shunt. *Pol J Vet Sci* 21: 265-272.
- Sobczak-Filipiak M, Szarek J, Badurek I, Padmanabhan J, Trębacz P, Januchta-Kurmin M, Galanty M (2019) Retrospective Liver Histomorphological Analysis in Dogs in Instances of Clinical Suspicion of Congenital Portosystemic Shunt. *J Vet Res*;63: 243-249.
- Tivers MS, Handel I, Gow AG, Lipscomb VJ, Jalan R, Mellanby RJ (2014) Hyperammonemia and systemic inflammatory response syndrome predicts presence of hepatic encephalopathy in dogs with congenital portosystemic shunts. *PLoS One* 9: e82303.
- Tobias KM, Rohrbach BW (2003) Association of breed with the diagnosis of congenital portosystemic shunts in dogs: 2,400 cases (1980-2002). *J Am Vet Med Assoc* 223: 1636-1639.
- Yabe K, Yamamoto Y, Suzuki T, Takada S, Mori K (2019) Functional and morphological characteristics of pancreatic islet lesions induced by quinolone antimicrobial agent gatifloxacin in rats. *Toxicol Pathol* 47: 35-43.
- Zhang B, Li SS, Men JL, Zhang ZH (2018) Effect of long-term cronaldehyde exposure on heart damage in male rats. *Zhonghua Lao Dong Wei Sheng Zhi Ye Bing Za Zhi* 36: 647-652