

FOLIA MEDICA CRACOVIENSIA

Vol. LXI, 4, 2021: 93–100

PL ISSN 0015-5616

DOI: 10.24425/fmc.2021.140007

Balanitis Xerotica Obliterans: an underestimated cause of secondary phimosis

IOANNA GKALONAKI¹, MICHALIS ANASTASAKIS¹, IOANNA SOFIA PSARRAKOU², IOANNIS PATOULIAS¹

¹First Department of Pediatric Surgery, Aristotle University of Thessaloniki Greece,
General Hospital “G.Gennimatas”, Thessaloniki, Greece

²Department of Pediatrics, General Hospital “G. Gennimatas”, Thessaloniki, Greece

Corresponding author: Ioanna Gkalonaki, M.D.

Papafi 178, Thessaloniki, Postal code 54453, Greece

Phone: +30 697 252 96 08; E-mail: iongalonaki@gmail.com

Abstract: Balanitis Xerotica Obliterans is a chronic, progressive, sclerosing inflammation of unclear etiology. It involves the external genitalia of males and more specifically the prepuce and its frenulum, the glans, and the external urethral meatus while it may extend to the peripheral part of the urethra. Recent studies have noted an increasing incidence in the paediatric population. It is the most common cause of secondary (pathologic) phimosis. Even more, in boys with physiologic phimosis that does not respond to conservative treatment, Balanitis Xerotica Obliterans should be considered as the underlying condition. In this study, we present all the latest data and attempt to create a diagnostic and curative algorithm regarding this condition.

Keywords: Balanitis Xerotica Obliterans, Lichen Sclerosus, meatitis, phimosis, circumcision.

Submitted: 10-Sep-2021; **Accepted in the final form:** 30-Nov-2021; **Published:** 28-Dec-2021.

Introduction

Balanitis Xerotica Obliterans (BXO) is a chronic, progressive, sclerosing inflammation of unclear etiology, that presents on the external genitalia of males and more specifically the prepuce and its frenulum, the glans, the external urethral meatus and the peripheral part of the urethra [1]. When neglected, it may affect the entire urethra, penile skin and scrotum [2, 3].

Early history

Balanitis Xerotica Obliterans was first described by Hallopeau [4] in 1887, with the synonymous term of Lichen Sclerosis of the glans penis and prepuce.

Based on the clinical features, Stuhmer described the international term of Balanitis Xerotica Obliterans, in 1928: Balanitis describes the chronic inflammation of the glans, Xerotica the whitish epithelium of the inflamed glans and Obliterans the co-existing endarteritis [5].

Caterall and Oates described for the first time this entity in the pediatric population, in a 7-year old child, in 1962 [6].

Epidemiology

The prevalence of BXO among all boys in the German population is estimated at 0.1–0.4% [7]. In a similar study taking place in the USA, the prevalence of BXO among boys younger than the age of 10 was estimated at 0.07% [8]. This differentiation is probably because many boys in the USA undergo circumcision earlier. In female the corresponding inflammatory lesions fall under the synonymous term Lichen Sclerosis (LS). The occurrence rate of LS in girls was estimated at 0.1–0.3%. This actually means that there is a similar prevalence between the two sexes.

It is worth mentioning that in recent studies there is an increasing occurrence rate on the pediatric population [9–13]. This may be due to the fact that more samples of resected prepuce are sent for histological examination, as well as the fact that young pediatric surgeons are familiar with the manifestations of BXO. When correlating the clinical findings of BXO with the corresponding histological findings, it is found that the diagnostic reliability of the clinical features is 53% (0–88%) [14–15]. That is to say, in about half of the cases, the possible diagnosis of BXO is not correctly made based on the clinical findings.

Etiology

BXO is a lymphocyte-mediated chronic inflammatory disease of the skin [7]. For its development the autoimmune reaction, the genetic predisposition and the chronic irritation of the area are to blame [16, 17]. An infectious cause, such as viruses, bacteria or spirochaetes has often been postulated, but never proved [7, 18]. Other possible causes include hormonal changes and genetic predisposition [19].

Pilatz, Altikilic *et al.*, in a study that concerned basically the histological examination of the resected prepuces in BXO, found an abundance of infiltrating, autoreactive cytotoxic T lymphocytes, impaired metabolism of the extracellular matrix (ECM) and the presence of autoantibodies to ECM protein in serum [11]. There is increasing

evidence for an underlying autoimmune mechanism. There have been multiple reports of association of BXO with autoimmune diseases including vitiligo, Hashimoto's thyroiditis, and type-1 diabetes [20].

The association of LS with HLA-DQ7 and the appearance of familial cases imply a genetic predisposition to LS in female patients [20, 21]. The literature contains evidence of a familial predisposition to BXO in boys [22].

On a molecular level, Pilatz, Altikilic *et al.* found a significant up-regulation of 11 genes associated with the generation of proinflammatory cytokines and proteins pivotal for tissue remodeling [11].

Clinical features

In the early stages of the disease there are rarely any symptoms. The most common symptoms are those of phimosis: the progressively worsening in the difficulty of retracting the prepuce in order to reveal the glans, and dysuria. Parents often describe a characteristic ballooning of the prepuce with voiding. Meffert *et al.* observed the Kobner effect, that is, the "triggering" of inflammation where the prepuce was previously injured, after its violent retraction [20].

If the clinical examination is done at an early stage, the examiner may find inflammation in the prepuce frenulum, erythema with serous fluid discharge from the prepuce or the glans, blistering and fissuring [1]. In 15–20% of cases, hypospadias may coexist [23–27]. In 20% of cases there are signs of primary physiologic phimosis, without the presence of mature scar. Later, signs of BXO may be seen, such as a circular whitish scar around the prepuce [7]. If the inspection of the glans is possible, the presence of thickened epithelialization on its outer surface as well as signs of meatitis may be detected. In 2.7% of the cases, narrowing of the urethral meatus can be seen at the same time as phimosis [7].

Diagnosis

It is important to emphasize that the diagnosis of BXO can be based on clinical features only in 53–76.2% of all cases [28, 29]. Therefore, in 23.8–47% of cases, pathognomonic manifestations of the disease are not revealed [29]. So, if clinical suspicion arises then the diagnosis must be substantiated by histological examination of the resected prepuce.

Typical lesions include hyperkeratosis and atrophy of the basal layer of the epidermis, loss of elastic fibers, changes in the composition and arrangement of collagen fibers, and finally inflammatory infiltration by lymphocytes [26, 30].

Treatment

Based on the most recent bibliographic references, circumcision is suggested as the treatment of choice. It is considered a radical solution as a low probability of phimosis recurrence is reported (0.05–0.1%) [7]. On the contrary, if partial circumcision or dorsal slit is performed without additional topical treatment with corticosteroids, then the probability of recurrence of the phimosis is 50% of the cases [7].

Wilkinson *et al.* performed more conservative interventions on the affected prepuce (prepuceplasty) in combination with a topical application of steroids, announcing the successful outcome in 81% of cases [10]. Ebert *et al.* completed the circumcision with local application of tacrolimus 0.1% in cases of complicated BXO, where the glans and urethral meatus were involved. They reported a regression of the disease in 91% of cases [13].

Alternatively, conservative treatment may be attempted with topical corticosteroid ointment or an immunosuppressive drug such as tacrolimus [31, 32]. Topical corticosteroid application may be combined with preoperative, intraoperative, and postoperative application. Topical application of corticosteroid ointment may limit the progression of the disease, but it cannot cure it [1]. In several studies of Vincent *et al.* and Kiss *et al.*, who applied topical corticosteroid ointment as the first-choice treatment, a reversal of the inflammatory lesions of BXO was observed [31, 32]. Vincent *et al.* performed a dorsal cleft — instead of circumcision — in cases where conservative treatment failed, with a successful outcome in 15/16 patients [32].

While treating BXO, the second intervention that may be required is the correction of the stenosis of the urethral meatus. If the urethral meatus has a normal appearance, examination should follow in three months, after the circumcision. If it has a normal appearance, and there is no difficulty in urination, no further examination is needed. If lesions are observed in the urethral meatus, then the child should be monitored for at least 2 years, in the beginning every three months, and later every six months, for the possibility of developing stenosis.

However, if stenosis is found during the operation, the circumcision must be combined either with dilatations of the urethral meatus, meatotomy or meatoplasty. After that, the monitoring plan mentioned above is followed. Topical application of corticosteroid ointment to the urethral meatus is not effective, because most of these patients (more than 62% of the total) will require interventions due to the transience of the result [33].

For the treatment of the postoperative stenosis, urethral dilatations, meatotomy or meatoplasty may be performed. These interventions are best done when the disease is in remission [34].

A comprehensive algorithm for the diagnostic and therapeutic management of patients with BXO is indicated in Table 1.

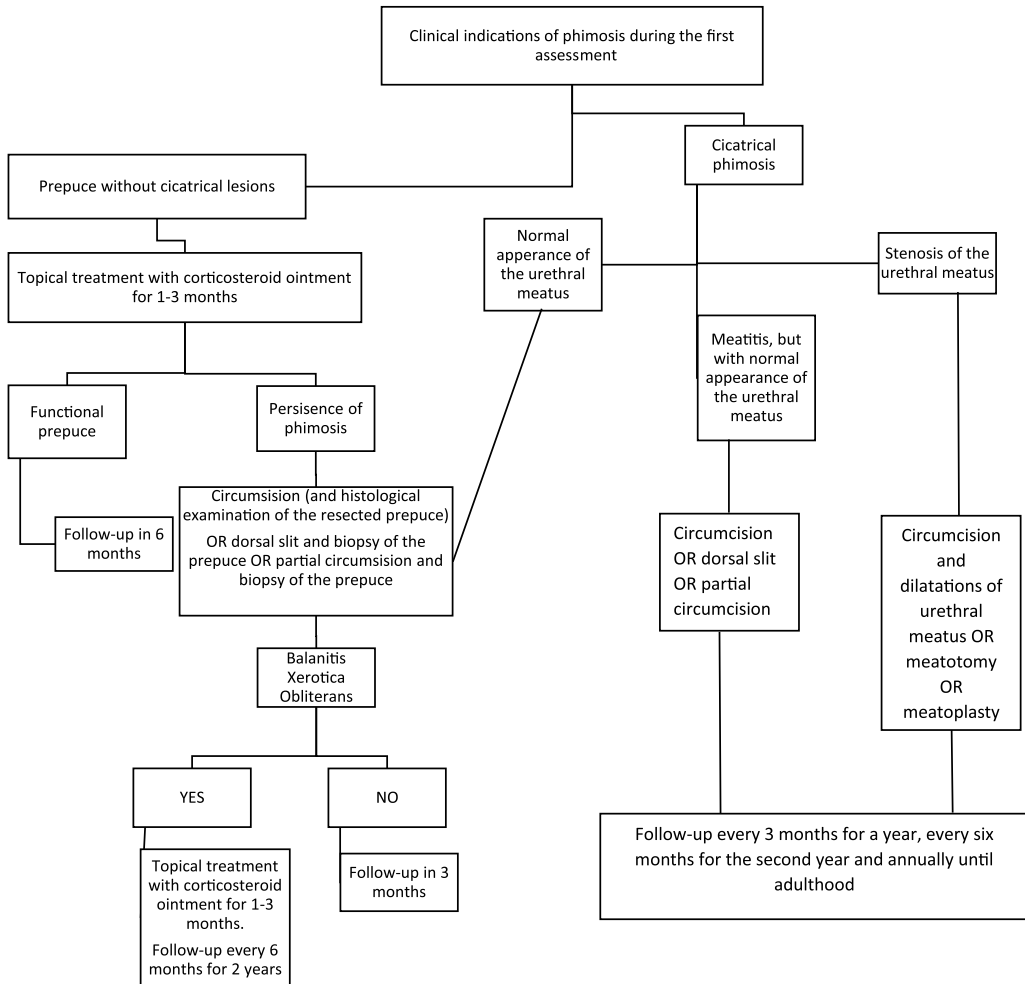


Table 1. Algorithmic strategy for the diagnosis and treatment of BXO.

Complications

The most important complication is inflammation of the urethral meatus and urethral stenosis [5, 19, 31]. The incidence of inflammation of the urethral meatus is reported in 4–47% of cases, while that of urethral stenosis reaches 20–60% [5, 35]. The development of obstructive uropathy, as is understandable, can progressively lead to chronic renal failure. It is important to mention the significance of both the early surgical treatment of BXO and the arrangement of a postoperative follow-up plan. As part of a long-term postoperative follow-up, topical treatment with corticosteroid

ointment periodically is required, as well as the early recognition of either recurrence of the BXO or stenosis of the peripheral part of the urethra.

The Ebert, Rosch *et al.* study evaluated the etiological correlation of the development of penile cancer in adults who suffered from BXO in childhood [13]. In adult studies, the etiological correlation — coexistence between BXO and squamous cell carcinoma of the penis — based on histological findings — corresponds to 2.8–28% of all cases [5, 36, 37]. Due to the fact that the human papillomavirus (HPV) is a causative agent of this malignancy, prophylactic vaccination of children with BXO against HPV is suggested. It is suggested that these children continue to be monitored by a urologist after they reach adulthood [38].

Lichen Sclerosus in Girls

The lichenoid changes begin on either the vulva or the anus and then become confluent to form a perineal figure eight. Symptoms can arise in the form of itching, local wound pain, and difficulty defecating due to anal fissures, leading to functional constipation [39]. The question of potential sexual abuse requires careful attention and should be included in the differential diagnosis. In this case, the Köbner phenomenon is not developed. When the diagnosis is in doubt, histopathological examination is helpful. There is little evidence that the condition improves spontaneously at puberty in a small number of cases [7]. The treatment of choice includes topical corticosteroid therapy for two to three months and is successful in over 90% of cases [40]. Alternative treatments include calcineurin antagonists or UVA phototherapy [39].

Overview

1. BXO is the number one cause of secondary phimosis in boys, that involves the glans and the urethral meatus. In boys with phimosis, who do not respond to the conservative treatment, BXO must be suspected.
2. Early diagnosis and management of BXO is the key to its regression in 92% of the cases. It is considered critical to perform circumcision within a year from the diagnosis of BXO, to prevent stenosis of the urethral meatus.
3. Histological examination of the resected prepuce is essential.

Conflict of interest

None declared.

References

1. Hartley A., Ramanathan C., Siddiqui H.: The surgical treatment of Balanitis Xerotica Obliterans. *Indian J Plast Surg.* 2011 Jan; 44 (1): 91–97.
2. Depasquale I., Park A.J., Bracka A.: The treatment of balanitis xerotica obliterans. *BJU International.* 2000; 86 (4): 459–465.
3. Singh I., Ansari M.S.: Extensive Balanitis Xerotica Obliterans (BXO) involving the anterior urethra and scrotum. *Int Urol Nephrol.* 2006; 38: 505–506.
4. Hallopeau H.: Leçons cliniques sur les maladies cutanées et syphilitiques. *Union Med Can.* 1887; 43: 472.
5. Depasquale I., Park A.J., Bracka A.: The treatment of Balanitis Xerotica obliterans. *BJU Int* 2000; 86: 459–465.
6. Catterall R.D., Oates J.K.: Treatment of Balanitis Xerotica obliterans with hydrocortisone injections. *Br J Vener Dis.* 1962; 38: 75–77.
7. Becker K.: Lichen Sclerosus in Boys. *Dtsch Arztebl Int.* 2011; 108 (4): 53–58.
8. Kizer W.S., Prarie T., Morey A.F.: Balanitis xerotica obliterans: Epidemiologic distribution in an equal access health care system. *South Med J.* 2003; 96: 9–11.
9. Jayakumar S., Antao B., Bevington O., Furness P., Ninan G.K.: Balanitis Xerotica obliterans in children and its incidence under the age of 5 years. *J Ped Urol* 2012; 8: 272–275.
10. Bochove-Overgaauw D., Gelders W., De Vylder A.: Rutine biopsies in pediatric circumcision (non sense)? *J Pediatr Urol.* 2009; 5: 178–180.
11. Pilatz A., Altinkilic B., Schormann E., et al.: Congenital phimosis in patients with and without lichen sclerosus: distinct expression patterns of tissue remodeling associated genes. *J Uro.* 2013; 189: 268e74.
12. Kizer W.S., Prarie T., Morey A.F.: Balanitis Xerotica Obliterans: epidemiologic distribution in an equal access health care system. *South Med J.* 2003; 96: 9e11.
13. Ebert A.K., Rösch W.H., Vogt T.: Safety and tolerability of adjuvant topical tacrolimus treatment in boys with lichen sclerosus: a prospective phase 2 study. *Eur Urol.* 2008; 54: 932e7.
14. Gargollo P., Kozakewich H., Bauer S., et al.: Balanitis Xerotica obliterans in boys. *J Urol* 2005; 174: 1409e12.
15. Kiss A., Csontai A., Pirot L., Nyirady P., Merksz M., Kiraly L.: The response of Balanitis Xerotica obliterans to local, steroid application compared with placebo in children. *J Urol* 2001; 165: 219e20.
16. Powell J., Wojnarowska F.: Lichen sclerosus. 1999; 353: 1777e89.
17. Peterson A.C., Palmineteri E., Lazzeri M., Guanzoni G., Barbagli G., Webster G.: Heroic measures may not always be justified in extensive urethral stricture due to lichen sclerosus (Balanitis Xerotica obliterans). *J Urol.* 2004; 64: 565–568.
18. Dillon W.I., Saeed G.M., Fivenson D.P.: *Borrelia burgdorferi* DNA is undetectable by polymerase chain reaction in skin lesions of morphea, scleroderma or lichen sclerosus et atrophicus inpatients of North America. *J Am Acad Dermatol.* 1995; 33: 617e20.
19. Pugliese J., Morey A., Peterson A.: Lichen sclerosus: review of the literature and current recommendations for management. *J Urol.* 2007; 178: 2268e76.
20. Meffert J.J., Davis B.M., Grimwood R.E.: Lichen sclerosus. *J Am Acad Dermatol.* 1995; 32: 393–416.
21. Powell J., Wojnarowska F.: Childhood vulvar lichen sclerosus: an increasingly common problem. *J Am Acad Dermatol.* 2001; 44: 803–806.
22. Depasquale I., Park A.J., Singh I., Ansari M.S.: Extensive Balanitis Xerotica Obliterans (BXO) involving the anterior urethra and scrotum. *Int Urol Nephrol.* 2006; 38: 505–506.
23. Yardiey I.E., Cosgrove C., Lambert A.W.: Pediatric preputial pathology: are we circumcising enough? *Ann R Coll Surg Engl.* 2007; 89: 62–65.
24. Edmonds E., Barton G., Buisson S., et al.: Gene expression profiling in male genital lichen sclerosus. *Int J ExpPathol.* 2011; 92: 320e5.
25. Bale P.M., Lochhead A., Martin H.C., Gollow I.: Balanitis xerotica obliterans in children. *Pediatr Pathol.* 1987; 7: 617–627.

26. *Mattioli G., Repetto P., Carlini C., Granata C., Gambini C., Jasonni V.*: Lichen sclerosus et atrophicus in children with phimosis and hypospadias. *Pediatr Surg Int.* 2002; 18: 273e5.
27. *Batbagli G., Palminteri E., Balo S., et al.*: Lichen sclerosus of the male genitalia and urethral stricture diseases. *Urol Int.* 2004; 73: 1–5.
28. *Celis S., Reed F., Murphy F., et al.*: Balanitis xerotica obliterans in children and adolescents: A literature review and clinical series. *J Pediatr Urol.* 2014; 10: 34–39.
29. *Kiss A., Király L., Kutasy B., Merksz M.*: High incidence of Balanitis Xerotica Obliterans in boys with phimosis: prospective 10-year study. *Ped Dermatol.* 2005; 22: 305–308.
30. *Bale P.M., Lochhead A., Martin H.C., et al.*: BXO in children *Pediatr Pathol.* 1987; 7: 617; 9.
31. *Mohammed A., Shegil I.S., Christou D., Khan A., Barua J.M.*: Paediatric Balanitis Xerotica obliterans: an 8-year experience. *Arch Ital Urol Androl.* 2012; 84: 12e6.
32. *Vincent M., MacKinnon E.*: The response of clinical Balanitis Xerotica Obliterans to the application of topical steroid-based creams. *J Pediatr Surg.* 2005; 40: 709e12.
33. *Holbrook C., Tsang T.*: Management of boys with abnormal appearance of meatus at circumcision for BXO. *Ann R Coll Surg Engl.* 2011; 93: 482–484.
34. *Barbagli G., Palminteri E., Baló S., et al.*: Lichen sclerosus of the male genitalia and urethral stricture diseases. *Urol Int.* 2004; 73: 1–5.
35. *Pugliese J., Morey A., Peterson A.*: Lichen sclerosus: review of the literature and current recommendations for management. *J Urol.* 2007; 178: 2268e76.
36. *Nasca M.R., Innocenzi D., Micali G.*: Penile cancer among patients with genital lichen sclerosus. *J Am Acad Dermatol.* 1999; 41: 911e4.
37. *Pietrzak P., Hadway P., Corbishley C., Watkin N.*: Is the association between Balanitis Xerotica Obliterans and penile carcinoma underestimated? *BJU Int.* 2006; 98: 74e6.
38. *Prowse D.M., Ktori E.N., Chandrasekaran D., et al.*: Human papillomavirus-associated increase in p16-INK4A expression in penile lichen sclerosus and squamous cell carcinoma. *Br J Dermatol.* 2008; 158: 261–265.
39. *Neill S.M., Tatnall F.M., Cox N.H.*: Guidelines for the management of lichen sclerosus. *Br J Dermatol.* 2002; 147: 640–649.
40. *Poindexter G., Morrell D.S.*: Anogenital pruritus: lichen sclerosus in children. *Pediatr Ann.* 2007; 36: 785–791.