

DOI 10.24425/pjvs.2023.148285

Original article

The effects of proanthocyanidin on testicular toxicity in rats exposed to a glyphosate-based herbicide

F. Avdatek¹, M. Kirikkulak¹, D. Yeni¹

¹ Department of Reproduction and Artificial Insemination, Faculty of Veterinary Medicine, University of Afyon Kocatepe, 03030, Afyonkarahisar, Turkey

Abstract

The purpose of this study is to determine the effects of proanthocyanidin (PA) on spermatological parameters and testicular toxicity in male rats exposed to glyphosate (GLP). In our study, four groups were formed out of 24 male rats, each group would include 6 rats. The rats in the PA group were given a dose of 400 mg/kg/day dissolved in DMSO via gastric gavage. The rats in the GLP+PA groups were first given GLP at the LD50/10 dose of 787.85 mg/kg/day, followed by administering PA at a dose of 400 mg/kg/day dissolved in DMSO via gastric gavage. The rats in the GLP group were given GLP at the LD50/10 dose of 787.85 mg/kg/day dissolved in DMSO via gastric gavage. It was determined that in terms of motility, in comparison to the control group, the decreases in the GLP group and the increases in the PA and GLP+PA groups were statistically significant ($p < 0.001$). The administration of GLP increased DNA damage compared to the control group, but the GLP+PA and PA applications reduced DNA damage ($p < 0.001$). The analysis of testosterone levels indicated a statistically significant reduction in the GLP group compared to the other groups. Consequently, it was determined that PA effectively prevented the decreases in the spermatological parameters lowered as a result of GLP exposure and the oxidative stress and toxicity in testicular tissue.

Keywords: glyphosate, proanthocyanidin, rat, spermatozoa, testicular toxicity

Introduction

Glyphosate (GLP)-based herbicides are among the first herbicides to be used in the world, and they are prevalently utilized as broad-spectrum herbicides to kill unwanted plants in lands that are used for agricultural and non-agricultural purposes (Avdatek et al. 2018). With the rapidly increasing prevalence of genetically modified crops, the amount of GLP usage is increasing worldwide (Cai et al. 2017). Due to the more frequent

usage of GLP, there are concerns about the ecosystem, water resources, animal health and, consequently, human health (Richmond 2018). Herbicides accumulate in animals through water and soil, and the consumption as food of animal products whose pesticide exposure doses have reached certain concentrations as food affects human health (Acquavella et al. 2004). Exposure to GLP can lead to endocrine disruption in both humans and rodents and can affect the reproductive systems of males. GLP can alter spermatozoon

properties, including spermatozoon production and even fetal development. It has been determined that GLP significantly alters cellular antioxidant status, and this leads to glutathione depletion, enzymatic disruptions, and increased lipid peroxidation in keratinocytes (Abarikwu et al. 2014, Cai et al. 2017). It was reported that changes in testicular cells affect spermatogenesis negatively (Ikpeme et al. 2012). Interactions between the genetic material in the testes of rats and GLP during spermatogenesis can lead to an increase in the rate of abnormal spermatozoa. Moreover, low spermatozoon numbers and motility were identified in rats exposed to GLP (Owagboriayea et al. 2017). It is likely for the disruption of reproductive functions by GLP to cause the depletion of the antioxidant defense system in the testes and epididymis of rats, which leads to the induction of oxidative stress (Ikpeme et al. 2012). Oxidative stress was proven to cause disruptions in spermatogenesis and sterility in males by reducing antioxidant concentrations in the blood and testes (Owagboriayea et al. 2017). GLP was reported to cause in vitro DNA and chromosomal damage in human and other animal cells and in vitro oxidative stress in rodents (Bolognesi et al. 2009).

Proanthocyanidins (PAs) are considered one of the most complex subclasses of flavonoids. They are found in fruits (grapes, dates, apples, peaches), vegetables (peas), nuts (hazelnuts, almonds), seeds (grape seeds), flowers (longan flowers), tree bark (pine bark), tuberous roots (onions), leaves (green tea), and various foods and drinks such as cocoa, tea, and wine (Fine 2000, Joshi et al. 2001, Iglesia et al. 2010, Choy and Waterhouse 2014). Previous studies have demonstrated that PAs which are found in grape seed extracts are better free radical scavengers and oxidative tissue injury inhibitors than vitamin C, vitamin E, combinations of vitamins C and E, β -carotene, gallic acid, and resveratrol (Fine 2000, Su et al. 2011, Zhao et al. 2014, Ou and Gu 2014, He et al. 2018). In addition to their free radical scavenging and antioxidant activities, they also show various biological activities such as antibacterial, antiviral, anti-inflammatory, antiallergic, anticarcinogenic, anti-diabetic, anti-neurodegenerative, anti-osteoarthritis, cardioprotective, hepatoprotective, and vasodilator effects. ROS-induced oxidative stress, which is one of the causes of infertility in males, leads to lipid peroxidation, DNA damage, and protein damage (Al-Daraji 2012). ROS, which consist of oxygen ions, free radicals, and peroxides, lead to infertility by directly damaging spermatozoon DNA or disrupting the plasma membrane integrity of spermatozoa. As a result of this, they cause reductions in motility and fertilization capacity in spermatozoa. Antioxidants that are found in the seminal plasma eliminate many negative issues

by displaying a strong defense against ROS (Soleimani and Masoumi 2017). Several studies have revealed that PAs have a potential protective effect against various male reproductive system disorders with their antioxidant properties (Attia et al. 2010, Bayatli et al. 2013, Abdel-Kawi et al. 2016, El-Beltagi et al. 2017, Long et al. 2017).

The purpose of this study is to determine the effects of PA on spermatological and oxidative stress parameters, potential DNA alterations, serum testosterone levels, and histological changes indicative of testicular toxicity in male rats exposed to GLP.

Materials and Methods

Chemicals

The glyphosate (Knockdown 48 SL) used in this study was obtained from the commercial firm HEKTAŞ (Kocaeli, Turkey), while proanthocyanidin (Grape Seed Extract, Technical, 250 mg) was purchased from the firm BIOSYNTH Carbosynth (Bratislava, Slovakia). Ketalar (10 ml vial, Ketamin HCl 50 mg/ml) was obtained from Pfizer (Turkey), and xylazine (25 ml vial, each ml of solution contains 20 mg xylazine base) was purchased from Bayer (Turkey).

Experimental animals and setup

This study was conducted with the approval of the Animal Experiments Local Ethics Committee of Afyon Kocatepe University dated 26.01.2021 and numbered 49533702/06. The animal material included 24 male 2.5-3-month-old Wistar Albino rats weighing 160-180 g. The rats were kept under standard conditions ($25\pm 2^\circ\text{C}$ constant temperature, 60-65% humidity, ventilated rooms, 12h-12h light-dark cycle) and in cages that were cleaned every day with ad libitum access to standard rat feed and water. The procedures were carried out between 13:00 and 14:00 every day. The experimental part of the study lasted for 56 days. The animals were divided into four groups so that each cage would include six animals. The rats in the control group ($n=6$) were given only standard rat feed and drinking water. The rats in the PA group ($n=6$) were given PA at a dose of 400 mg/kg/day dissolved in DMSO via gastric gavage. The rats in the GLP+PA group ($n=6$) were first given GLP at the $LD_{50/10}$ dose of 787.85 mg/kg/day, followed by administering PA at a dose of 400 mg/kg/day dissolved in DMSO via gastric gavage. The rats in the GLP group ($n=6$) were given GLP at the $LD_{50/10}$ dose of 787.85 mg/kg/day dissolved in DMSO via gastric gavage. On the last day of the study, the rats were fasted for 12 h and then anesthe-

Table 1. Weekly variations in live weight averages of rats.

Weeks	Control	PA	GLP+PA	GLP
1	176.1	196.4	207.1	184.2
2	201.7	209.5	217.3	193.8
3	221	220.5	231.5	211.2
4	237.5	240	246.3	228.1
5	243.1	251.2	254.8	238.1
6	251.1	260.1	261.8	248.5
7	257.5	267.2	268.1	256.2
8	263.2	272.1	274.1	262.5

PA – Proanthocyanidin, GLP+PA – Glyphosate+Proanthocyanidin.

tized with 10 mg/kg Xylazine HCl plus 50 mg/kg Ketamine HCl intramuscular. All rats were euthanized by exsanguination under anesthesia at the end of the experiment. For biochemical analyses, 24 hours after the last procedure at the experimental stage, after the animals were weighed, and their weights were recorded (Table 1), blood samples were collected from their hearts.

Epididymal spermatozoon assessments

The left cauda epididymis was compressed with forceps and cut lengthwise using a thin pair of scissors. In Petri dishes containing phosphate-buffered saline (PBS), the cauda epididymis was cut into small pieces, and sperm were collected. To determine motility, 10 microliters (μ l) of sperm+PBS was added on a slide that was put on a heating tray adjusted to 37°C, and a cover slide was added on the top. Motility values were determined in percentages by counting spermatozoa moving linearly towards any direction in three different zones under a phase-contrast microscope (Avdatek et al. 2018). The hypoosmotic eosin staining (HE) test was carried out to assess the rates of viable-dead spermatozoa and membrane integrity together. 1 ml of the 100 mOsm HOST solution kept in a water bath at 37°C and 1 μ l of the sperm sample were taken into a 10 μ l Eppendorf tube. After this, the eosin stain was added, and the mixture was left to incubate for 30 min in a 37°C water bath. Following incubation, a drop of the mixture was taken, smears were obtained, and they were dried rapidly. The prepared samples were evaluated under a microscope at 400x magnification using 400 spermatozoa in four ways, based on whether the entirety or part of the heads were stained and whether the tails were coiled (Avdatek et al. 2018).

Abnormal spermatozoon ratios in the sperm samples were analyzed using Giemsa staining. 400 spermatozoa were counted under a phase-contrast microscope structures that did not conform to the normal spermatozoon structure were accepted as abnormal, the head,

middle piece, tail, and total anomalies of the spermatozoa were separately evaluated, and the results were recorded as % (Watson 1975).

Preparation of testis tissue homogenate for antioxidant assays

In order to conduct antioxidant assays, preliminary treatment was performed on testis tissues. Initially, the tissues were fragmented using a mechanical homogenizer (IKA-T18 Ultra Turrax), and the resulting suspension underwent a secondary homogenization process using an ultrasonicator (Bandelin Sonopuls; 20 kHz power). Following this, the homogenate was centrifuged at 5000 rpm for 15 minutes using a centrifuge. The resulting supernatant was utilized for conducting antioxidant assays.

Malondialdehyde and reduced glutathione measurement in tissue homogenates

The method reported by Ohkawa, Ohishi and Yagi (1979) was utilized to determine the malondialdehyde (MDA) concentrations in the testicular tissue samples. The measurement of lipid peroxidation level in the study was conducted using malondialdehyde (MDA) as an indicator, following Draper and Hadley's double warming method. The MDA level was determined using the reaction between lipid peroxides and thiobarbituric acid. To perform this, 0.5 ml of the sample was thoroughly mixed with 2.5 ml of 10% (w/v) trichloroacetic acid and incubated in a water bath at 95°C for 15 minutes. Subsequently, the tubes were cooled to 4°C and centrifuged at 5000 rpm for 10 minutes. The resulting supernatant (2 ml) was mixed with 1 ml of 0.67% thiobarbituric acid. The mixture was subjected to another 15-minute incubation at 95°C, followed by cooling. In the MDA analysis, 1,1,3,3-tetramethoxypropane was utilized as the standard substance. The absorbance was then measured at 532 nm, and the concentration of MDA was calculated in nmol/g.

Moreover, to identify the reduced glutathione (GSH) concentrations in the samples, the method described by Beutler and Kelly (1963) was used. The amount of reduced glutathione (GSH) was determined using Ellman's method, and the concentration was calculated as mg/g, according to a previously described method. This method is primarily based on the catalytic reaction of Ellman reagent (DTNB) with GSH and GSSG. A mixture of 0.2 ml supernatant and 3 ml precipitant solution (containing 5 g metaphosphoric acid, 1 g EDTA, and 90 g NaCl solution in 300 ml distilled water) was prepared. The mixture was filtered through ordinary filter paper, and then 8 ml of phosphate buffer (0.3 M Na_2HPO_4) was added to 2 ml of the filtrate. To this mixture, 0.5 ml of DTNB solution (40 mg of DTNB in 1% sodium citrate solution) was added. The resulting mixture was vortexed, and the absorbance was measured at 412 nm. In the GSH analysis, reduced glutathione was utilized as the standard substance. In the spectrophotometric measurements, a Shimadzu 1601 UV-VIS spectrophotometer (Tokyo, Japan) was used.

Blood testosterone determination

Rat blood samples obtained through exsanguination were transferred into EDTA-containing tubes. Subsequently, the tubes were centrifuged (Nüve NF100) at +4 °C. The resulting plasma samples were transferred into Eppendorf tubes and stored at -20°C until the time of analysis. The plasma samples were allowed to reach room temperature. For the analyses, ELISA kits branded BT LAB Bioassay Technology Laboratory with catalog number E0259Ra from China were used. This kit is used based on the double-antibody sandwich enzyme immunoassay (EIA) method with biotin to investigate rat testosterone levels. All parameters were evaluated at a wavelength of 450 nm, and the results of the samples were obtained by placing the absorbance values obtained from the device on the calibration plot.

DNA damage assessments

The comet assay method was used to determine the DNA damage in the spermatozoa. The sperm samples collected freshly during euthanasia were washed two times in PBS (Ca- and Mg-free), approximately 15×10^6 (10 mL) spermatozoa were mixed with low-melting-point agarose (LMA) at 37°C, and they were smeared onto slides that were precoated with 1% normal-melting-point agarose (NMA). The slides were submerged in the Triton X-100 (1%) lysis solution (Trevigen Inc. Cat. No. 4250-010-01) in a vertical jar and kept at 4°C for 1 h. DL-Dithiothreitol (DTT)

(4 mM) (Sigma Aldrich Chemical Co.) was then added, and they were kept at 4°C for 1 h again. After this, 60 μL proteinase K (1 mg/mL) (Sigma Aldrich Chemical Co.) was added, and the slides were left to incubate at 37°C overnight to allow the DNA to dissolve. They were put into an electrophoresis container containing a previously prepared and cooled 300 mM NaOH and 1 mM Na-EDTA (pH 13) electrophoresis solution and kept there to acclimatize to the solution for 15 min. To attract the negatively charged DNA to the anode, an electric field (300 mA, 25 V) was applied at 25°C for 20 min. The slides were washed in a neutralizing buffer (0.4 M Tris, pH 7.5) three times for 5 min at 25°C, and they were then stained with 5 $\mu\text{g}/\text{mL}$ Ethidium Bromide (Sigma-Aldrich Chemical Co.). After staining, a cover slide was put onto each slide, and 100 DNA images under a fluorescent-added microscope (Olympus CX-31) were scored visually at 400x magnification. The DNA images were scored between 0 and 4 based on the degree of damage. The DNA images with no damage were given 0 points, while those that showed damage were scored from 1 point to 4 points in increasing order of damage severity. The results were recorded in arbitrary units (AU) (Avdatek et al. 2018).

Histological assessments

After the collection of testicular tissues from all rats and their fixation in Bouin solutions, the tissues were embedded in paraffin and sliced at thicknesses of 5 μm . Mayer hematoxylin and eosin (H&E) were used for staining. The tissues were examined using an optical microscope (Olympus Bx51 model) equipped with a camera (Olympus DP20) (Avdatek et al. 2018).

Statistical analysis

SPSS version 22.0 software was used to statistically analyze the data, and the Shapiro-Wilk W test was conducted to test the normality of the distribution of the data. The significance of the differences between groups was tested using one-way analysis of variance (ANOVA), and the sources of the significant differences were identified using post hoc Duncan's tests. The levels of statistical significance were accepted as $p < 0.05$ (*) and $p < 0.001$ (**).

Results

The spermatozoon motility values and abnormal spermatozoon ratios of the groups in this study are presented in Table 2. It was determined that in terms of motility, in comparison to the control group, the decreases in the GLP group and the increases in the

Table 2. Motility and abnormal spermatozoon rates in rat groups ($\bar{X} \pm \text{SEM}$, n:6).

Groups	Motility %	Head %	Mid-Piece %	Tail %	Total %
Control	70.00±1.82 ^c	7.66±0.33 ^b	16.83±0.98 ^b	41.50±1.11 ^a	66.00±2.12 ^b
PA	84.16±0.83 ^a	6.16±0.47 ^b	8.00±0.81 ^c	24.83±1.01 ^b	39.00±1.18 ^d
GLP+PA	78.33±1.05 ^b	8.16±0.70 ^b	11.66±1.30 ^c	29.16±1.47 ^b	49.00±2.16 ^c
GLP	62.50±1.11 ^d	13.66±1.76 ^a	20.83±1.92 ^a	43.83±3.04 ^a	78.33±4.22 ^a
p	**	**	**	**	**

a-d – Values (Mean ± SEM) with different superscripts (a and c) within the same column showed significant differences ** p<0,001. PA – Proanthocyanidin, GLP – Glyphosate, GLP+PA – Glyphosate+Proanthocyanidin

Table 3. HE-test parameters in rat groups ($\bar{X} \pm \text{SEM}$, n:6).

Groups	H+/E- %	H-/E- %	H+/E+ %	H-/E+ %
Control	26.83±1.70 ^a	37.50±2.17 ^{bc}	15.33±2.01 ^b	20.33±2.17 ^{ab}
PA	25.16±0.79 ^{ab}	48.50±2.07 ^a	10.33±1.08 ^c	16.00±0.57 ^b
GLP+PA	23.50±0.22 ^b	43.33±2.31 ^{ab}	14.83±0.87 ^{bc}	18.33±1.58 ^{ab}
GLP	19.50±0.80 ^c	35.33±1.99 ^c	21.16±1.83 ^a	24.00±2.43 ^a
p	**	**	**	*

a-c – Values (Mean ± SEM) with different superscripts (a and c) within the same column showed significant differences * p<0,05, ** p<0,001. PA – Proanthocyanidin, GLP – Glyphosate, GLP+PA – Glyphosate+Proanthocyanidin, H+/E-, tail swollen and head white; H-/E-, tail nonswollen and head white; H+/E+, tail swollen and head red; H-/E+, tail nonswollen and head red.

Table 4. Spermatozoa DNA damages in rat groups ($\bar{X} \pm \text{SEM}$, n:6).

Groups	DNA Hasarı (AU)
Control	59.66±3.85 ^b
PA	28.16±2.52 ^d
GLP+PA	49.50±3.50 ^c
GLP	87.16±2.62 ^a
p	**

a-d – Values (Mean ± SEM) with different superscripts (a and c) within the same column showed significant differences ** p<0,001. PA – Proanthocyanidin, GLP – Glyphosate, GLP+PA – Glyphosate+Proanthocyanidin

PA and GLP+PA groups were statistically significant (p<0.001). The increase in head anomalies in the GLP group compared to the control and other groups, the decreases in middle piece, tail, and total anomalies in the PA and GLP+PA groups compared to the control group, and the increase in the GLP group compared to the control group in these anomalies were found to be statistically significant (p<0.001). The HE test results are presented in Table 3. In comparison to the control group, the decreases in the H+/E- ratios of the GLP+PA and GLP groups and the increase in the H-/E- ratios of the PA group were significant (p<0.001). Additionally, the decrease in the PA group and the increase in the GLP group in terms of H+/E+ in comparison to the control group were significant (p<0.001). The DNA damage results are given in Table 4. Accordingly, it was found that GLP administration increased

DNA damage, while administering PA alone (PA group) and administering PA after the administration of GLP (GLP+PA group) reduced DNA damage by a statistically significant proportion (p<0.001). As seen in Table 5, the statistical analysis of testosterone indicated a statistically significant reduction in the GLP group compared to the other groups. The results on the oxidative stress parameters are presented in Table 6. While there was no significant difference among the groups in terms of MDA, the GSH levels in the GLP and GLP+PA groups were significantly lower in comparison to those in the PA group (p<0.05). The seminiferous tubule diameters and germinative cell layer thicknesses of the groups are shown in Table 7. In terms of seminiferous tubule diameters, the reductions in the GLP and GLP+PA groups in comparison to the control group were found to be statistically significant (p<0.001).

Table 5. Blood testosterone levels in rat groups ($\bar{X} \pm \text{SEM}$, n:6).

Groups	Testosterone (ng/L)
Control	444.02 \pm 36.78 ^a
PA	394.85 \pm 60.33 ^{ab}
GLP+PA	449.86 \pm 12.45 ^a
GLP	290.28 \pm 11.99 ^b
p	*

a-b – Values (Mean \pm SEM) with different superscripts (a and c) within the same column showed significant differences * $p < 0,05$. PA – Proanthocyanidin, GLP – Glyphosate, GLP+PA – Glyphosate+Proanthocyanidin

Table 6. Testis tissue oxidative stress parameters in rat groups ($\bar{X} \pm \text{SEM}$, n:6).

Gruplar	MDA (nmol/g)	GSH (mg/g)
Control	14.47 \pm 0.28 ^a	16.41 \pm 0.43 ^{ab}
PA	14.10 \pm 0.43 ^a	16.98 \pm 0.28 ^a
GLP+PA	14.18 \pm 0.26 ^a	15.64 \pm 0.30 ^b
GLP	15.05 \pm 0.73 ^a	15.51 \pm 0.24 ^b
p	-	*

a-b – Values (Mean \pm SEM) with different superscripts (a and c) within the same column showed significant differences * $p < 0,05$. PA – Proanthocyanidin, GLP – Glyphosate, GLP+PA – Glyphosate+Proanthocyanidin, MDA – Malondialdehyde, GSH – Glutathione

Table 7. Mean (\pm SEM) diameter of ST and GCLT in rat testis.

Groups	Diameter of ST (μm)	GCLT (μm)
Control	102.49 \pm 0.35 ^a	42.95 \pm 1.53 ^a
PA	103.05 \pm 0.28 ^a	39.42 \pm 0.86 ^{ab}
GLP+PA	99.04 \pm 0.47 ^b	35.11 \pm 1.13 ^c
GLP	94.77 \pm 1.17 ^c	36.56 \pm 1.57 ^{bc}
p	**	*

Values (Mean \pm S.E.M.) with different superscripts (a-b) within the same column showed significant differences * $p < 0,05$, ** $p < 0,001$. PA – Proanthocyanidin, GLP – Glyphosate, GLP+PA – Glyphosate+Proanthocyanidin, ST – Seminiferous tubules, GCLT – Germinal cell layer thickness

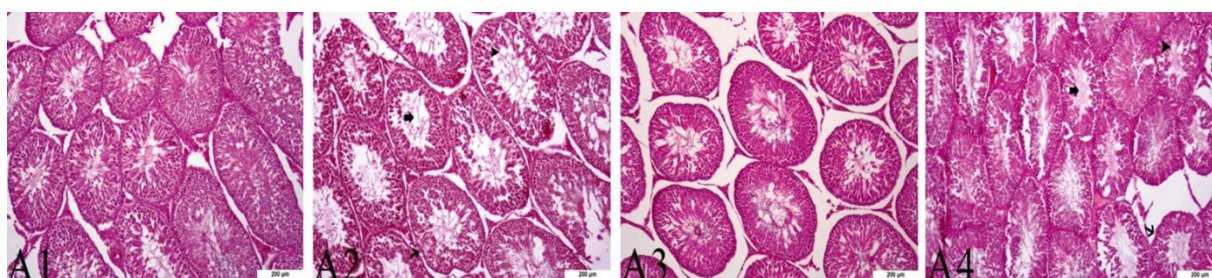


Fig. 1. Effect of proanthocyanidin on glyphosate-induced damage in the testes of rats. The presented picture was stained with hematoxylin eosin. The control group (A1), PA applied group (A2), GLP+PA applied group (A3), GLP applied group (A4) are shown.

The reductions in the GLP and GLP+PA groups in comparison to the control group in terms of germinative cell layer thicknesses were also significant ($p < 0.05$) (Fig. 1).

Discussion

Administering GLP to rats leads to a reduction in the antioxidant capacity of sperm, the formation of ROS and, consequently, oxidative stress. This has negative effects on spermatological parameters, spermatozoon DNA, testicular tissue histopathology and, thus, fertility. Therefore, considering that it could have favorable effects on spermatological parameters and

testicular toxicity, we used a strong antioxidant substance, PA, in our study.

The GLP that was administered to rats at a dose of 787.85 mg/kg/day via gastric lavage for 56 days in our study led to a significant decrease in the motility rates, which are one of the most significant indicators of sperm quality, in comparison to the control and other groups, while it also led to significant increases in important spermatological parameters such as the head, middle piece, tail, and total abnormal spermatozoon ratios. Moreover, in the HE tests in which we investigated membrane integrity and viable-dead spermatozoon ratios together, we observed that GLP had effects including the reduction of membrane integrity and the elevation of dead spermatozoon ratios. These results were compatible with the findings of several researchers who investigated the same parameters in different animal species. In the study where they administered GLP (5 mg/kg) to 6-week-old male rats three times a week for 52 days via gavage, Abarikwu et al. (2017) reported reductions in spermatozoon motility and numbers, as well as an increase in the rate of dead spermatozoa in the GLP group compared to the control group. Yousef et al. (1995) stated that the chronic exposure of male rabbits to GLP resulted in a reduction in spermatozoon numbers and an increase in the rates of abnormal or dead spermatozoa. In their study, which involved administering 375 mg/kg GLP daily to rats, Avdatek et al. (2018) reported lower spermatozoon motility and membrane integrity values and higher rates of abnormal spermatozoa in the GLP group in comparison to the control and other groups. Cai et al. (2017) showed that, in both mice and rats, GLP led to reductions in spermatozoon numbers and motility values, and this consequently had negative effects on fertility.

In our study, 400 mg/kg/day PA, which was administered as a protective substance after administering GLP as a toxic substance, had many positive effects including increasing spermatozoon motility, reducing abnormal and dead spermatozoon ratios, and increasing membrane integrity. Long et al. (2017) demonstrated that administering PA beforehand improved the spermatozoon numbers and motility that were reduced by Zearalenone (ZEN), while significantly preventing an increase in the ratio of abnormal spermatozoa. It has been reported that PA improved the spermatozoon numbers, motility, and abnormal and viable/dead spermatozoon ratios of rats that were exposed to Cadmium (Cd) toxicity (Sönmez and Tascioglu 2016, He et al. 2018, Bashir 2019). PA administration was shown to significantly reduce high spermatogonial chromosomal abnormalities and spermatozoon head anomalies induced by doxorubicin (Attia et al. 2010).

Cells may be highly sensitive to chemical substances. As a result of this sensitivity, damage in cells, especially single strand breaks in DNA, can be observed (Kumaravel and Jha 2006). Exposure to high-dose GLP has been shown to cause DNA damage in different species including rats, *Drosophila*, ruminants, eels, and humans (Çavaş and Könen 2007, Bolognesi et al. 2009, Poletta et al. 2009). In our study, it was observed that GLP led to higher rates of DNA damage compared to the control and other groups, but administering PA as a protective substance at a dose of 400 mg/kg/day significantly reduced DNA damage. Lopes et al. (2014) reported that GLP damaged spermatozoon DNA in the zebrafish *Danio rerio*, and it could have detrimental effects on reproductive system parameters by reducing the integrity and functionality of the mitochondrial membrane. In a study in which they administered 375 mg/kg/day GLP to rats, Avdatek et al. (2018) found that DNA integrity was significantly damaged. Bashir (2019) reported that exposure to Cd led to high rates of DNA damage in the spermatozoa of rats, but administering PA had a protective effect by stopping free radicals formed by Cd before they reached the DNA. Consequently, they determined that, with its strong antioxidant properties, PA was protective against Cd-induced oxidative testicular toxicity. Hajizadeh et al. (2016) suggested that the oxidative stress induced by exposure to Fluoxetine (FLX) in rats was suppressed by PA administration and, as a result of this, DNA damage decreased. Our results were similar to those reported in previous studies, and administering PA was effective in the protection of spermatozoa by reducing DNA damage.

Exposure to environmental sources of toxicity, including pesticides, affects fertilization negatively and can create severe outcomes extending up to sterility. Pesticide accumulation in the testes and other reproductive organs triggers oxidative stress that leads to the accelerated death of spermatozoa. Oxidative stress creates significant harm to the normal functions and DNA of spermatozoa by causing the induction of peroxidative damage in the plasma membrane. Owagboriayea et al. (2017) reported a decrease in GSH and an increase in MDA in rat testes exposed to GLP, and this resulted in oxidative stress. Avdatek et al. (2018) observed an increase in MDA levels and a decrease in GSH activity in rats in the group to which GLP was administered in comparison to the other groups. Nithya and Elango (2015) showed that oxidative stress disrupted spermatogenesis in rats by reducing the levels of antioxidants in the blood and testes, and this led to sterility. Abarikwu et al. (2014), on the other hand, stated that MDA and GSH levels in the testes of rats were not significantly affected

by GLP administration. Zhao et al. (2014) found that Cisplatin administration led to a significant decrease in GSH levels in rats and an increase in MDA levels, whereas by the administration of PA, Cisplatin-induced lipid peroxidation and oxidative stress were significantly reduced. Oxidative stress is one of the main pathogenic mechanisms in varicoceles. It leads to morphological and functional damage in the testes and epididymis. Varicocele was observed to significantly raise MDA levels in testicular tissue and significantly lower GSH levels. Nevertheless, these parameters were significantly improved as a result of administering PA (Wang et al. 2018). In other studies, a high-fat diet and exposure to Cd led to significant increases in MDA levels and significant decreases in GSH levels. However, PA application improved the testicular oxidative stress induced by the high-fat diet and Cd exposure. These results revealed the ROS-scavenging effects of PA (He et al. 2018, Wang et al. 2019). Rodríguez-Pérez et al. (2019) reported that PA administration against arsenic toxicity in rats significantly reduced MDA levels and increased GSH levels, and as a result of this, arsenic-induced oxidative damage was blocked. In our study, there was no significant difference among the groups in terms of MDA levels in the testicular tissue samples. In terms of GSH, on the other hand, the reduction in the GLP group in comparison to the other groups was significant. Furthermore, we found that administering PA led to an increase in GSH levels. While our results were different from the results of some studies, they were similar to those reported in others.

In our study, the statistical analysis of testosterone levels indicated a statistically significant reduction in the GLP group compared to the other groups. Romano et al. (2010) argued that the exposure of young rats to GLP reduces blood testosterone levels, and this may delay their age of reaching puberty. In another study, dose-dependent reductions in the serum levels of testosterone, progesterone, and estradiol were reported in the group that was exposed to GLP in comparison to the control and other groups (Dai et al. 2016). In the studies conducted by Wang et al. (2019) and Hajizadeh et al. (2016), PA treatment had a protective role against abnormal testosterone levels and testicular androgenic disorders induced by a high-fat diet and exposure to FLX. Therefore, it is thought that GLP might have a significant effect on testosterone production in rats.

In the testes of rats, GLP causes degenerative changes such as reduced epithelium height and tubular diameter and increased lumen diameters (Romano et al. 2010). Degenerative changes that are observed in the seminiferous tubules and interstitial cells of rat testes are evidence of the toxic effects of GLP on the repro-

ductive system of male rats (Owagboriayea et al. 2017). Avdatek et al. (2018) found a reduction in the seminiferous tubule diameters and germinative epithelial layer thicknesses of rats that were subjected to GLP in comparison to other groups. Ikpeme et al. (2012) reported that GLP exposure in mice was harmful to their reproductive physiology including the cellular integrity of gonads. After exposing rats to cisplatin, Zhao et al. (2014) determined significant reductions in the seminal tubule diameters and germinative epithelial layer thicknesses in testicular tissue, as well as degeneration, necrosis, and interstitial edema in the testes. They revealed that, with PA treatment, the cisplatin-induced testicular injury was almost entirely cured, and there were noticeable improvements in the examined parameters. Thus, they reported that PA had a protective effect against cisplatin-induced testicular toxicity. In our study, the seminiferous tubule diameter and germinative cell layer thickness values in the GLP+PA and GLP groups were found to be significantly lower in comparison to those in the control group. Although the results of our study were in agreement with those reported in some previous studies, other studies have shown different results. The reasons for these differences may include differences in the individuals who made these assessments, the administration routes and durations of substances used in the studies, and the tools, equipment, and methods that were used in the assessment of parameters.

Consequently, PA, a strong antioxidant, had favorable effects against the reduced motility and plasma membrane integrity and the increased abnormal spermatozoon ratio and DNA damage induced by GLP exposure in rats. Moreover, PA was determined to effectively prevent negative histological alterations in the testicular tissues of the rats. Based on these positive effects, it was concluded that PA had a protective effect against GLP-induced testicular toxicity.

Acknowledgements

This research was supported by Afyon Kocatepe University Scientific Research Projects Coordination Unit (BAPK). Project No: 21.SAG.BIL.01. All authors declare that they have no conflicts of interest.

References

- Abarikwu SO, Akiri OF, Durojaiye MA, Adenike A (2015) Combined effects of repeated administration of Bretmont Wipeout (glyphosate) and Ultrazin (atrazine) on testosterone, oxidative stress and sperm quality of Wistar rats. *Toxicol Mech Methods* 25: 70-80.

- Abdel-Kawi SH, Hashem KS, Abd-Allah S (2016) Mechanism of diethylhexylphthalate (DEHP) induced testicular damage and of grape seed extract-induced protection in the rat. *Food Chem Toxicol* 90: 64-75.
- Acquavella JF, Alexander BH, Mandel JS, Gustin C, Baker B, Chapman P, Bleeke M (2004) Glyphosate biomonitoring for farmers and their families: results from the Farm Family Exposure Study. *Environ Health Perspect* 112: 321-326.
- Al-Daraji HJ (2012) The use of certain grape constituents for improve semen quality and storage ability of diluted Roosters' semen. *Am J Pharm Tech Res* 2: 308-322.
- Attia SM, Al-Bakheet SA, Al-Rasheed NM (2010) Proanthocyanidins produce significant attenuation of doxorubicin-induced mutagenicity via suppression of oxidative stress. *Oxid Med Cell Longev* 3: 404-413.
- Avdatek F, Birdane YO, Türkmen R, Demirel HH (2018) Ameliorative effect of resveratrol on testicular oxidative stress, spermatological parameters and DNA damage in glyphosate-based herbicide-exposed rats. *Andrologia* 50: e13036.
- Bashir N, Shagirtha K, Manoharan V, Miltonprabu S (2019) The molecular and biochemical insight view of grape seed proanthocyanidins in ameliorating cadmium-induced testes-toxicity in rat model: implication of PI3K/Akt/Nrf-2 signaling. *Biosci Rep* 39: BSR20180515.
- Bayatli F, Akkuş D, Kilic E, Saraymen R, Sönmez MF (2013) The protective effects of grape seed extract on MDA, AOPP, apoptosis and eNOS expression in testicular torsion: an experimental study. *World J Urol* 31: 615-622.
- Beutler E, Kelly BM (1963) The effect of sodium nitrite on red cell GSH. *Experientia* 19: 96-97.
- Bolognesi C, Carrasquilla G, Volpi S, Solomon KR, Marshall EJ (2009) Biomonitoring of genotoxic risk in agricultural workers from five colombian regions: association to occupational exposure to glyphosate. *J Toxicol Environ Health A* 72: 986-997.
- Cai W, Ji Y, Song X, Guo H, Han L, Zhang F, Liu X, Zhang H, Zhu B, Xu M (2017) Effects of glyphosate exposure on sperm concentration in rodents: A systematic review and meta-analysis. *Environ Toxicol Pharmacol* 55: 148-155.
- Cavas T, Könen S (2007) Detection of cytogenetic and DNA damage in peripheral erythrocytes of goldfish (*Carassius auratus*) exposed to a glyphosate formulation using the micronucleus test and the comet assay. *Mutagenesis* 22: 263-268.
- Choy YY, Waterhouse AL (2014) Proanthocyanidin metabolism, a mini review. *Nutr Aging* 2: 111-116.
- Dai P, Hu P, Tang J, Li Y, Li C (2016) Effect of glyphosate on reproductive organs in male rat. *Acta Histochem* 118: 519-526.
- de La Iglesia R, Milagro FI, Campión J, Boqué N, Martínez JA (2010) Healthy properties of proanthocyanidins. *Biofactors* 36: 159-168.
- El-Beltagi EM, Elwan WM, El-Bakry NA, Salah EF (2017) Histological and immunohistochemical study on the effect of gibberellic acid on the seminiferous tubules of testis of adult albino rat and the possible protective role of grape seeds proanthocyanidin extract. *Tanta Med J* 45: 79.
- Fine AM (2000) Oligomeric proanthocyanidin complexes: history, structure, and phytopharmaceutical applications. *Altern Med Rev* 5: 144-151.
- Hajizadeh Z, Mehranjani MS, Najafi G, Shariatzadeh SM, Jalali AS (2016) Black grape seed extract modulates fluoxetine-induced oxidative stress and cytotoxicity in the mouse testis. *Jundishapur J Nat Pharm Prod* 11: e27512.
- He L, Li P, Yu LH, Li L, Zhang Y, Guo Y, Long M, He JB, Yang SH (2018) Protective effects of proanthocyanidins against cadmium-induced testicular injury through the modification of Nrf2-Keap1 signal path in rats. *Environ Toxicol Pharmacol* 57: 1-8.
- Ikpeme EV, Udensi O, Ekaluo UB, Solomon TO (2012) Efficacy of ascorbic acid in reducing glyphosate-induced toxicity in rats. *Br Biotechnol J* 2: 157-168.
- Joshi SS, Kuszynski CA, Bagchi D (2001) The cellular and molecular basis of health benefits of grape seed proanthocyanidin extract. *Curr Pharm Biotechnol* 2: 187-200.
- Kumaravel TS, Jha AN (2006) Reliable Comet assay measurements for detecting DNA damage induced by ionising radiation and chemicals. *Mutat Res* 605: 7-16.
- Long M, Yang S, Zhang Y, Li P, Han J, Dong S, Chen X, He J (2017) Proanthocyanidin protects against acute zearalenone-induced testicular oxidative damage in male mice. *Environ Sci Pollut Res Int* 24: 938-946.
- Lopes FM, Varela Junior AS, Corcini CD, da Silva AC, Guazzelli VG, Tavares G, da Rosa CE (2014) Effect of glyphosate on the sperm quality of zebrafish *Danio rerio*. *Aquat Toxicol* 155: 322-326.
- Nithya R, Elango V (2015) Pesticide effect in male hormones and antioxidant status in male albino rats. *J Acad Indus Res* 4: 140-143.
- Ohkawa H, Ohishi N, Yagi K (1979) Assay for lipid peroxides in animal tissues by thiobarbituric acid reaction. *Anal Biochem* 95: 351-358.
- Ou K, Gu L (2014) Absorption and metabolism of proanthocyanidins. *J Funct Food* 7: 43-53.
- Owagboriaye FO, Dedeke GA, Ademolu KO, Olujimi OO, Ashidi JS, Adeyinka AA (2017) Reproductive toxicity of Roundup herbicide exposure in male albino rat. *Exp Toxicol Pathol* 69: 461-468.
- Poletta GL, Larriera A, Kleinsorge E, Mudry MD (2009) Genotoxicity of the herbicide formulation Roundup (glyphosate) in broad-snouted caiman (*Caiman latirostris*) evidenced by the Comet assay and the Micronucleus test. *Mutat Res* 672: 95-102.
- Richmond ME (2018) Glyphosate: a review of its global use, environmental impact, and potential health effects on humans and other species. *J Environ Stud Sci* 8: 416-434.
- Rodríguez-Pérez C, García-Villanova B, Guerra-Hernández E, Verardo V (2019) Grape seeds proanthocyanidins: an overview of in vivo bioactivity in animal models. *Nutrients* 11: 2435
- Romano RM, Romano MA, Bernardi MM, Furtado PV, Oliveira CA (2010) Prepubertal exposure to commercial formulation of the herbicide glyphosate alters testosterone levels and testicular morphology. *Arch Toxicol* 84: 309-317.
- Soleimani M, Masoumi N (2017) The effect of grape seed extract on semen oxidative stress markers in men with idiopathic infertility: a cross-sectional before-after study. *Nephro-Urol Mont* 9: e13837.
- Sönmez MF, Tascioglu S (2016) Protective effects of grape seed extract on cadmium-induced testicular damage, apoptosis, and endothelial nitric oxide synthases expression in rats. *Toxicol Ind Health* 32: 1486-1494.
- Su L, Deng Y, Zhang Y, Li C, Zhang R, Sun Y, Zhang K, Li J,

- Yao S (2011) Protective effects of grape seed procyanidin extract against nickel sulfate-induced apoptosis and oxidative stress in rat testes. *Toxicol Mech Methods* 21: 487-494.
- Wang EH, Yu ZL, Bu YJ, Xu PW, Xi JY, Liang HY (2019) Grape seed proanthocyanidin extract alleviates high-fat diet induced testicular toxicity in rats. *RSC Adv* 9: 11842-11850.
- Watson PF (1975) Use of a Giemsa stain to detect changes in acrosomes of frozen ram spermatozoa. *Vet Rec* 97: 12-15.
- Yousef MI, Salem MH, Ibrahim HZ, Helmi S, Seehy MA, Bertheussen K (1995) Toxic effects of carbofuran and glyphosate on semen characteristics in rabbits. *J Environ Sci Health B* 30: 513-534.
- Zhao YM, Gao LP, Zhang HL, Guo JX, Guo PP (2014) Grape seed proanthocyanidin extract prevents DDP-induced testicular toxicity in rats. *Food Funct* 5: 605-611.