

# Effect of dressing with different antiseptic agents on reproductive parameters in rats undergoing abdominal incision

G.D. Akarsu<sup>1,2</sup>, E. Erbaş<sup>3</sup>, S.A. Akarsu<sup>4</sup>

<sup>1</sup> Division of Molecular Medicine, Laboratory for Advanced Genomics, Institut Ruđer Bošković, Zagreb, Croatia

<sup>2</sup> Department of Pharmacy Services, Vocational School of Health Services, Yozgat Bozok University, Atatürk Road 7.Km, Bilal Şahin West Campus 66100, Yozgat, Turkey

<sup>3</sup> Department of Histology and Embryology, Faculty of Veterinary Medicine, Ataturk University, Yakutiye 25030, Erzurum, Turkey

<sup>4</sup> Department of Reproduction and Artificial Insemination, Faculty of Veterinary Medicine, Yakutiye 25030, Ataturk University, Erzurum, Turkey

Correspondence to: S.A. Akarsu, e-mail: serkanaliakarsu@gmail.com

## Abstract

Antiseptic agents used in the postoperative period affect the functions of many tissues in the body, including the testicles. In this study, the effect of dressings administered with different antiseptic agents on testicular functions in rats that underwent abdominal incisions was investigated. A total of 48 Sprague-Dawley rats were used in the study. Each of the rats in the study group underwent a 4 cm-long skin and muscle operation. The incision was then stitched immediately. Antiseptics, hemp seed oil, hemp leaf oil, and cannabidiol oil were then administered to the rats for 10 days to provide antiseptics. The rats were sacrificed 24 hours after the last administration, and testicular tissues were removed. Testicular tissues were used for histopathological examination and biochemical analysis, while epididymal tissue was used for sperm analysis. According to the results, the MDA level in the antiseptic-administered group was higher than in the other experimental groups ( $p < 0.05$ ). Levels of SOD, CAT activities, and GSH content were found to be lower in the antiseptic group than in the hemp seed oil, hemp leaf oil, and cannabidiol oil groups ( $p < 0.05$ ). In testicular histology, the SEED group had the highest Johnsen score, and the antiseptic group had the lowest score ( $p < 0.05$ ). While JAK, P-JAK2, STAT3, PSTAT3, and NF- $\kappa$ B were generally higher in the antiseptic group compared to the other groups, they were lower in the SEED group. Additionally, sperm total motility rate and epididymal sperm density were highest in the SEED group ( $p < 0.05$ ). As a result, it was determined that cannabidiol seed oil had a good effect on testicular histology and sperm quality in male rats during the wound healing process.

**Keywords:** antiseptic, hemp, oxidative stress, testis, wound healing



## Introduction

Sperm viability and motility are necessary for fertility (Donkin and Barrès 2018, Ömür 2022). Sperm viability and motility are affected by many environmental factors such as surgery and the postoperative period. The reasons for this situation include the immune system's focus on healing the wound and protecting against infections. A study indicates that sperm quality and sperm viability decreased after surgery in azoospermia or fertile obese patients (Carette et al. 2019). In addition, surgical operations increase oxidative stress and therefore force antioxidant mechanisms to rapidly activate. This oxidative damage continues during the maturation process of the wound (Karlidag et al. 2006).

Antiseptic solutions are agents that help accelerate wound healing by destroying possible antigens that may damage the wound. However, while these antiseptic solutions directly contact wound tissue, they can contact other tissues and body fluids and mix with blood and extracellular fluids. The Wolff-Chaikoff effect, a response to povidone-iodine in infants, is a good example of this (Heymann 2000). Therefore, continuing research is crucial to creating new and updated antiseptic solutions (Murphy and Evans 2012, Daeschlein 2013, Bodnar 2014).

Hemp is a plant with antiseptic properties that grows almost everywhere in the world and has been one of the research topics in recent years. Although it has psychotropic effects, its seeds are used in oil production and its fibers are used in the furniture and textile industry (Farinon et al. 2020). The oil obtained from hemp seeds contains a variety of different molecules, minerals and vitamins (Matthäus and Brühl 2008). Similarly, oils obtained from the fibrous parts of hemp are reported to have various compounds (Menghini et al. 2021). Studies indicate that cannabidiol, a hemp-derived compound that does not have psychotropic effects, can be used in the wound healing process (Wietecha and DiPietro 2013, Carvalho et al. 2022).

In the present study, the effects of cannabis products on oxidative stress, testicular histopathology and sperm quality in rats subjected to abdominal incision were investigated.

## Materials and Methods

### Ethics committee approval and supply of experimental animals

Ethical approval was received from Erciyes University Animal Experiments Local Ethics Committee (Protocol no; 2023/242). Forty-eight male Sprague-Dawley rats, weighing between 250-300 g and aged

10-12 weeks, were used in the study. The animals were housed in standard conditions at 24°C, 45% humidity, and a 12h light and dark cycle. In all animal administrations, the guidelines set forth by the EU for the care of experimental animals were complied with. The rats that acclimated to the novel environment were arbitrarily separated into four groups (n=48). The rats were then sedated with the administration of ketamine (Ketalar, Eczacıbaşı, Turkey). A 4 cm long skin and muscle incision was made sequentially on the anesthetized rats. The muscle and skin were then sutured with simple separate stitches.

The antiseptic group were dressed with 10% antiseptic solution (Dermosept, ALG drug, Turkey) for 10 days. The CBD group were dressed with Cannabidiol (CBD) – ethanol (w15%) for 10 days. The HEMP group were dressed with cannabis leaf essential oil- DMSO (w15%) for 10 days. The SEED group were dressed with cannabis seed oil for 10 days.

After the last dressing, the rats were sacrificed under 10 mg/kg xylazine (Basilazin, Bavet, Turkey) + 50 mg/kg ketamine (Ketalar, Eczacıbaşı, Turkey) anesthesia. Testicular tissues of rats were removed, separated from connective tissues, and weighed. Right testicular tissues were placed in formaldehyde solution for histological analysis, and the remaining testicular tissues were kept in a deep freezer until analysis.

### Determination of lipid peroxidation in testicular tissue

Analysis of malondialdehyde (MDA) level as an indicator of lipid peroxidation (LPO) in testicular tissue was determined using the method described by Placer et al. (1966). Testicular tissues were diluted 1:15 with 1.15% KCl, then homogenized and centrifuged at 1000 g at +4°C for 15 minutes. Analyses were made from the obtained supernatant.

### Determination of antioxidant status in testicular tissue

The powdered tissues were diluted 1:15 with 1.15% KCl and then homogenized in a homogenizer. Homogenates were then centrifuged for superoxide dismutase (SOD), catalase (CAT) and glutathion peroxidase (GPx) measurements. Supernatants were used for analysis. Glutathion (GSH) level analysis in testicular tissue was determined using the method described by Sedlak and Lindsay (1968). GPx activities were determined using Matkovic's method (1988). CAT activities were measured using the method determined by Aebi (1984). SOD activities were measured using the method described by Sun et al. (1988).

### Histopathological and immunohistochemical analysis

Testicular tissues of sacrificed rats were placed in 10% neutral formaldehyde solution and fixed for 72 hours. They were then passed through graded alcohol and xylol series, embedded in paraffin blocks, and 5 $\mu$  thick serial sections were taken with a microtome (Leica RM2125 RTS) for histopathological evaluations. The obtained sections were stained using Crossman's Modified Mallory's Triple Staining method for histopathological examinations, and tissue damage assessments were made.

Testicular histological damage and spermatogenesis were assessed under a light microscope using Johnsen's mean testicular biopsy score (Johnsen 1970). 30 tubules for each testis were graded according to the presence or absence of germ cell types such as spermatozoa, spermatids, spermatocyte, spermatogonia, germ cells and Sertoli cells in the testicular seminiferous tubules, and a score of 1 to 10 was given for each tubule. According to this scoring system; 10 points indicate complete spermatogenesis with many spermatozoa, the germinal epithelium is of regular thickness and the lumen is open. 9 points indicate that there are numerous spermatozoa but they appear disorganized with marked shedding or obliteration of the germinal epithelial lumen. 8 points indicate that there are only a few sperm in the section. 7 points indicate that there are no spermatozoa but many spermatids. 6 points indicate that there are no spermatozoa but a few spermatids. 5 points indicate no spermatozoa and no spermatids, but there are a few or many spermatocytes. 4 points indicate only a few spermatocytes and no spermatids or spermatozoa. 3 points indicate the only germ cells present are spermatogonia. 2 points indicate no germ cells but Sertoli cells. 1 point indicates no cells in the tubular section. Histopathological evaluations were made according to these criteria.

The obtained testicular tissues were taken from paraffin blocks in 5  $\mu$ m thick sections and placed on positively charged slides, and the sections were then passed through xylol and alcohol series and washed with PBS in 3% H<sub>2</sub>O<sub>2</sub> for 10 minutes for endogenous peroxidase inactivation. They were treated with citrate solution (pH:6.0) for 4x5 minutes at 600 watts to reveal the antigen in the tissues. Anti janus kinase2 (Anti-JAK2) (Elabscience, E-AB-22272, 1/150 dilution), anti-P-JAK2 (Affinity, AF3024, 1/150 dilution), Anti signal transducer and activator of transcription 3 (anti-STAT3) (Elabscience, E-AB-32981, dilution 1/150), anti-P-STAT3 (BT LAB, BT-PHS00280, 1/150 dilution), Anti nuclear factor kappa B (anti-NF- $\kappa$ B p65) (Santa Cruz, sc-109, 1/100 dilution) and anti-Bcl Tissues incubated with

-2 (Abcam, Ab-7973, 1/100 dilution) primary antibodies overnight at +4°C were then treated with secondary antibody. Secondary antibody (Large Volume Detection System: anti-Polyvalent) and HRP (Thermo fischer, TP-125-HL) was used as recommended by the manufacturer. DAB (Thermo fischer, 3,3'-Diaminobenzidine) was used as a chromogen. After counterstaining with Mayer Hematoxylin, they were coated with entellan and examined under a light microscope. Evaluation was made by the histopathologist at 20X objective magnification.

### Stereological immune reactivity analysis

In order to determine whether the immunohistochemical staining was specific or not, a negative control was applied to all sections and all procedures were performed under the same conditions using PBS instead of primary antibody. For immunohistochemical examinations, tissue slides were evaluated under a light microscope (Olympus Bx53) and photographs were then taken. Semiquantitative analyses for all groups investigated the degree of immunoreactivity at the cellular level. Numerical density values for immune reactive cells of testicular tissue were obtained from a modified light microscope (Leica DM4000B; Leica Instruments) and stereology software (Microbrightfield Stereo- Investigator software v. 9.0; Microbrightfield, Williston, VT, USA), as described in previous work (Kalkan et al. 2012).

### Reproductive parameters analysis

The caudal part of the epididymis was trimmed in 5 mL of saline in a petri dish at 35°C to obtain semen fluid. A light microscope (Zeiss, Germany) fitted with a heating plate was used for total motility analysis. 20  $\mu$ L of semen sample was placed on a slide and covered with a coverslip. Total motility score was calculated by examining 3 different microscope fields (Gur et al. 2023). For epididymal sperm density, 5  $\mu$ L of semen sample was taken in an eppendorf tube and mixed with 995  $\mu$ L of eosin dye (5%). 10  $\mu$ L of the sample was then taken by vortexing and transferred to a Thoma slide. After the fluid movement stopped, a count was made and the semen density was calculated. For the percentage of dead-viable sperm and abnormal spermatozoa ratio, 10  $\mu$ L of sperm fluid was placed on a slide and 20  $\mu$ L of eosin-nigrosin mixture (1.67% eosin, 10% nigrosin and 0.1 M sodium citrate) was placed on it. It was then mixed on the slide, smeared and dried. The percentage of dead sperm and abnormal spermatozoa was calculated by counting 200 spermatozoa from each sample (Aksu et al. 2016).

Table 1. Testicular tissue oxidative stress results in rats.

	Antiseptic	CBD	HEMP	SEED
MDA (nmol/g tissue)	41.01±2.19 <sup>c</sup>	39.67±1.63 <sup>bc</sup>	34.83±3.76 <sup>ab</sup>	32.30±4.80 <sup>a</sup>
SOD (u/g protein)	13.67±3.61 <sup>a</sup>	14.51±2.88 <sup>a</sup>	20.50±3.51 <sup>b</sup>	22.33±2.88 <sup>b</sup>
CAT (catal/g protein)	17.16±4.70 <sup>a</sup>	16.83±2.64 <sup>a</sup>	21.33±1.63 <sup>ab</sup>	22.83±3.18 <sup>b</sup>
GPx (u/g protein)	20.51±4.76	18.01±2.28	22.17±2.14	22.01±2.36
GSH (nmol/g tissue)	2.33±0.41 <sup>a</sup>	2.35±0.85 <sup>a</sup>	2.83±0.20 <sup>b</sup>	2.81±0.23 <sup>b</sup>

Different superscript letters indicate the difference between groups (a, b, c;  $p < 0.05$ ).

Table 2. Stereological analysis of immune reactivity of anti-JAK2, anti-P-JAK2, anti-STAT3, anti-P-STAT3, anti- NF- $\kappa$  B, anti-Bcl-2 antibodies, and Johnsen's score in the testis tissue of rats for all groups.

Groups	JAK2	P-JAK2	STAT3	P-STAT3	NF- $\kappa$ B p65	Bcl-2	Johnsen's score
Antiseptic	0.063±0.014 <sup>a</sup>	0.065±0.006 <sup>a</sup>	0.057±0.008 <sup>a</sup>	0.071±0.003 <sup>a</sup>	0.055±0.009 <sup>a</sup>	0.022±0.005 <sup>a</sup>	3.83±0.75 <sup>a</sup>
CBD	0.044±0.012 <sup>b</sup>	0.050±0.008 <sup>a</sup>	0.063±0.010 <sup>a</sup>	0.065±0.009 <sup>a</sup>	0.060±0.007 <sup>a</sup>	0.028±0.009 <sup>a</sup>	4.5±0.83 <sup>b</sup>
HEMP	0.026±0.013 <sup>c</sup>	0.018±0.003 <sup>b</sup>	0.012±0.005 <sup>b</sup>	0.035±0.008 <sup>b</sup>	0.022±0.011 <sup>b</sup>	0.061±0.006 <sup>b</sup>	7.83±0.75 <sup>c</sup>
SEED	0.022±0.011 <sup>c</sup>	0.011±0.003 <sup>b</sup>	0.011±0.003 <sup>b</sup>	0.040±0.007 <sup>b</sup>	0.018±0.003 <sup>b</sup>	0.063±0.010 <sup>b</sup>	9.5±0.54 <sup>c</sup>

Different superscript letter (a, b, c) indicates the statistical differences between the groups, p value accepted as  $< 0.05$ .

## Results

### Oxidative stress parameters results

Results for oxidative stress parameters are shown in Table 1. The MDA content was found to be higher in the antiseptic group compared to the other experimental groups, while it had the lowest value in the SEED group ( $p < 0.05$ ). While the SOD and CAT activity levels had the lowest values in the antiseptic and CBD groups, they had higher values in the HEMP and SEED groups ( $p < 0.05$ ). There was no statistically significant difference between the groups in terms of GPx activity. While the GSH level was the lowest in the antiseptic and CBD groups, it was highest in the HEMP and SEED groups ( $p < 0.05$ ).

### Histopathological examination results

In the present study, it was found that the seminiferous tubules in the antiseptic and CBD groups lost their normal structure, and the integrity of the testis was completely disturbed. The germ cells in the seminiferous tubules were shown to be totally shed in some tubules while appearing uneven and incomplete in other groups. The lumen is totally destroyed in some seminiferous tubules. It was easy to see that the seminiferous tubules and germ cells were deteriorating. The integrity of the seminiferous tubules was confirmed in the HEMP and SEED groups, the germ cells were organized regularly, and the tubule lumens were in a normal configura-

tion. As a result of the histopathological evaluations, it was observed that the score was 4 according to the JS score in the antiseptic group (Fig. 1A-B) and 5 in the CBD group (Fig. 1C-D). According to this scoring system, while the score was 8 in the HEMP group (Fig. 1E-F), it was determined as 10 in the SEED group (Table 2, Fig. 1G-H).

According to the data obtained as a result of immunohistochemical staining, while JAK2, P-JAK2, STAT3, P-STAT3 and NF- $\kappa$ B p65 immune reactions were found to be high in the antiseptic and CBD groups, these values were found to be significantly lower in the HEMP and SEED groups when compared to other groups ( $p < 0.05$ ). Bcl-2 immune reactivity was found to be significantly higher in the HEMP and SEED groups compared to other groups ( $p < 0.05$ ). Statistical data of all immune reactivity results are presented in Table 2 and immunoreactivity results are presented in Fig. 2.

### Reproductive parameters results

Testicular weights and sperm quality parameters of the experimental groups are presented in Table 3. These data indicate that total motility was highest in the HEMP and SEED groups and lowest in the antiseptic group ( $p < 0.05$ ). Regarding the percentage of dead, abnormal spermatozoa, and total weight of the testicles, there were no statistical differences between the groups. While the epididymal sperm density was

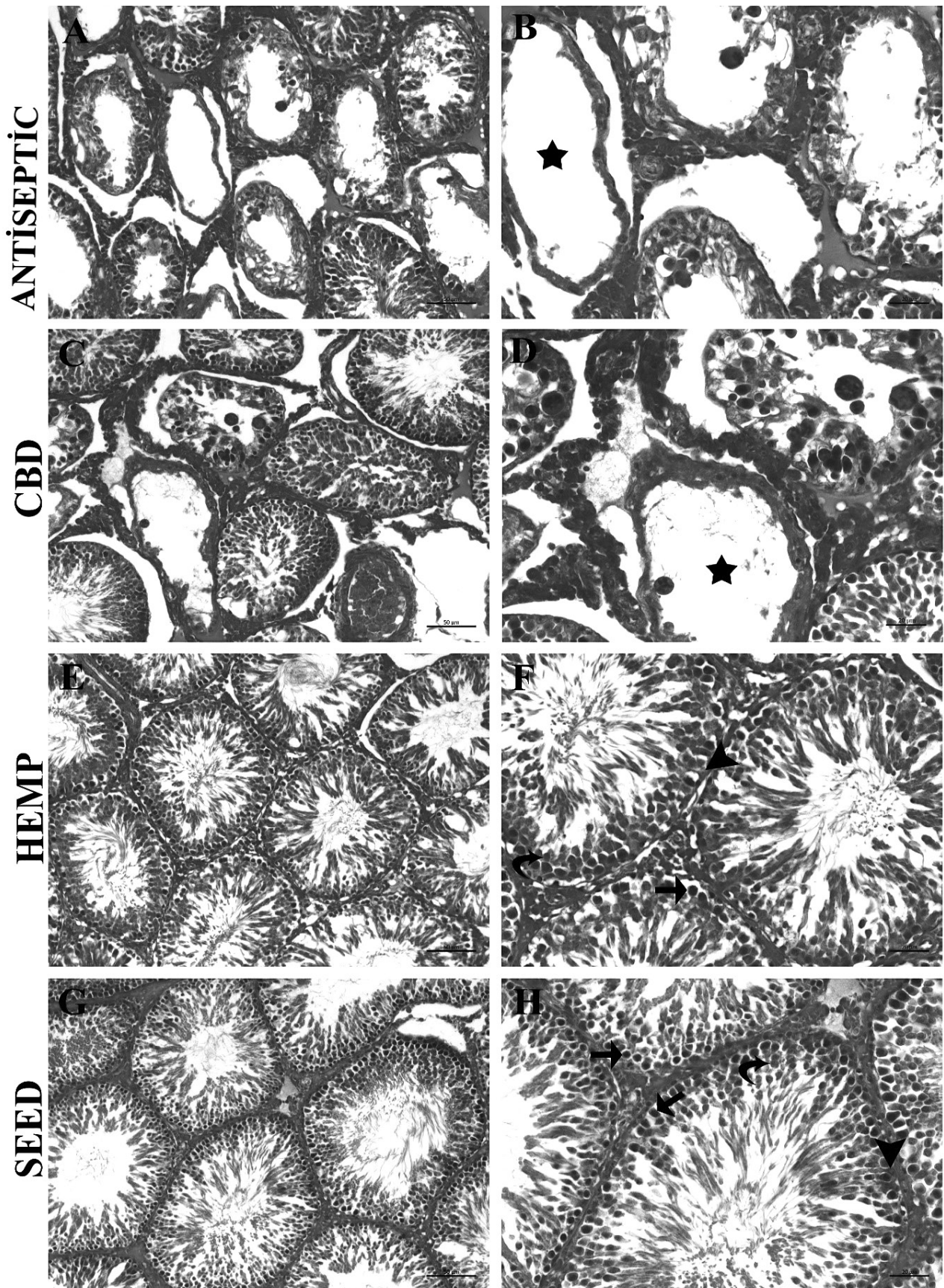


Fig. 1. Testicular seminiferous tubules stained with Crossman's Modified Mallory's Triple Staining. Star: Degeneration of seminiferous tubules, Arrow: Spermatogoniums, Curved arrow: Spermatocytes, Arrowhead: Sertoli cells. Magnification: A, C, E, G x200; B, D, F, H x400.

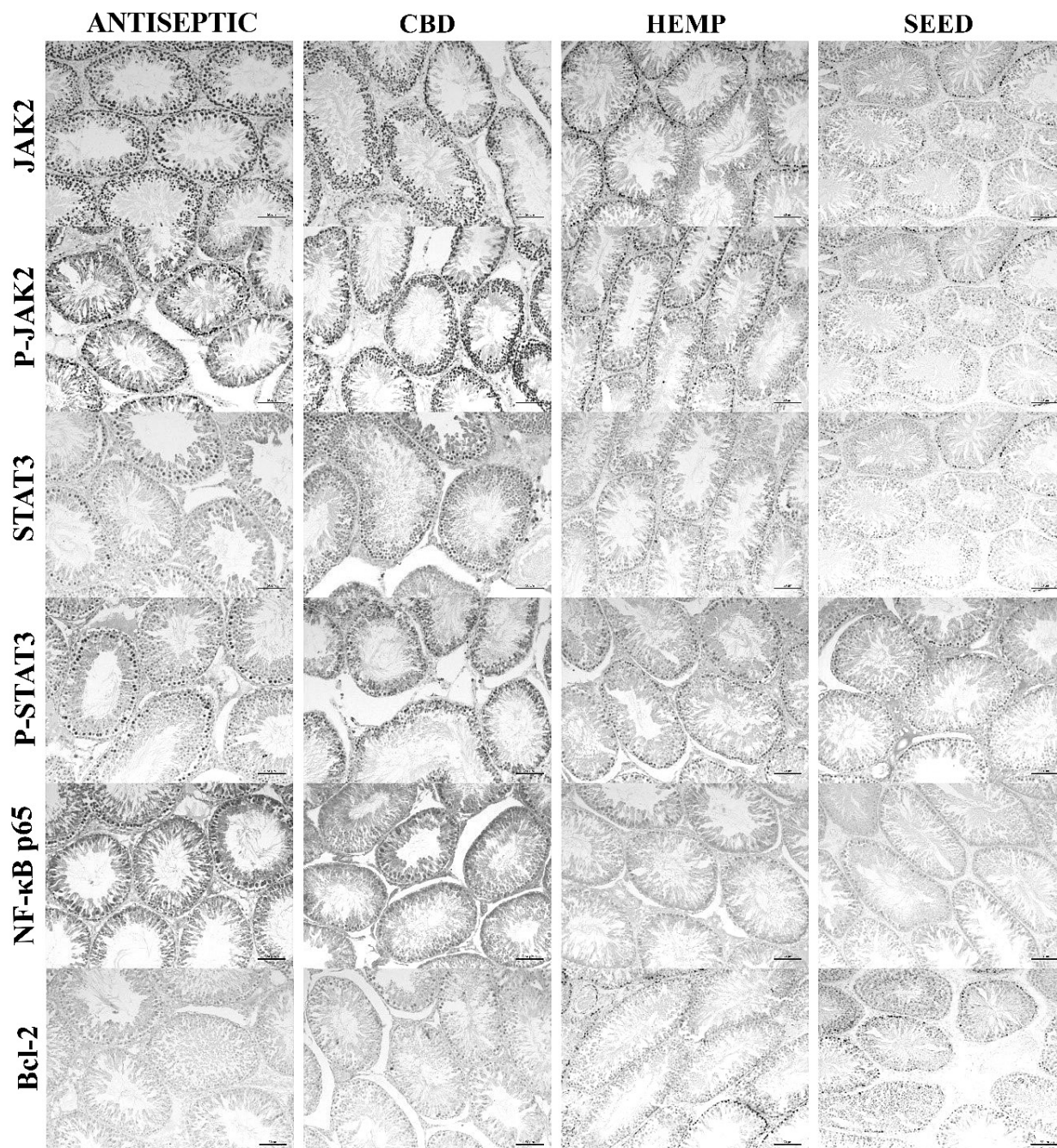


Fig. 2. Representation of testicular seminiferous tubules stained with antibodies to JAK2, P-JAK2, STAT3, P-STAT3, NF- $\kappa$ B p65, Bcl-2 by immunohistochemical methods; Streptavidin- Biotin (LSAB) staining, magnification x200.

Table 3. Results of total testicular weight and epididymal sperm parameters in rats.

	Total motility (%)	Dead-live spermatozoa rate (%)	Abnormal spermatozoa rate (%)	Density ( $\times 10^6$ )	Total Testis Weight (mg)
Antiseptic	63.32 $\pm$ 6.67 <sup>a</sup>	10.67 $\pm$ 0.81	9.01 $\pm$ 1.26	14.33 $\pm$ 2.33 <sup>a</sup>	2404.01 $\pm$ 183.99
CBD	66.63 $\pm$ 5.98 <sup>ab</sup>	10.01 $\pm$ 1.09	8.51 $\pm$ 0.54	14.01 $\pm$ 1.67 <sup>a</sup>	2484.83 $\pm$ 124.64
HEMP	74.41 $\pm$ 4.02 <sup>b</sup>	8.83 $\pm$ 1.47	8.17 $\pm$ 1.60	15.66 $\pm$ 1.03 <sup>ab</sup>	2399.84 $\pm$ 87.24
SEED	73.86 $\pm$ 3.89 <sup>b</sup>	8.51 $\pm$ 2.42	8.01 $\pm$ 1.26	17.16 $\pm$ 0.75 <sup>b</sup>	2550.33 $\pm$ 140.09

Different superscript letters (a, b, c;  $p < 0.05$ ) in the same line are statistically significant.

highest in the SEED group, a statistically significant difference was observed between the CBD and antiseptic groups ( $p < 0.05$ ).

## Discussion

Semen quality is affected by various environmental factors such as surgical operations. In the present study, the effects of different antiseptic agents on testicular histopathology, oxidative stress and sperm quality in rats subjected to abdominal incision were investigated.

Oxidative stress is one of the parameters affecting sperm quality in testicles. The increase in MDA, which is an indicator of lipid peroxidation, affects spermatogenesis in the testicles and causes a decrease in sperm quality (Aksu et al. 2021). It has been reported in studies that oxidative damage occurs in experimental operations applied to the testicles (Aktaş et al. 2010, Koksall et al. 2012). Cannabis sativa L. contains amino acids, fatty acids, and steroids, as well as secondary metabolites such as flavonoids, stilbenoids, terpenoids, alkaloids, lignans, and others (Graczyk et al. 2021). It is also reported that cannabis products have antioxidant properties (Fouda et al. 2020). While antiseptic products delay wound healing (Thomas et al. 2009), cannabis products accelerate this process (Chelliah et al. 2018, Atalay et al. 2019, Zheng et al. 2022). It is reported that dysregulated endocannabinoids system (ECS) signaling occurs in wound conditions and cannabis products regulates this condition (Maccarrone et al. 2015). In our study, the fact that the CBD groups generally had lower testicular tissue MDA content compared to the antiseptic group can also be explained by the ECS regulation. The significant decrease in MDA content, especially in the SEED group, can be explained by the higher antioxidant properties of cannabidiol seeds and the regulation of the ECS system.

Inflammation, sperm DNA damage, induction of apoptosis and spermatogenesis disorder occur in testis damage (Hassan et al. 2019). The binding of IL-6 to Janus kinase (JAK)/signaling pathways and activators of the transcription3 (STAT3) receptor family induces the transcription of a variety of inflammatory and apoptotic genes, including NF- $\kappa$ B (Shafiey et al. 2023). Previous studies suggest that povidone-iodine use may affect the inflammatory response (Islamov et al. 2020). In the present study, it is seen that JAK, STAT3, and NF- $\kappa$ B immune activity is lowest in the SEED group and high in the antiseptic group ( $p < 0,05$ ). This is interpreted as CBD and its products reducing inflammation. Anti-apoptotic B-cell lymphoma-2 (Bcl-2) regulates apoptosis. The Bcl-2 ratio was found to be higher in CBD groups compared to the antiseptic group.

A significant increase in Bcl-2 levels was observed in the SEED and HEMP groups ( $p < 0.05$ ). This is thought to be the reason why CBD products have anti-apoptotic properties and therefore preserve the composition of the testis.

Male reproductive function is essential for successful fertilization (Aksu et al. 2019). It is indicated that there may be a decrease in sperm quality after abdominal surgery (Peeters et al. 2014). While antiseptic solutions used after the operation protect the tissues against pathogens, they also cause various complications (Çoban et al. 2018). When we examine the study groups, it is seen that the sperm quality has decreased in general. This may be due to the operation performed. However, sperm quality was found to be lower in the antiseptic group compared to the other groups ( $p < 0.05$ ). This may be due to the fact that CBD derivatives reduce inflammation and oxidative damage in tissues, and consequently inhibit apoptosis.

## Conclusion

Testicular histopathology, oxidative damage, and sperm quality were examined in this study to determine the effects of various antiseptic agents used after abdominal incision. Groups using CBD, HEM, and SEED oil reduced testicular inflammation and oxidative damage while also improving sperm quality, compared to the group using antiseptics.

## References

- Aebi H (1984) Catalase in vitro. *Methods Enzymol* 105: 121-126.
- Akarsu SA, Acısu TC, Güngör İH, Cihangiroğlu AÇ, Koca RH, Türk G, Sönmez M, Gür S, Fırat F, Duruel HE (2023) The effect of luteolin on spermatological parameters, apoptosis, oxidative stress rate in freezing rabbit semen. *Pol J Vet Sci* 26: 91-98.
- Aksu EH, Kandemir FM, Küçükler S (2021) Ameliorative effect of hesperidin on streptozotocin-diabetes mellitus-induced testicular DNA damage and sperm quality degradation in Sprague-Dawley rats. *J Food Biochem* 45: e13938.
- Aksu EH, Kandemir FM, Küçükler S (2021) The effects of hesperidin on colistin-induced reproductive damage, autophagy, and apoptosis by reducing oxidative stress. *Andrologia* 53: e13900.
- Aksu EH, Kandemir FM, Yıldırım S, Küçükler S, Dörtbudak MB, Çağlayan C, Benzer F (2019) Palliative effect of curcumin on doxorubicin-induced testicular damage in male rats. *J Biochem Mol Toxicol* 33: e22384.
- Aksu E, Özkaraca M, Kandemir FM, Ömür AD, Eldutar E, Küçükler S, Çomaklı S (2016) Mitigation of paracetamol-induced reproductive damage by chrysin in male rats via reducing oxidative stress. *Andrologia* 48: 1145-1154.
- Bodnar RJ (2014) Anti-angiogenic drugs: involvement in cutaneous side effects and wound-healing complication. *Adv Wound Care* 3: 635-646.

- Carette C, Levy R, Eustache F, Baron G, Coupaye M, Msika S, Barrat C, Cohen R, Catheline JM, Brugnon F, Slim K, Barsamian C, Chevallier JM, Bretault M, Bouillot JL, Antignac JP, Rives-Lange C, Ravaud P, Czernichow S (2019) Changes in total sperm count after gastric bypass and sleeve gastrectomy: the BARIASPERM prospective study. *Surg Obes Relat Dis* 15: 1271-1279.
- Carvalho RK, Rocha TL, Fernandes FH, Gonçalves BB, Souza MR, Araújo AA, Barbosa CC, Silva DM, Campos HM, Tomazett MV, Ghedini PC, Guimarães FS, Andersen ML, A Santos FC, Mazaro-Costa R (2022) Decreasing sperm quality in mice subjected to chronic cannabidiol exposure: New insights of cannabidiol-mediated male reproductive toxicity. *Chem Biol Interact* 351: 109743.
- Çoban S, Ali A, Türkoğlu A R, Güzelsoy M, Üstündağ Y, Öztürk M, Demirci H (2018) Are there any effect of povidone iodine used in genitourinary surgery on thyroid hormones? *New J Urol* 13: 34-38.
- Donkin I, Barrès R (2018) Sperm epigenetics and influence of environmental factors. *Mol Metab* 14: 1-11.
- Farinon B, Molinari R, Costantini L, Merendino N (2020) The seed of industrial hemp (*Cannabis sativa* L.): Nutritional quality and potential functionality for human health and nutrition. *Nutrients* 12: 1935.
- Fouda MA, Ghovanloo MR, Ruben PC (2020) Cannabidiol protects against high glucose-induced oxidative stress and cytotoxicity in cardiac voltage-gated sodium channels. *Br J Pharmacol* 177: 2932-2946.
- Graczyk M, Lewandowska AA, Dzierżanowski T (2021) The therapeutic potential of cannabis in counteracting oxidative stress and inflammation. *Molecules* 26: 4551.
- Gur C, Akarsu, SA, Akaras N, Tuncer SC, Kandemir FM (2023) Carvacrol reduces abnormal and dead sperm counts by attenuating sodium arsenite-induced oxidative stress, inflammation, apoptosis, and autophagy in the testicular tissues of rats. *Environ Toxicol* 38: 1265-1276.
- Hassan E, Kahilo K, Kamal T, El-Neweshy M, Hassan M (2019) Protective effect of diallyl sulfide against lead-mediated oxidative damage, apoptosis and down-regulation of CYP19 gene expression in rat testes. *Life Sci* 226: 193-201.
- Heymann WR (2000) Potassium iodide and the Wolff-Chaikoff effect: relevance for the dermatologist. *J Am Acad Dermatol* 42: 490-492.
- Islamov R, Kustova T, Nersesyan A, Ilin A (2020) Subchronic toxicity of the new iodine complex in dogs and rats. *Front Vet Sci* 7: 184.
- Johnsen SG (1970) Testicular biopsy score count – a method for registration of spermatogenesis in human testes: normal values and results in 335 hypogonadal males. *Horm Res Paediatr* 1: 2-25.
- Kalkan Y, Kapakin KAT, Kara A, Atabay T, Karadeniz A, Simsek N, Karakuş E, Can I, Yıldırım S, Özkanlar S, Sengul E (2012) Protective effect of Panax ginseng against serum biochemical changes and apoptosis in kidney of rats treated with gentamicin sulphate. *J Mol His* 43: 603-613.
- Karlıdag R, Unal S, Sezer OH, Bay Karabulut A, Battaloğlu B, But A, Özcan C (2006) The role of oxidative stress in post-operative delirium. *Gen Hosp Psychiatry* 28: 418-423.
- Kiralan M, Gül V, Kara SM (2010) Fatty acid composition of hempseed oils from different locations in Turkey. *Span J Agric Res* 8: 385-390.
- Koksal M, Oğuz E, Baba F, Ali Eren M, Ciftci H, Demir ME, Kurcer Z, Aral F, Ocak AR, Aksoy N, Ulas T (2012) Effects of melatonin on testis histology, oxidative stress and spermatogenesis after experimental testis ischemia-reperfusion in rats. *Eur Rev Med Pharmacol Sci* 16: 582-588.
- Maccarrone M, Bab I, Biró T, Cabral GA, Dey SK, Di Marzo V, Konje JC, Kunos G, Mechoulam R, Pacher P, Sharkey KA, Zimmer A (2015) Endocannabinoid signaling at the periphery: 50 years after THC. *Trends Pharmacol Sci* 36: 277-296.
- Matkovic B (1988) Determination of enzyme activity in lipid peroxidation and glutathione pathways. *Laborator Diagnostics* 15: 248-250.
- Matthäus B, Brühl L (2008) Virgin hemp seed oil: An interesting niche product. *Eur J Lipid Sci Technol* 110: 655-661.
- Menghini L, Ferrante C, Carradori S, D'Antonio M, Orlando G, Cairone F, Cesa S, Filippi A, Frascchetti C, Zengin G, AK G, Tacchini M, Iqbal K (2021) Chemical and bioinformatics analyses of the anti-leishmanial and anti-oxidant activities of hemp essential oil. *Biomolecules* 11: 272.
- Noble D, Jablonka E, Joyner MJ, Müller GB, Omholt SW (2014) Evolution evolves: physiology returns to centre stage. *J Physiol* 592: 2237.
- Peeters E, Spiessens C, Oyen R, De Wever L, Vanderschueren D, Miserez M (2014) Sperm motility after laparoscopic inguinal hernia repair with lightweight meshes: 3-year follow-up of a randomised clinical trial. *Hernia* 18: 361-367.
- Placer ZA, Cushman LL, Johnson BC (1966) Estimation of product of lipid peroxidation (malonyl dialdehyde) in biochemical systems. *Anal Biochem* 16: 359-364.
- Sedlak J, Lindsay RH (1968) Estimation of total, protein-bound, and nonprotein sulfhydryl groups in tissue with Ellman's reagent. *Anal Biochem* 25: 192-205.
- Shafiey SI, Ahmed KA, Abo-Saif AA, Abo-Youssef AM, Mohamed WR (2023) Galantamine mitigates testicular injury and disturbed spermatogenesis in adjuvant arthritic rats via modulating apoptosis, inflammatory signals, and IL-6/JAK/STAT3/SOCS3 signaling. *Inflammopharmacology*: doi: 10.1007/s10787-023-01268-z
- Sun Y, Oberley LW, Li Y (1988) A simple method for clinical assay of superoxide dismutase. *Clinic Chem* 34: 497-500.
- Thomas GW, Rael LT, Bar-Or R, Shimonkevitz R, Mains CW, Slone DS, Craun ML Bar-Or D (2009) Mechanisms of delayed wound healing by commonly used antiseptics. *J Trauma* 66: 82-91.
- Zheng Z, Qi J, Hu L, Quyang D, Wang H, Sun Q, Lin L, You Q, Tang B (2022) A cannabidiol-containing alginate based hydrogel as novel multifunctional wound dressing for promoting wound healing. *Biomater Adv* 134: 112560.