

Complications of the intragastric balloon treatment. Small bowel obstruction caused by migrated intragastric balloon — clinical case report and literature review

ANNA RZEPA^{1*}, IZABELA KARPIŃSKA^{1,2*}, JUSTYNA RYMAROWICZ¹, MATEUSZ WIERDAK¹,
MAGDALENA PISARSKA-ADAMCZYK¹, ANNA LASEK¹, PIOTR ZARZYCKI¹, PIOTR MAJOR¹

¹ 2nd Department of General Surgery, Jagiellonian University Medical College, Kraków, Poland

² Doctoral School of Medical and Health Sciences, Jagiellonian University Medical College, Kraków, Poland

* Authors contributed equally to this work

Corresponding author: Izabela Karpińska, M.D.

^{2nd} Department of General Surgery, Jagiellonian University Medical College
ul. Jakubowskiego 2, 30-688 Kraków, Poland

Phone: +48 510 710 066; E-mail: iza.karpinska@doctoral.uj.edu.pl

Abstract: Introduction: An endoscopic intragastric balloon (IGB) placement is one of the minimally invasive methods of obesity treatment. One of the rare serious complications is mechanical bowel obstruction requiring operative management. We report a case of a male patient with small bowel obstruction due to IGB migration and the literature review of complications during IGB treatment.

Detailed Case Description: A patient with a BMI of 28 kg/m² was admitted to the hospital with spontaneous deflation of an IGB. Due to the suspected location of IGB in the ileum laparoscopy was performed. The enterotomy was performed and the IGB removed. The procedure and the postoperative period were uneventful.

Discussion: Spontaneous IGB ruptures are reported in the literature with a frequency ranging from 0.6 to 23%. The majority of deflated devices are spontaneously excreted with the stool with no abdominal symptoms. Only 0.38% of IGBs cause mechanical bowel obstruction of requiring surgical management. Based on our own experience and literature review, we propose the diagnostic and therapeutic algorithm.

Conclusion: Complications after IGB placement can range from mild to severe, that is why it is so important to make an early diagnosis based on the emerging symptoms and to implement prompt management to reduce or avoid serious complications. Any patient reporting disturbing symptoms occurring over a prolonged period of time requires hospitalization and careful observation for the occurrence of gastrointestinal obstruction. The ideal option is hospitalization in the center which implemented the IGB and start with the algorithm we proposed.

Keywords: intragastric balloon, mechanical obstruction, complications, emergency surgery.

Submitted: 18-Feb-2024; **Accepted in the final form:** 10-Jun-2024; **Published:** 30-Jun-2024.



Introduction

Overweight and obesity are defined as abnormal or excessive fat accumulation that presents health risk. It has been described as a global pandemic due to rising prevalence almost universally and over a third of the world's population is now classified as over-weight or obese [1, 2]. According to World Health Organization (WHO), overweight and obesity are linked to more deaths worldwide than underweight and the prevalence of obesity nearly tripled between 1975 and 2016 [3].

Obesity is associated with a vast number of comorbidities, including coronary heart disease, type 2 diabetes mellitus (T2DM), stroke, sleep apnea, musculoskeletal disease, psychiatric diseases and an increase in the prevalence of certain cancers [4]. Consequently, obesity not only shortens life expectancy but also reduces its quality, which makes it one of the greatest challenges of modern medicine.

The health benefits of weight reduction are well established. However, permanent weight loss is frequently difficult to achieve, and the availability of safe and effective weight loss therapies is limited [4]. The conventional treatments, such as a restricted diet, physical activity, and behavioral modification, are usually not effective.

Pharmacological therapy is less invasive and less costly for the management of obesity but results in a limited weight loss and may have significant side effects [4].

Bariatric surgery is the most effective type of obesity treatment resulting in long-term sustained weight loss [4]. Despite all of its advantages, bariatric surgery is invasive and high-cost. Even though recent evidence suggests a trend toward improved safety of bariatric surgery in terms of mortality [4]. However, the presence of comorbid conditions in obese patients leads to higher frequency of postoperative complications [5].

One of the methods for obesity treatment is an intragastric balloon (IGB) insertion. An IGB placement is one of the minimally invasive methods of obesity treatment that has been introduced in 1980s [6]. However, due to the unsatisfactory short-term results, especially quick weight regain after IGB removal, it is currently used mostly as the first step of multi-stage treatment in patients with body mass index (BMI) over 50 kg/m². In selected cases of patients who are not inclined to undergo bariatric surgery at the moment of qualification but require weight reduction as bridge to bariatric or another type of surgery including: hernia, endoprosthesis surgery or other orthopedic procedures, kidney surgery or heart transplantation [7]. Different specific indication for the IGB placement is patients with severe obesity causing possible technical difficulties during the operation. Among others these are: males, patients with visceral type of obesity or unfavorable anatomical proportions. IGB treatment has been associated with prolonged overall duration of treatment and additional costs. On the other hand, it has been shown in recent studies that therapy with the use of IGB is not significantly associated with increased perioperative morbidity, prolonged operative time or length of hospital stay. One of the important advantages of an IGB placement prior to final bariatric surgery is the reduction of perioperative complications [8].

IGB placement is known to be safe, reversible, and associated with a low rate of serious complications and mortality [9, 10]. However, overall morbidity rate reach over 30% [11]. The most common complications are abdominal pain, acid reflux, burping or nausea and vomiting which result from the lack of stomach tolerance.

One of the rare serious complications is mechanical bowel obstruction requiring operative management. We report a case of a male patient with small bowel obstruction due to IGB migration and the literature review of complications during IGB treatment.

Detailed Case Description

A 42-year-old man with a BMI of 28 kg/m² and a weight of 112 kg was admitted to the hospital with a severe epigastric pain, worse on the right side. The other symptoms were: nausea, vomiting, alternating obstipation and rectal bleeding. Symptoms had persisted for approximately two weeks. He had undergone IGB placement for weight loss 23 months prior in a private care clinic. Patient's weight loss during IGB treatment was approximately 12 kg. IGB was not removed within the prescribed time of six months despite the recommendations of the attending surgeon. Patient's past medical history includes type 2 diabetes — controlled without any medications and arterial hypertension. As for surgical history patient underwent an open appendectomy in childhood.

Two days before admission to our department, the esophagogastroduodenoscopy (EGD) under general anesthesia was performed, with the intention of removing prolonged IGB. Unfortunately, no balloon was found during examination. The proposal of hospitalization and further diagnostics in the local hospital was rejected by the patient.

At admission, the patient was hemodynamically stable, in logical verbal contact. Physical examination showed abdominal distension, mild epigastric tenderness, no peritonitis signs. Normal peristalsis was found during auscultation. The liver and the spleen were not enlarged. Additionally, there were no significant changes during per rectum examination.

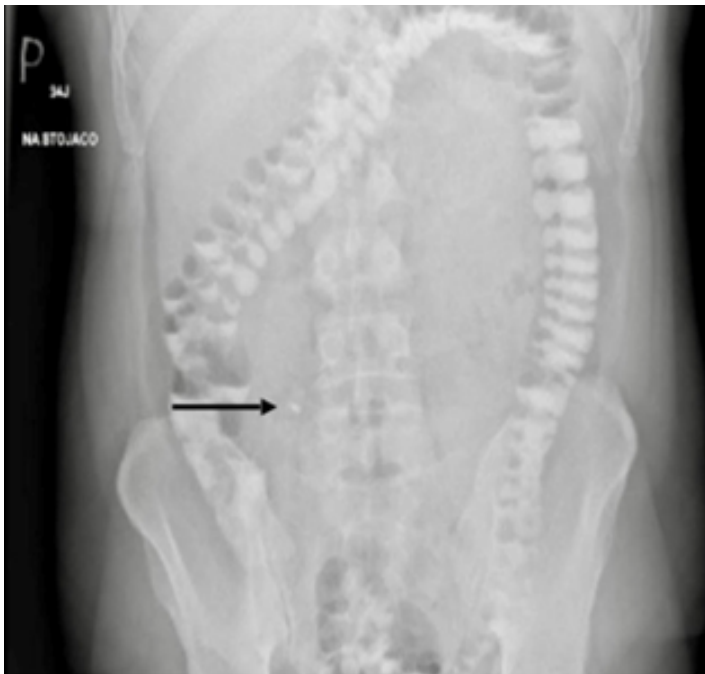

Fig. 1. X-ray of the abdomen black arrow indicates the IGB catheter.

His initial laboratory test results showed mild leucocytosis with a normal C-reactive protein level. Abdominal X-ray in a standing position showed a shadow above the right iliac fossa which could represent the IGB part (Fig. 1). Subsequently, an intravenous contrast-enhanced computed

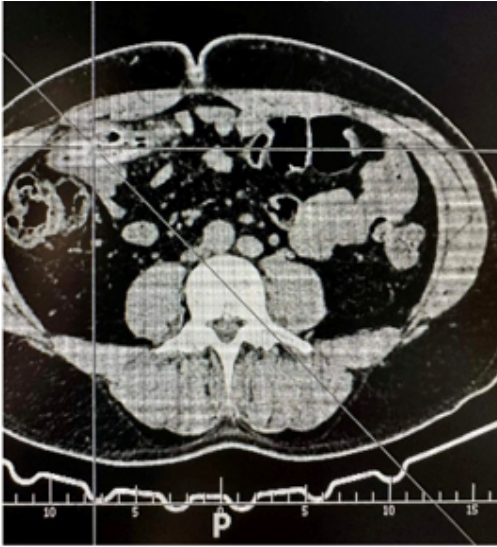


Fig. 2. CT of the abdomen, cross-section; lines indicate the IGB.

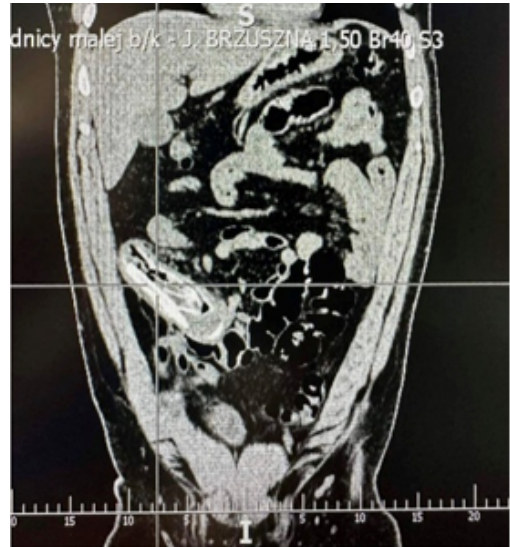


Fig. 3. CT of the abdomen, frontal section; lines indicate the IGB.

tomography of the abdomen and pelvis (CTAP) was performed, which delineated the IGB within the lumen of the ileum in the area of right mesogastrium and right hypogastrium (Fig. 2 and Fig. 3). Due to the suspected location of IGB in the terminal ileum, a colonoscopy was performed. The device was placed in approximately 30 cm of the final section of the unchanged small intestine. No foreign body was detected in the examined section of the intestine.

Due to the development of gastrointestinal obstruction patient was qualified for the surgery. Elective laparoscopy was performed. Intraoperatively a conglomerate of a thickened small bowel loops with a solid body shape inside were identified. The loops were freed meticulously, the segment of the bowel just above the solid body shape was incised longitudinally and the migrated IGB was visualized and removed. The enterotomy was closed transversely with a one-layer continuous Stratafix 3-0 suture (Photo 1). A 16F drain was placed on the right side around the closed enterotomy.

There were no adverse events during the procedure. On the second postoperative day, abdominal pain and a slight increase in inflammatory parameters occurred, which were released after pharmacological treatment. The administered antibiotic therapy included metronidazole at a dose of 500 mg three times a day and ceftriaxone, a third-generation cephalosporin, at a dose of 2 grams every 12 hours. The patient passed stool on the second day evening after surgery. The further course of hospitalization was uneventful. In the following days of hospitalization, we observed a gradual improvement in the patient's clinical condition and a decrease in inflammatory parameters. A full oral diet was started on the third day of hospital stay. The drain was removed on the fourth postoperative day. The patient was discharged home in good general condition on the fifth postoperative day. The total length of hospital stay was seven days.

During follow-up visits to the surgical outpatient clinic, the patient did not report any symptoms. On physical examination, the abdomen was soft, painless, and without peritoneal symp-

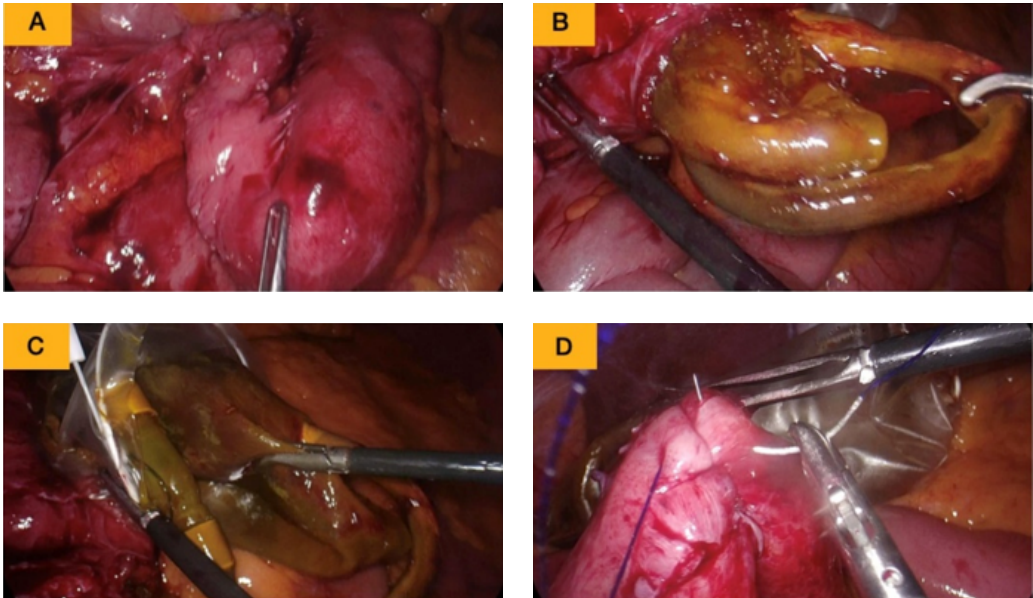


Photo 1. Stages of laparoscopy; A — place of the obstruction; B — IGB retrieval; C — putting in endobag; D — closing the enterotomy.

toms. The patient did not have a fever. He passed stools normally, without any blood. After a week, the skin sutures from the trocar wounds were removed. Due to the leakage of serous-turbid fluid from the wound around the navel, the patient took an antibiotic (Amoxicillin and Clavulanic Acid in the dose of 875 mg + 125 mg two times a day) prescribed by the primary care physician for a week. After a month of observation at follow-up visits, the wounds healed properly and the treatment was completed.

Discussion

Mild and severe complications after IGB placement

The frequency and severity of complications associated with IGB treatment depends on the type of balloon and the method of insertion. Endoscopically inserted fluid filled IGBs, the most commonly used, are simultaneously the least tolerated. If symptoms of balloon intolerance last over seven days it may lead to spontaneous deflation of IGB or its early removal [12]. Interestingly, individuals who reported at least two intolerance symptoms achieved the highest BMI reduction compared to other patients [13].

Serious adverse events after IGB placement include: bleeding, spontaneous hyperinflation, acute pancreatitis due to the external compression of the pancreatic duct or acute renal failure caused by the IGB compression of the renal vessels [14, 15]. Among all the IGB migration and gastric ulceration or perforation are the most frequently reported severe complications [16]. Table 1 presents the most recent studies reporting the most common complications and their frequency.

Spontaneous deflation of the IGB

Spontaneous IGB ruptures are reported in the literature with a frequency ranging from 0.6 to 23%.

All IGBs are inflated with 600–700 ml of 0.9% saline solution mixed with of methylene blue. After IGB insertion, each patient is informed about possible side effects and complications. One of them is greenish urine which occurs in case of spontaneous deflation. When the patient notices greenish urine he should immediately presents to the emergency department and an EGD should be attempt to remove the IGB [17].

Radiographic imaging such as abdominal radiograph, ultrasound of the abdominal cavity or CTAP are performed to confirm spontaneous IGB deflation, with the latter being the most sensitive in patients with obesity [18].

The majority of deflated devices are spontaneously excreted with the stool with no abdominal symptoms [19]. Only 0.38% of deflated IGBs cause mechanical bowel obstruction requiring surgical management [19].

The likelihood of IGB rupture resulting in bowel obstruction increases with prolonged IGB removal time longer than recommended six months [14]. Patients failing to attend follow-up appointments, as with the case described in this report, could explain such findings in the majority of cases. However, there are seven case reports available in the literature which have described small-bowel obstruction from a migrated intragastric balloon inserted within six months, with the shortest period among all cases being just one month [10, 19–24]. In summary the risk of balloon deflation and subsequent migration will increase over time, but this complication may occur early and within the recommended six-month retrieval time.

Along with usually symptoms of small-bowel obstruction, patients usually attend the emergency department with cramping abdominal pain associated with nausea, vomiting [25]. The duration of symptoms prior to seeking medical assistance varies from a few hours up to seven days [25]. Furthermore, the symptom profile does not seem to correlate with the anatomical location of obstruction [25].

According to the available literature IGB obstruction levels are located mostly between the first portion of the duodenum and the terminal ileum with no single location particularly common [25].

Kim et al reported a case of an obstructing intragastric balloon in the sigmoid colon [26]. To date, this appears to be the only case of large-bowel obstruction caused by deflated IGB. Authors could not provide the explanation about how the balloon had migrated so far in gastrointestinal tract.

Interestingly, in the literature is also reported one case of a 46-year-old patient with intragastric balloon found lodged inside an incidental Meckel's diverticulum, causing a near-complete occlusion of the small bowel lumen. The treatment involved resection of affected segment of small bowel, with side-to-side anastomosis [27].

Diagnostic and therapeutic algorithm for IGB deflation

In the case of more severe and long-lasting symptoms occurring after the adaptive phase such as vomiting, dehydration, absence of passage of flatus and feces, the patient should be admitted to the hospital.

Based on our own experience and literature review, we propose the following solution in the form of the diagnostic and therapeutic algorithm.

The standard procedure is the prohibition of oral food intake, intravenous fluids and proton pump inhibitor, correction of electrolyte imbalance (especially hypokalemia caused by vomiting), and in the case of a large gastric retention, the insertion of a nasogastric tube.

Basic laboratory tests should be ordered (complete blood cell count), C-reactive protein (CRP) level, metabolic panel including sodium and potassium levels, blood urea nitrogen (BUN) and creatinine, coagulation parameters including activated partial thromboplastin time (APTT), prothrombin time (PT) and activated partial thromboplastin time (INR) and blood type assay.

Additionally, we recommend to indicate liver enzymes like: alkaline phosphatase (ALP), alanine transaminase (ALT), and aspartate aminotransferase (AST) as well as bilirubin level

In the case of suspected spontaneous rupture, imaging diagnostics is indicated. Simple and cheap method of visualizing IGB in the stomach, which does not require specialist facilities, is abdominal ultrasound (Photo 2). However, it is worth noticing that it has relatively low sensitivity in obese patients due to the low translucency of the integumentary tissues. An X-ray will be useful to exclude perforation of the gastrointestinal tract and to indicatively locate the position of the IGB. However, the gold standard for assessing the exact level of the obstruction and the location of the foreign body is CT scan.

Detailed management algorithm proposed by our team and used on a daily basis in our department is presented in the Fig. 4.

Intervention methods

The method of treatment is determined mainly by the level of obstruction, in the minority by the severity of the basic disease and the operational skills of the doctor performing the procedure.

When the IGB is located in the duodenum or the terminal ileum, an endoscopic procedure (EGD or colonoscopy) is usually sufficient to retrieve the IGB from gastrointestinal tract.

If it is located in the jejunum or the ileum, surgical management is required. In the literature open procedure prevails the laparoscopic approach (66% vs. 15%) [4]. Besides the case presented in this report, there have been five laparoscopic removals of migrated IGB in the literature [10, 28–31]. Balloon was retrieved in these cases from either the jejunum or the ileum without further complications.

There were a few attempts to remove the balloon non-operatively. Vlachou *et al.* reported the use of antegrade double-balloon enteroscopy to recover the deflated balloon from the ileum [32]. Until now, there were nearly three case reports of percutaneous aspiration of a partially deflated balloon [33–35]. Two of them were successful, whereas during the third attempt in 2012, the balloon impacted again distally in the small bowel, necessitating open surgery [33–35]. Recently, scientific consensus seems to state that the technique of percutaneous needle aspiration should be considered only when partially deflated balloon is accessible percutaneously, evaluated by radiological imaging.

Conclusions

Endoscopically inserted IGBs are a minimally invasive bariatric procedures performed worldwide with a low rate of adverse events. Complications after IGB placement can range from mild to severe. One of the most common serious complications is IGB deflation, as it may cause intestine obstruction and consequently death. That is why it is so important to make an early diagnosis

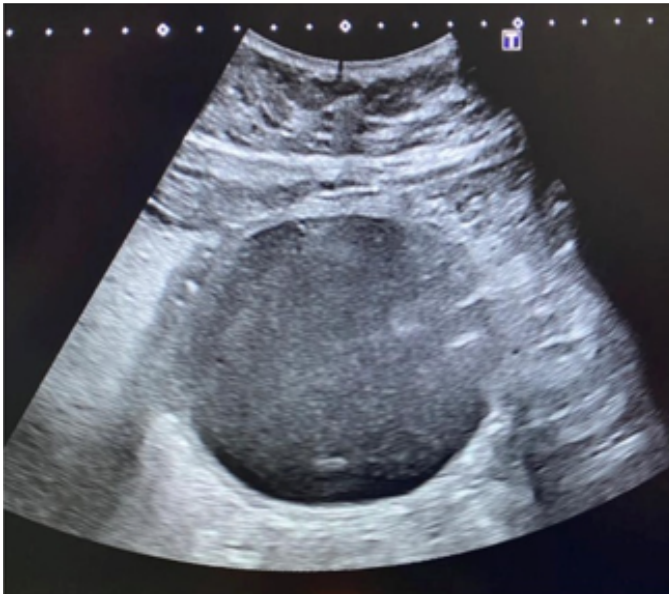


Photo 2. Abdominal ultrasound — IGB in the stomach.

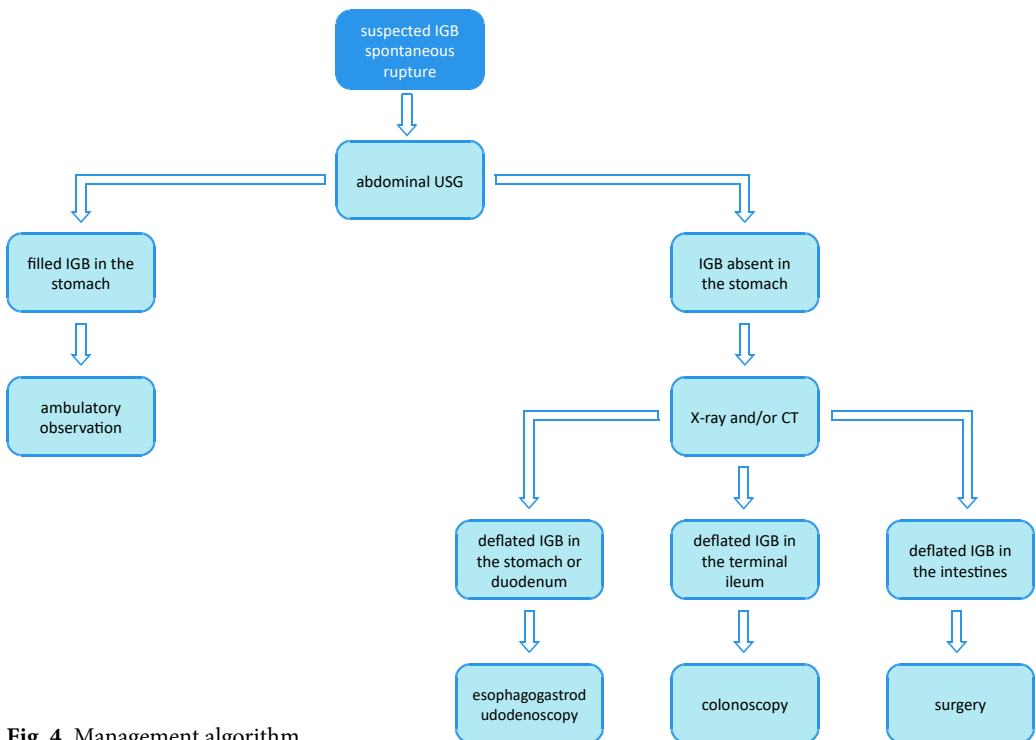


Fig. 4. Management algorithm.

based on the emerging symptoms and to implement prompt management to reduce or avoid repercussions. Any patient reporting disturbing symptoms occurring over a prolonged period of time after IGB placement requires hospitalization and careful observation for the occurrence of gastrointestinal obstruction. Diagnostics should involve radiological imaging with the use of CT scan which remains the gold standard for assessing the exact level of the bowel obstruction and the location of the IGB through the body. The ideal option is hospitalization in the center which implemented the IGB and start with the algorithm we proposed. However, it may not always be possible as many IGBs are performed on an outpatient clinics.

Funding

This research did not receive any specific grant from funding agencies in the public, commercial, or not-for-profit sectors.

Disclosures

All authors declare no competing interests.

References

1. Swinburn B.A., et al.: The global obesity pandemic: shaped by global drivers and local environments. *Lancet*. 2011 Aug; 378 (9793): 804–814. doi: 10.1016/S0140-6736(11)60813-1.
2. Ng M., et al.: Global, regional, and national prevalence of overweight and obesity in children and adults during 1980–2013: a systematic analysis for the Global Burden of Disease Study 2013. *Lancet*. 2014 Aug; 384 (9945): 766–781. doi: 10.1016/S0140-6736(14)60460-8.
3. Obesity and overweight. Accessed: Jan 18, 2024. [Online]. Available: <https://www.who.int/news-room/fact-sheets/detail/obesity-and-overweight>.
4. Ribeiro da Silva J., et al.: Intra-gastric Balloon for Obesity Treatment: Safety, Tolerance, and Efficacy. *GE Port J Gastroenterol*. 2018 Sep; 25 (5): 236–242. doi: 10.1159/000485428.
5. Arterburn D.E., Telem D.A., Kushner R.F., Courcoulas A.P.: Benefits and Risks of Bariatric Surgery in Adults: A Review. *JAMA*. 2020 Sep; 324 (9): 879–887. doi: 10.1001/jama.2020.12567.
6. Li S.-H., Wang Y.-J., Zhang S.-T.: Development of Bariatric and Metabolic Endoscopy. *Chin Med J (Engl)*. 2018 Jan; 131 (1): 88–94. doi: 10.4103/0366-6999.221283.
7. Hering I., et al.: Impact of preoperative weight loss achieved by gastric balloon on peri- and postoperative outcomes of bariatric surgery in super-obese patients: a retrospective matched-pair analysis. *Langenbecks Arch Surg*. 2022 Aug; 407 (5): 1873–1879, doi: 10.1007/s00423-022-02472-1.
8. Busetto L., et al.: Preoperative weight loss by intra-gastric balloon in super-obese patients treated with laparoscopic gastric banding: a case-control study. *Obes Surg*. 2004 May; 14 (5): 671–676. doi: 10.1381/096089204323093471.
9. Rzepa A., et al.: Impact of Intra-gastric Balloon Placement on the Stomach Wall: A Prospective Cohort Study. *Obes Surg*. 2022 Jul; 32 (7): 2426–2432. doi: 10.1007/s11695-022-06101-0.
10. Al-Subaie S., Al-Barjas H., Al-Sabah S., Al-Helal S., Alfakharani A., Termos S.: Laparoscopic management of a small bowel obstruction secondary to Elipse intra-gastric balloon migration: A case report. *Int J Surg Case Rep*. 2017; 41: 287–291. doi: 10.1016/j.ijscr.2017.10.050.
11. Mitura K., Garnysz K.: Tolerance of intra-gastric balloon and patient's satisfaction in obesity treatment. *Wideochir Inne Tech Maloinwazyjne*. 2015 Sep; 10 (3): 445–449. doi: 10.5114/wiitm.2015.54047.

12. Papademetriou M., Popov V.: Intragastric balloons in clinical practice. *Gastrointest Endosc Clin N Am*. 2017 Apr; 27 (2): 245–256. doi: 10.1016/j.giec.2016.12.006.
13. Jamal M.H., et al.: A Study Examining the Orbera365 Intragastric Balloon Safety and Effects on Weight Loss. *Obes Surg*. 2021; 31 (12). doi: 10.1007/S11695-021-05729-8.
14. UPDATE: Potential Risks with Liquid-filled Intragastric Balloons — Letter to Health Care Providers. Accessed: Jan 18, 2024. [Online]. Available: <https://public4.pagefreezer.com/content/FDA/08-08-2023T13:42/https://www.fda.gov/medical-devices/letters-health-care-providers/update-potential-risks-liquid-filled-intragastric-balloons-letter-health-care-providers>.
15. Aljahlili E.S.: Ischemic Renal Injury Complicating Intragastric Balloon Insertion. *ACG Case Rep J*. 2018; 5: e16. doi: 10.14309/crj.2018.16.
16. Lim R.B., Sullivan S.: Intragastric balloon therapy for weight loss. Accessed: Jan 18, 2024. [Online]. Available: <https://medilib.ir/uptodate/show/106357>.
17. Silva L.B., Neto M.G.: Intragastric balloon. *Minim Invasive Ther Allied Technol*. 2022 Apr; 31 (4): 505–514. doi: 10.1080/13645706.2021.1874420.
18. Vanden Eynden F, Urbain P.: Small intestine gastric balloon impaction treated by laparoscopic surgery. *Obes Surg*. 2001 Oct; 11 (5): 646–648. doi: 10.1381/09608920160556913.
19. Twardzik M., Wiewiora M., Glück M., Piecuch J.: Mechanical intestinal obstruction caused by displacement of a stomach balloon — case report. *Wideochir Inne Tech Maloinwazyjne*. 2018 Jun; 13 (2): 278–281. doi: 10.5114/wiitm.2018.73446.
20. Mousavi Naeini S.M., Sheikh M.: Bowel Obstruction due to Migration of an Intragastric Balloon Necessitating Surgical Removal before Completion of the Recommended 6 Months. *Case Rep Med*. 2012; 2012: 414095. doi: 10.1155/2012/414095.
21. Al-Zubaidi A.M., Alghamdi H.U., Alzobydi A.H., Dhiloon I.A., Qureshi L.A.: Bowel perforation due to break and distal passage of the safety ring of an adjustable intra-gastric balloon: A potentially life threatening situation. *World J Gastrointest Endosc*. 2015 Apr; 7 (4): 429–432. doi: 10.4253/wjge.v7.i4.429.
22. Öztürk A., Yavuz Y., Atalay T.: A Case of Duodenal Obstruction and Pancreatitis Due to Intragastric Balloon. *Balkan Med J*. 2015 Jul; 32 (3): 323–326. doi: 10.5152/balkanmedj.2015.15312.
23. Vlachou E., et al.: Small bowel obstruction caused by a migrated Obalon gastric bariatric balloon: non-surgical management by antegrade double-balloon panenteroscopy. *Endoscopy*. 2016; 48 (S 01): E403–E404. doi: 10.1055/s-0042-120289.
24. Brooks J., et al.: Percutaneous Needle Aspiration of a Partially Deflated Intragastric Balloon: a Forgotten Modality? Review of the Literature. *Obes Surg*. 2018 Jun; 28 (6): 1781–1784. doi: 10.1007/s11695-018-3205-0.
25. Hay D., Ryan G., Somasundaram M., Yip V., Navaratne L.: Laparoscopic management of a migrated intragastric balloon causing mechanical small bowel obstruction: a case report and review of the literature. *Ann R Coll Surg Engl*. 2019 Nov; 101 (8): e172–e177. doi: 10.1308/rcsann.2019.0104.
26. Kim W.Y., Kirkpatrick U.J., Moody A.P., Wake P.N.: Large bowel impaction by the BioEnterics Intragastric Balloon (BIB®) necessitating surgical intervention. *Ann R Coll Surg Engl*. 2000; 82: 202–204.
27. Young E., Raju D.P., Ryan M.: Intragastric balloon inside a Meckel's diverticulum: a rare cause of small bowel obstruction. *ANZ J Surg*. 2020 Dec; 90 (12): E210–E211. doi: 10.1111/ans.16007.
28. Hay D., Ryan G., Somasundaram M., Yip V., Navaratne L.: Laparoscopic management of a migrated intragastric balloon causing mechanical small bowel obstruction: a case report and review of the literature. *Ann R Coll Surg Engl*. 2019 Nov; 101 (8): e172–e177. doi: 10.1308/rcsann.2019.0104.
29. Vanden Eynden F, Urbain P.: Small intestine gastric balloon impaction treated by laparoscopic surgery. *Obes Surg*. 2001 Oct; 11 (5): 646–648. doi: 10.1381/09608920160556913.
30. Di Saverio S., et al.: Complete small-bowel obstruction from a migrated intra-gastric balloon: emergency laparoscopy for retrieval via enterotomy and intra-corporeal repair. *Obes Surg*. 2014 Oct; 24 (10): 1830–1832. doi: 10.1007/s11695-014-1271-5.

31. *Al Shammari N.M., Alshammari A.S., Alkandari M.A., Abdulsalam A.J.*: Migration of an intragastric balloon: A case report. *Int J Surg Case Rep.* 2016; 27: 10–12. doi: 10.1016/j.ijscr.2016.08.006.
32. *Vlachou E., et al.*: Small bowel obstruction caused by a migrated Obalon gastric bariatric balloon: non-surgical management by antegrade double-balloon panenteroscopy. *Endoscopy.* 2016; 48 (S 01): E403–E404. doi: 10.1055/s-0042-120289.
33. *Frimberger E., Kühner W., Weingart J., Waldthaler A., Ottenjann R.*: Percutaneous decompression of an intrainestinal balloon — case report. *Hepatogastroenterology.* 1982 Feb; 29 (1): 38–39.
34. *Holland S., Bach D., Duff J.*: Balloon therapy for obesity — when the balloon bursts. *J Can Assoc Radiol.* 1985 Dec; 36 (4): 347–349. <http://www.ncbi.nlm.nih.gov/pubmed/4086508>.
35. *Hegade V.S., Sood R., Douds A.C.*: Small bowel obstruction induced by spontaneous partial deflation of an intragastric balloon. *Ann R Coll Surg Engl.* 2012 May; 94 (4): e171–173. doi: 10.1308/003588412X13171221590539.