

DOI 10.24425/pjvs.2026.158501

Original article

Evaluation of effectiveness of oleanolic acid in rat testicular ischemia-reperfusion injury model

S.-M. Wei^{1,2}, Y.-M. Huang³

¹ Shulan International Medical College, Zhejiang Shuren University, 310015 Hangzhou City, China

² School of Nursing, Zhejiang Chinese Medical University, 310053 Hangzhou City, China

³ Department of Sports Science, College of Education, Zhejiang University, 310058 Hangzhou City, China

Correspondence to: S.-M. Wei, e-mail: wsm1971@hotmail.com, tel.: +86 15268133671

Abstract

Following testicular ischemia, the return of blood circulation promotes reactive oxygen species formation. By damaging cellular components such as proteins, DNA and lipids, reactive oxygen species negatively affect testicular spermatogenic function. Numerous plant species, particularly those within the Oleaceae family, contain oleanolic acid as a principal active ingredient. Extensive research has confirmed oleanolic acid's efficacy in exerting antioxidant action. We examined the therapeutic potential of oleanolic acid in mitigating testicular damage induced by ischemia-reperfusion in rats. The study included three groups, each comprising twenty male rats: a sham group, an ischemia-reperfusion group, and an ischemia-reperfusion group treated with oleanolic acid (30 mg/kg). Left testicular torsion of 720 degrees counterclockwise, maintained for 2 hours, induced testicular ischemia-reperfusion injury. After surgical detorsion of the left testis, the ischemia-reperfusion + oleanolic acid group was treated immediately with a single 30 mg/kg dose of oleanolic acid via intraperitoneal injection. Multiple analytical procedures were performed on testicular tissues collected from the three rat groups. Biochemical measurements encompassed both nicotinamide adenine dinucleotide phosphate (NADPH) oxidase activity (critical for reactive oxygen species production) and malondialdehyde concentration (a reactive oxygen species indicator). We used hematoxylin-eosin staining for the evaluation of spermatogenic function in testicular tissue. Relative to the sham group, the ischemia-reperfusion group exhibited significantly elevated NADPH oxidase activity and malondialdehyde levels in ipsilateral testes, accompanied by impaired spermatogenic function ($p < 0.05$). Oleanolic acid intervention effectively suppressed oxidative stress markers (NADPH oxidase activity and malondialdehyde levels) in ipsilateral testes, relatively enhancing spermatogenic capacity ($p < 0.05$). Overall, oleanolic acid enhances testicular spermatogenic function by lowering NADPH oxidase activity and curbing reactive oxygen species formation.

Keywords: antioxidant, ischemia-reperfusion, oleanolic acid, oxidative stress, testicular torsion



Introduction

Testicular torsion, characterized by twisting of the spermatic cord, results in impaired blood flow to the testis (Yildizhan et al. 2023). As a urologic emergency requiring immediate attention, it occurs in approximately 1 in 4,000 men under 25 years of age (Anderson et al. 2025). Surgical detorsion must be performed promptly to reestablish circulation and prevent testicular necrosis (Mohammadnejad et al. 2025b). Testicular atrophy was observed in 9.2%-41.29% of cases during postoperative follow-up examinations of salvaged testes (Delgado-Miguel et al. 2025, Wei et al. 2025). The pathogenesis of torsion/detorsion-induced testicular injury involves reactive oxygen species (Hu et al. 2025). Following testicular ischemia, the return of blood circulation promotes reactive oxygen species formation (Hu et al. 2025). Superoxide radicals, hydroxyl radicals, hydrogen peroxide and other compounds collectively form reactive oxygen species (Zolfaghari et al. 2025). By damaging cellular components such as proteins, DNA and lipids, reactive oxygen species negatively affect testicular spermatogenic function (Izanloo et al. 2021, Hu et al. 2025).

To date, no pharmaceutical treatment has been clinically implemented to alleviate injury resulting from testicular ischemia-reperfusion (Zolfaghari et al. 2025). Numerous plant species, particularly those within the Oleaceae family, contain oleanolic acid as a principal active ingredient (Sapkota and Choi 2022). With a chemical formula of $C_{30}H_{48}O_3$, oleanolic acid has a molecular weight of 456.70. Extensive research has confirmed oleanolic acid's efficacy in exerting antioxidant and anti-inflammatory actions (Cai et al. 2021). Oleanolic acid demonstrates organoprotective effects against ischemia/reperfusion damage, with benefits observed in the kidney, heart, brain and liver (Du and Ko 2006, Hao et al. 2016, Wang et al. 2019, Cai et al. 2021, Yang et al. 2021, Sapkota and Choi 2022, Pi et al. 2024, Chen et al. 2025). Despite its known protective effects in these organs, oleanolic acid's potential benefits for testicular ischemia-reperfusion injury remain unexplored. Hence, the present study aimed to elucidate the protective properties and action mechanisms of oleanolic acid against testicular ischemia-reperfusion damage following torsion-detorsion.

Materials and Methods

Animals

This research used a cohort of 60 male Sprague-Dawley rats at the age of eight weeks, each with a body mass of 250-300 g. All rodents used in this investiga-

tion were sourced from the SLAC company, Shanghai, China. The housing environment consisted of barrier-controlled facilities with the following parameters: 12-hour light/dark intervals, relative humidity maintained between 50% and 60%, ambient temperature controlled at $21\pm 1^\circ\text{C}$, and adequate ventilation. Conventional laboratory rodent food and tap water were supplied ad libitum to all experimental animals. The research began only after they had completed seven days of acclimatization. Ethical clearance for all animal experiments was granted by Zhejiang Shuren University Ethics Committee (Protocol ID: 202401051). The surgical protocols conformed rigorously to established laboratory animal care standards.

Animal model of testicular ischemia-reperfusion injury and oleanolic acid therapy

Three experimental cohorts were formed through random assignment, with each group consisting of twenty rats. Intraperitoneal anesthesia was induced using ketamine (Sigma-Aldrich, Saint Louis, MO, USA) at 50 mg/kg. All surgical interventions adhered to sterile protocols. Surgical exposure of the left testis was achieved via a left ilioinguinal incision. In the sham group, sham operations were conducted that did not involve torsion and subsequent detorsion of the left testis (Wei et al. 2022). The skin incision was sutured subsequent to repositioning the left testis to its native position. Ischemia was maintained in the left testis of the ischemia-reperfusion group by performing a 720° counterclockwise twist and anchoring the organ to the scrotum with an 11/0 suture (Wei et al. 2022). Reperfusion was initiated by removing the fixation suture and performing clockwise detorsion of the left testis to its normal position following 2 hours of ischemia. Prompt administration of 30 mg/kg oleanolic acid (Sigma-Aldrich) via intraperitoneal injection was performed in the treatment group following testicular detorsion. Our dosage selection (30 mg/kg oleanolic acid) was guided by existing reports in published literature (Hao et al. 2016, Wang et al. 2019, Sapkota and Choi 2022). Ten animals per group were randomly sampled upon completion of the 4-hour testicular detorsion interval. The left and right testes were excised from the rats to measure nicotinamide adenine dinucleotide phosphate (NADPH) oxidase activity and quantify malondialdehyde content. Following the 3-month detorsion interval, the residual 10 rodents per group were incorporated into the study. To evaluate spermatogenic function in the testes, both left and right testes were collected from rats.

Quantification of NADPH oxidase activity in testicular tissue

After homogenization in chilled lysis buffer, the testicular samples were centrifuged for 10 minutes at $10,000 \times g$ and 4°C . For NADPH oxidase activity analysis, the supernatant was carefully collected. The activity of NADPH oxidase was determined with a commercially available kit from Jiancheng Bioengineering Institute (Nanjing, China).

Assay for determining malondialdehyde levels

The procedure began by homogenizing the testicular tissue in pre-cooled lysis solution using a glass homogenizer. Subsequent analyses were performed using the supernatant collected after 15 minutes of centrifugation at $5,000 g$ under 4°C conditions. The malondialdehyde content was measured according to the manufacturer's protocol using a reagent from Jiancheng Bioengineering Institute (Nanjing, China) (Shakouri et al. 2021).

Morphological examination of histological preparations

Testicular spermatogenic function was evaluated using four key parameters: number of epithelial layers in the seminiferous tubule, seminiferous tubular diameter, testicular weight, and Johnsen's biopsy score (Soleimanzadeh et al. 2024, Wei and Huang 2024b). Testicular weight was measured using an electronic balance. The testicular tissues, previously immersed in Bouin's fixative, underwent alcohol dehydration before immediate paraffin embedding. Following microtome sectioning at $5 \mu\text{m}$ thickness, the samples were processed for hematoxylin-eosin staining (Sigma-Aldrich). Histomorphological evaluation was carried out on the stained tissue sections under an optical microscope, with the assessor blinded to experimental groups. The study involved randomly selecting twenty seminiferous tubules per section (5 sections per testis) and examining their number of epithelial layers, tubular diameter, and Johnsen's biopsy score. The number of epithelial layers in the seminiferous tubule was counted from basement membrane to lumen. Using an ocular micrometer, the researcher quantified the tubular diameter. Spermatogenic activity was evaluated based on the 10-point Johnsen scoring scale (Johnsen 1970). Tubules received the maximum score of 10 if they exhibited both an unobstructed lumen and optimal spermatogenesis, marked by the presence of plentiful fully developed sperms (Johnsen 1970). Nevertheless, neither spermatogenic cells nor Sertoli cells were classified as 1 (Johnsen 1970).

Statistical analysis

Statistical processing was carried out using version 4.0 of GraphPad Prism (San Diego, CA, USA). We used the Shapiro-Wilk test to ensure that quantitative data were normally distributed. The mean \pm standard deviation was used to present continuous variables. A one-way analysis of variance served as the method for comparing groups. Subsequent pairwise comparisons were carried out with the Student-Newman-Keuls test. For within-group comparisons, the t-test was applied to examine mean differences between ipsilateral and contralateral testes. Results were deemed statistically significant when p-values were below 0.05.

Results

Role of oleanolic acid administration in regulating NADPH oxidase activity in testes following ischemia-reperfusion injury

NADPH oxidase activity was significantly higher ($p < 0.05$) in the ipsilateral testis following ischemia-reperfusion than in the sham group (Fig. 1). Compared to the ischemia-reperfusion group, oleanolic acid-treated (30 mg/kg) ipsilateral testes demonstrated a marked reduction ($p < 0.05$) in NADPH oxidase activity. When contralateral testes were compared across groups, NADPH oxidase activity showed no significant ($p > 0.05$) intergroup variation.

Role of oleanolic acid administration in regulating level of malondialdehyde in testes following ischemia-reperfusion injury

A significant increase ($p < 0.05$) in level of malondialdehyde in the ipsilateral testis was seen in the ischemia-reperfusion group, as illustrated in Fig. 2, when compared to the sham group. Treatment with oleanolic acid (30 mg/kg) resulted in a marked decrease in the ipsilateral testicular level of malondialdehyde ($p < 0.05$) relative to the ischemia-reperfusion group. The three groups exhibited a comparable level of malondialdehyde ($p > 0.05$) in contralateral testes.

Role of oleanolic acid administration in regulating spermatogenic function in testes following ischemia-reperfusion injury

As illustrated in Figs. 3 and 4, the sham group exhibited normal testicular spermatogenic function, including the number of epithelial layers in the seminiferous tubule, tubular diameter, testicular weight, and Johnsen's biopsy score. In contrast, the ischemia-reperfusion group displayed a marked ($p < 0.05$) reduction

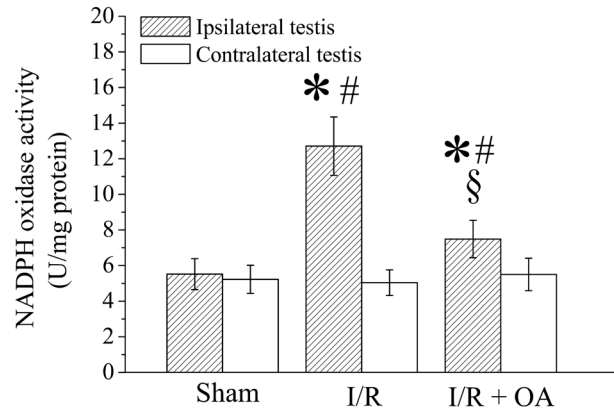


Fig. 1. Assessment of nicotinamide adenine dinucleotide phosphate (NADPH) oxidase activity in testicular tissues across experimental rat groups: sham, ischemia-reperfusion (I/R), and oleanolic acid (OA)-treated groups; $n=10$ each. The mean \pm standard deviation was used to present continuous variables. A one-way analysis of variance served as the method for comparing groups. Subsequent pairwise comparisons were carried out with the Student-Newman-Keuls test. For within-group comparisons, the t-test was applied to examine mean differences between ipsilateral and contralateral testes. * signified $p<0.05$ relative to sham group; § signified $p<0.05$ relative to ipsilateral testis in I/R group; # signified $p<0.05$ relative to contralateral testis within group.

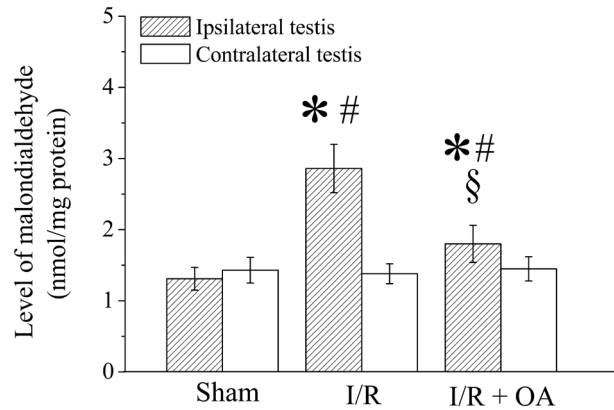


Fig. 2. Assessment of level of malondialdehyde in testicular tissues across experimental rat groups: sham, ischemia-reperfusion (I/R), and oleanolic acid (OA)-treated groups; $n=10$ each. The mean \pm standard deviation was used to present continuous variables. A one-way analysis of variance served as the method for comparing groups. Subsequent pairwise comparisons were carried out with the Student-Newman-Keuls test. For within-group comparisons, the t-test was applied to examine mean differences between ipsilateral and contralateral testes. * signified $p<0.05$ relative to sham group; § signified $p<0.05$ relative to ipsilateral testis in I/R group; # signified $p<0.05$ relative to contralateral testis within group.

in ipsilateral testicular spermatogenic function. Oleanolic acid (30 mg/kg) treatment led to a significant ($p<0.05$) attenuation of ipsilateral testicular injury. Compared to the sham group, neither the ischemia-reperfusion group nor the oleanolic acid-treated group showed significant ($p>0.05$) differences in spermatogenic function in contralateral testes.

Discussion

Prompt medical attention is crucial for testicular torsion as it interrupts testicular circulation. Delayed detorsion in testicular torsion increases the risk of testicular loss (Mostahsan et al. 2024a). The torsional testis can often be saved if corrected within six hours of symptom onset. A 95% testicular preservation rate is achievable with detorsion conducted within 4 hours

of torsion onset (Mao et al. 2025). When performed 8-10 hours after onset, detorsion yields testicular preservation rates of only 45%-60% (Mao et al. 2025). The rate of testicular atrophy after successful detorsion was observed to be 9.2%-41.29% (Wei et al. 2025, Delgado-Miguel et al. 2025). In our experimental model, testicular detorsion was performed in rats after maintaining left testicular torsion for 2 hours. After allowing three months for recovery post-detorsion, permanent testicular dysfunction was identified in the affected testis. We observed that the torsion-detorsion procedure resulted in diminished seminiferous epithelium stratification, smaller tubular diameters, decreased testicular weight, and lower Johnsen's histological scores (Figs. 3 and 4). Our results are in strong agreement with the findings of Zeynali et al. (2025) (Zeynali et al. 2025).

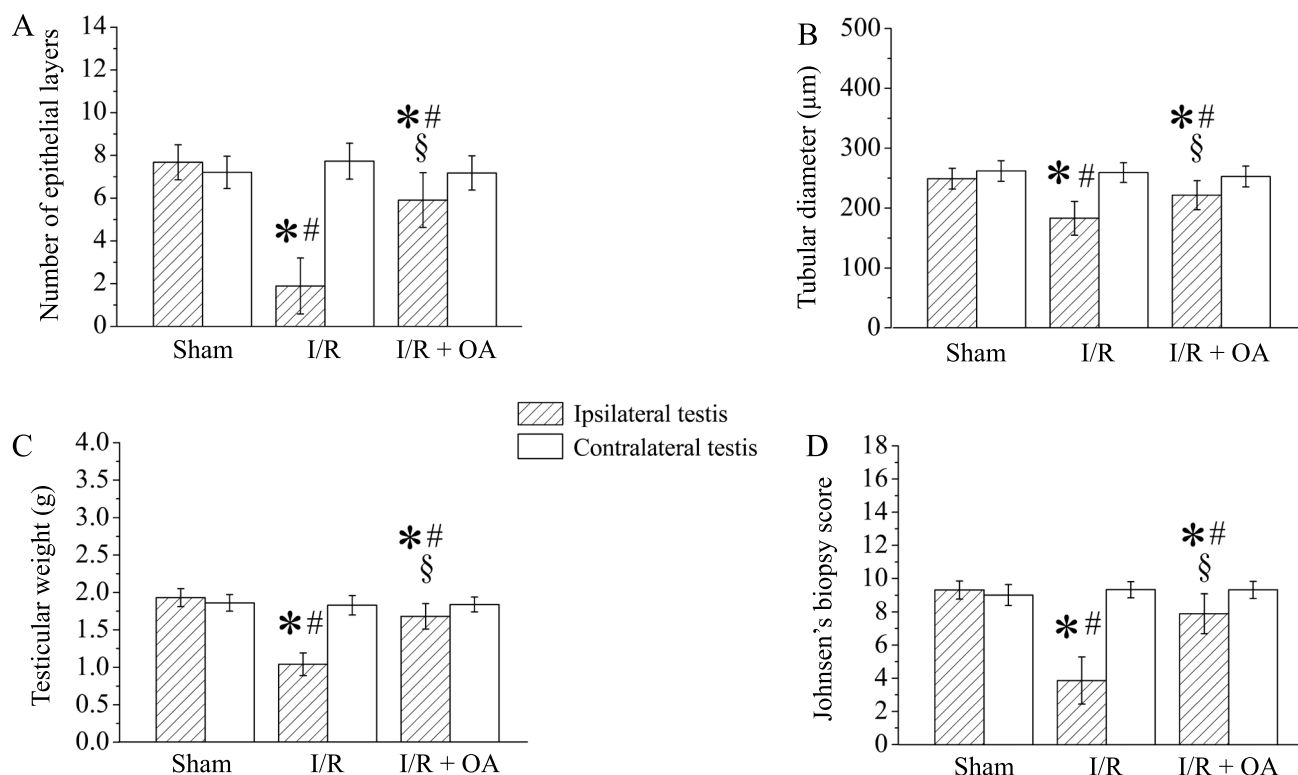


Fig. 3. Assessment of (A) number of epithelial layers in seminiferous tubule, (B) tubular diameter, (C) testicular weight, and (D) Johnsen's biopsy score in testicular tissues across experimental rat groups: sham, ischemia-reperfusion (I/R), and oleanolic acid (OA)-treated groups; $n=10$ each. The mean \pm standard deviation was used to present continuous variables. A one-way analysis of variance served as the method for comparing groups. Subsequent pairwise comparisons were carried out with the Student-Newman-Keuls test. For within-group comparisons, the t-test was applied to examine mean differences between ipsilateral and contralateral testes. * signified $p<0.05$ relative to sham group; § signified $p<0.05$ relative to ipsilateral testis in I/R group; # signified $p<0.05$ relative to contralateral testis within group.

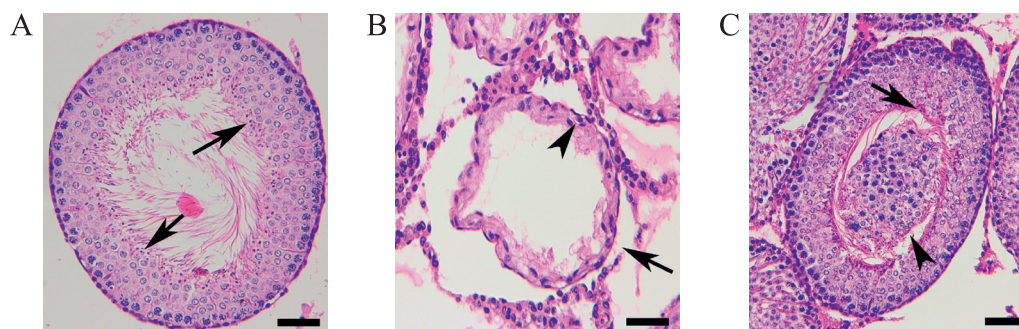


Fig. 4. Comparative histopathological analysis (hematoxylin-eosin staining) of testicular tissues from sham, ischemia-reperfusion, and oleanolic acid-treated rat groups. (A) Microscopic analysis demonstrated that both contralateral testes (all groups) and sham-operated ipsilateral testes exhibited: (1) abundant spermatozoa (indicated by \uparrow), (2) unobstructed tubular lumen, (3) well-preserved seminiferous tubule morphology, and (4) uncompromised epithelial layers. (B) Testicular ischemia-reperfusion caused ipsilateral testes to lack spermatozoa in tubular lumen. Furthermore, in ischemia-reperfusion group, seminiferous tubules (\uparrow) revealed atrophy, and epithelial layers (\blacktriangle) were reduced in number in ipsilateral testes. (C) In oleanolic acid-administered group, testicular tissue architecture appeared largely unaffected in ipsilateral side. Within seminiferous tubule's lumen, spermatozoa (\uparrow) were present. Yet, the lumen of the tubule was occupied by necrotic debris from shed epithelial layers (\blacktriangle). Detached epithelial layers frequently caused seminiferous tubule blockage. Micrograph taken at $200\times$ magnification; scale bar = $40\ \mu\text{m}$.

Reactive oxygen species overproduction serves as the mediator of testicular damage during torsion-detorsion (Wei and Huang 2024a). Excessive reactive oxygen species induce oxidative modifications in cellular proteins, DNA and lipids, which adversely affects

sperm production in the testes (Hu et al. 2025). The chemical nature of reactive oxygen species is highly unstable and ephemeral (Wei et al. 2022). As a result, accurate measurement of their concentrations remains problematic (Wei et al. 2022). Through the action

of reactive oxygen species, sperm membrane lipids undergo peroxidation, resulting in the formation of malondialdehyde as a stable terminal product (Refaie et al. 2025). Thus, malondialdehyde functions as an essential indicator in detecting reactive oxygen species (Gaber Ibrahim et al. in press). This study found that the ipsilateral testis displayed a sharp increase in malondialdehyde concentration following ischemia-reperfusion (Fig. 2). Our data echo the earlier work of Mohammadnejad et al. (2025a). Our results also showed that spermatogenic function was severely compromised in testicles affected by ischemia-reperfusion (Figs. 3 and 4). Our findings run parallel to those documented by Mostahsan et al. (2024b). The results indicate that germ cells suffer severe damage in testicular ischemia-reperfusion, primarily because of the buildup of excessive reactive oxygen species. Significantly, oleanolic acid treatment lowered malondialdehyde content (Fig. 2) and promoted germ cell recovery (Figs. 3 and 4) following testicular ischemia-reperfusion. The data demonstrate that oleanolic acid ameliorates ischemia/reperfusion-induced spermatogenic dysfunction by reducing reactive oxygen species. Oleanolic acid has proven clinically effective in addressing multiple medical conditions, including hyperlipidemia, type 2 diabetes, arthritis-induced pain, and inflammatory conditions (Lukaczer et al. 2005, Minich et al. 2007, Luo et al. 2018, Santos-Lozano et al. 2019). Oleanolic acid administration showed an excellent safety record in clinical settings, with no severe side effects reported (Lukaczer et al. 2005, Minich et al. 2007, Luo et al. 2018, Santos-Lozano et al. 2019). Our experimental data, in conjunction with clinical findings (Lukaczer et al. 2005, Minich et al. 2007, Luo et al. 2018, Santos-Lozano et al. 2019), indicate that oleanolic acid may possess therapeutic potential for improving spermatogenesis in cases of testicular ischemia-reperfusion damage. However, the underlying mechanisms of oleanolic acid's attenuation of reactive oxygen species remain inadequately explored.

In tissues subjected to ischemia-reperfusion, neutrophil-derived NADPH oxidase serves as an important source of reactive oxygen species (Matsushima and Sadoshima 2022). During the ischemic phase, the entry of calcium ions into neutrophils leads to intracellular NADPH oxidase activation (Dhalla et al. 2025). Upon reperfusion, oxygen is supplied to the ischemic region as blood flow resumes. Superoxide radical formation occurs when NADPH oxidase reduces oxygen (Kračun et al. 2025). Superoxide radicals react with each other to generate hydrogen peroxide (Karpinska and Foyer 2024). Through the Haber-Weiss reaction, hydrogen peroxide and superoxide radicals yield hydroxyl radicals (Méndez-Valdés et al. 2022, Teschke 2024).

Accordingly, reintroduction of blood flow to ischemic tissue triggers the production of reactive oxygen species. Our findings demonstrated that testicular ischemia-reperfusion resulted in substantially increased NADPH oxidase activity (Fig. 1) and malondialdehyde content (Fig. 2) in the affected testes, while simultaneously impairing spermatogenic capacity (Figs. 3 and 4). According to the data, NADPH oxidase activity rises due to ischemia-reperfusion, contributing to excessive reactive oxygen species production and, as a final consequence, compromises testicular spermatogenesis. Relative to the ischemia-reperfusion group, oleanolic acid intervention markedly decreased NADPH oxidase activity (Fig. 1) and malondialdehyde levels (Fig. 2) in ipsilateral testes, while significantly improving spermatogenic performance (Figs. 3 and 4). Our results imply that oleanolic acid protects testes from ischemia-reperfusion damage through its ability to lower NADPH oxidase activity and decrease oxidative stress.

Whether the contralateral testis incurs damage subsequent to unilateral testicular ischemia-reperfusion remains controversial. Several investigations reported the occurrence of notable histopathological alterations in the contralateral testis following unilateral testicular ischemia-reperfusion (Gaber Ibrahim et al. in press). Conversely, certain studies demonstrated preserved histopathological architecture in the contralateral testis under these conditions (Ghasemi et al. 2025). Our experimental data indicated that contralateral testicular parameters (including spermatogenic efficiency, malondialdehyde accumulation, and NADPH oxidase activity) remained no prominently changed following ipsilateral testicular ischemia-reperfusion compared to the sham group (Figs. 1-4). Our findings reveal no significant cross-effects of unilateral testicular ischemia-reperfusion on the contralateral testis.

According to research by Mdhluli and van der Horst (2002), the influence of oleanolic acid on the movement traits of sperm and subsequent reproductive capacity was examined in male Wistar rats (Mdhluli and van der Horst 2002). Following 30 days of oral treatment with an oleanolic acid-polyvinylpyrrolidone suspension, half of the adult male Wistar rats were subjected to a 14-day period without the drug. The control group was administered polyvinylpyrrolidone as the sole substance. The females used for mating, which received no treatment, were paired with all the available males. No females were impregnated by the treated males, while all those paired with control males or males taken off oleanolic acid became pregnant. The evidence from this research establishes that a one-month course of oleanolic acid is sufficient to cause temporary infertility in male Wistar rats, while normalization of testicular reproductive capacity is observed after a 14-day with-

drawal of oleanolic acid. The treatment regimen in our study consisted of a one-time dose of oleanolic acid to the rats. Spermatogenic capacity of the testes was examined 3 months after drug withdrawal. On the basis of data from Mdhuli and van der Horst (2002), testicular spermatogenic capacity remained free of any negative influence from oleanolic acid when examined 3 months post-withdrawal.

Following a 720° twist sustained for two hours, rat testes exhibit damage that does not progress to necrosis (Akhigbe et al. 2024). Accordingly, a duration of two hours for 720° testicular torsion was chosen in the rat model to study the influence of oleanolic acid on testicular damage caused by ischemia/reperfusion.

The power analysis, conducted with an alpha of 0.05, a power of 0.80, and an effect size of 1.74, indicated that a minimum of 10 subjects per group would be needed to observe a significant difference (Tasci et al. 2022). Hence, each subgroup in our study consisted of 10 participants.

A methodological limitation of our work is that it did not include spermatological analysis.

Conclusion

This study provides the first evidence that oleanolic acid ameliorates testicular ischemia/reperfusion-induced spermatogenic dysfunction by suppressing NADPH oxidase-mediated reactive oxygen species production. Such observations demonstrate that oleanolic acid possesses clinical value as a potential treatment for ischemia-reperfusion injury in the testis. Accordingly, future research involving human subjects will aim to determine oleanolic acid's clinical benefits.

Acknowledgments

This study was supported by the Zhejiang Provincial Natural Science Foundation of China under Grant No. LY19H040001.

Author Declarations

Ethics approval

Ethical clearance for all animal experiments was granted by Zhejiang Shuren University Ethics Committee (Protocol ID: 202401051).

Use of generative artificial intelligence

No generative artificial intelligence tools were used in the preparation of the manuscript.

Conflict of interest

No conflict of interest.

References

- Akhigbe RE, Odetayo AF, Akhigbe TM, Hamed MA, Ashonibare PJ (2024) Pathophysiology and management of testicular ischemia/reperfusion injury: Lessons from animal models. *Heliyon* 10: e27760.
- Anderson E, Chaplin WJ, Turner C, Johnson GD, Blake H, Tabner A (2025) Experiences and perceptions of acute testicular pain, with a focus on reasons for delayed presentation to hospital: a qualitative evidence synthesis. *Emerg Med J* 42: 264-270.
- Cai SC, Li XP, Li X, Tang GY, Yi LM, Hu XS (2021) Oleanolic acid inhibits neuronal pyroptosis in ischaemic stroke by inhibiting miR-186-5p expression. *Exp Neurobiol* 30: 401-414.
- Chen Q, Xiao D, Wang Y, Zhang Z, Lin X, Ji Q, Han Y, Yu L, Xu J (2025) Neutrophil-mimetic oleanolic acid-loaded liposomes targeted to alleviate oxidative stress for renal ischemia-reperfusion injury treatment. *Int J Pharm X* 9: 100344.
- Delgado-Miguel C, Arredondo-Montero J, Moreno-Alfonso JC, Garavis Montagut I, San Basilio M, Hernández I, Carrera N, Martínez L, Iraola E, Ruiz Jiménez I, Aguado Roncero P, Fuentes E, Díez R, Hernández-Oliveros F (2025) The role of neutrophil-to-lymphocyte ratio as a predictor of orchietomy or testicular atrophy after torsion in children: a multicentric study. *J Pers Med* 15: 310.
- Dhalla NS, Ostadal P, Tappia PS (2025) Involvement of oxidative stress and antioxidants in modification of cardiac dysfunction due to ischemia-reperfusion injury. *Antioxidants (Basel)* 14: 340.
- Du Y, Ko KM (2006) Oleanolic acid protects against myocardial ischemia-reperfusion injury by enhancing mitochondrial antioxidant mechanism mediated by glutathione and alpha-tocopherol in rats. *Planta Med* 72: 222-227.
- Gaber Ibrahim MF, Abdel-Hakeem EA, Shawky HA, Abdelkawy Abdelwahab S, Mokhmer SA (2026) Effect of local versus systemic exosomes administration on both testes in rat model of testicular ischemic reperfusion injury: shedding light on blood testis barrier. *Tissue Barriers* 14: 2532195.
- Ghasemi M, Basiri A, Mohammad Jafari R, Shafaroodi H, Tavangar SM, Mohammadi Hamaneh A, Dehpour AR (2025) Protective effects of lithium against testicular ischemia-reperfusion injury: Involvement of the Akt/GSK-3 β pathway. *J Pediatr Urol* 21: 558-566.
- Hao BB, Pan XX, Fan Y, Lu L, Qian XF, Wang XH, Zhang F, Rao JH (2016) Oleanolic acid attenuates liver ischemia reperfusion injury by HO-1/Sesn2 signaling pathway. *Hepatobiliary Pancreat Dis Int* 15: 519-524.
- Hu Z, Wang J, Ning J, Cheng F (2025) Curcumin mitigates testicular ischemia-reperfusion injury by suppressing NLRP3-mediated pyroptosis. *Mol Immunol* 185: 71-80.
- Izanloo H, Soleimanzadeh A, Bucak MN, Imani M, Zhandi M (2021) The effects of varying concentrations of glutathione and trehalose in improving microscopic and oxidative stress parameters in Turkey semen during liquid storage at 5°C. *Cryobiology* 101: 12-19.

- Johnsen SG (1970) Testicular biopsy score count – a method for registration of spermatogenesis in human testes: normal values and results in 335 hypogonadal males. *Hormones* 1: 2-25.
- Karpinska B, Foyer CH (2024) Superoxide signalling and antioxidant processing in the plant nucleus. *J Exp Bot* 75: 4599-4610.
- Kračun D, Lopes LR, Cifuentes-Pagano E, Pagano PJ (2025) NADPH oxidases: redox regulation of cell homeostasis and disease. *Physiol Rev* 105: 1291-1428.
- Lukacz D, Darland G, Tripp M, Liska D, Lerman RH, Schiltz B, Bland JS (2005) A pilot trial evaluating Meta050, a proprietary combination of reduced iso-alpha acids, rosemary extract and oleanolic acid in patients with arthritis and fibromyalgia. *Phytother Res* 19: 864-869.
- Luo HQ, Shen J, Chen CP, Ma X, Lin C, Ouyang Q, Xuan CX, Liu J, Sun HB, Liu J (2018) Lipid-lowering effects of oleanolic acid in hyperlipidemic patients. *Chin J Nat Med* 16: 339-346.
- Mao C, Yang C, Zhong H, Deng Q, Zhang T, Chu H, Shen J, Cao Y (2025) Development of a nomogram to predict risk factors for orchiectomy after testicular torsion in children. *Sci Rep* 15: 15154.
- Matsushima S, Sadoshima J (2022) Yin and Yang of NADPH oxidases in myocardial ischemia-reperfusion. *Antioxidants (Basel)* 11: 1069.
- Mdhului MC, van der Horst G (2002) The effect of oleanolic acid on sperm motion characteristics and fertility of male Wistar rats. *Lab Anim* 36: 432-437.
- Méndez-Valdés G, Pérez-Carreño V, Bragato MC, Hundahl M, Chichiarelli S, Saso L, Rodrigo R (2022) Cardioprotective mechanisms against reperfusion injury in acute myocardial infarction: targeting angiotensin II receptors. *Biomedicines* 11: 17.
- Minich DM, Bland JS, Katke J, Darland G, Hall A, Lerman RH, Lamb J, Carroll B, Tripp M (2007) Clinical safety and efficacy of NG440: a novel combination of rho iso-alpha acids from hops, rosemary, and oleanolic acid for inflammatory conditions. *Can J Physiol Pharmacol* 85: 872-883.
- Mohammadnejad K, Mohammadi R, Soleimanzadeh A, Shalzar-Jalali A, Sarrafzadeh-Rezaei F (2025a) Provitamin A carotenoid (β -cryptoxanthin) ameliorated testicular ischemia-reperfusion injury in mature rats. *Vet Res Forum* 16: 277-284.
- Mohammadnejad K, Mohammadi R, Soleimanzadeh A, Shalzar-Jalali A, Sarrafzadeh-Rezaei F (2025b) The effect of β -cryptoxanthin on testicular ischemia-reperfusion injury in a rat model: evidence from testicular histology. *Iran J Vet Surg* 20: 110-115.
- Mostahsan Z, Azizi S, Soleimanzadeh A, Shalzar-Jalali A (2024a) Protective effects of Mito-TEMPO on ischemia-reperfusion injury in a mouse testicular torsion and detorsion model. *Vet Res Forum* 15: 665-672.
- Mostahsan Z, Azizi S, Soleimanzadeh A, Shalzar-Jalali A (2024b) The protective roles of Mito-TEMPO on testicular ischemia-reperfusion injury based on biochemical and histopathological evidences in mice. *Iran J Vet Surg* 19: 97-105.
- Pi Y, Zuo H, Wang Y, Zheng W, Zhou H, Deng L, Song H (2024) Oleanolic acid alleviating ischemia-reperfusion injury in rat severe steatotic liver via KEAP1/NRF2/ARE. *Int Immunopharmacol* 138: 112617.
- Refaie MM, Abdel-Hakeem EA, Ahmed Ibrahim R, Hassan Mohamed Z, Shehata S, Soltan Shrekawy El Bakry H, Ali DM (2025) Role of sacubitril/valsartan in testicular ischaemia reperfusion injury via modulation of AngII/ASK/NF- κ B and JAK/STAT pathways in juvenile rats. *Br J Pharmacol* 182: 4343-4362.
- Santos-Lozano JM, Rada M, Lapetra J, Guinda Á, Jiménez-Rodríguez MC, Cayuela JA, Ángel-Lugo A, Vilches-Arenas Á, Gómez-Martín AM, Ortega-Calvo M, Castellano JM (2019) Prevention of type 2 diabetes in pre-diabetic patients by using functional olive oil enriched in oleanolic acid: The PREDIABOLE study, a randomized controlled trial. *Diabetes Obes Metab* 21: 2526-2534.
- Sapkota A, Choi JW (2022) Oleanolic acid provides neuroprotection against ischemic stroke through the inhibition of microglial activation and NLRP3 inflammasome activation. *Biomol Ther (Seoul)* 30: 55-63.
- Shakouri N, Soleimanzadeh A, Rakhshanpour A, Bucak MN (2021) Antioxidant effects of supplementation of 3,4-dihydroxyphenyl glycol on sperm parameters and oxidative markers following cryopreservation in canine semen. *Reprod Domest Anim* 56: 1004-1014.
- Soleimanzadeh A, Karvani N, Davoodi F, Molaie R, Raisi A (2024) Efficacy of silver-doped carbon dots in chemical castration: a rat model study. *Sci Rep* 14:24132.
- Tasci A, Uguralp S, Akatli AN, Arslan AK, Karabulut AB (2022) Long-term effects of orchiopexy and orchiectomy on the testes of rats with testicular torsion. *J Pediatr Urol* 18: 376.e1-376.e7.
- Teschke R (2024) Hemochromatosis: Ferroptosis, ROS, gut microbiome, and clinical challenges with alcohol as confounding variable. *Int J Mol Sci* 25: 2668.
- Wang W, Wu L, Li J, Ji J, Chen K, Yu Q, Li S, Feng J, Liu T, Zhang J, Chen J, Zhou Y, Mao Y, Wang F, Dai W, Fan X, Guo C, Wu J (2019) Alleviation of hepatic ischemia reperfusion injury by oleanolic acid pretreating via reducing HMGB1 release and inhibiting apoptosis and autophagy. *Mediators Inflamm* 2019: 3240713.
- Wei J, Li Z, Wei Y, Tang D, Bai G, Men L, Wu S, Yan X (2025) Development and validation of a predictive model for testicular atrophy after orchiopexy in children with testicular torsion. *World J Emerg Med* 16: 387-391.
- Wei SM, Huang YM (2024a) Effect of sulforaphane on testicular ischemia-reperfusion injury induced by testicular torsion-detorsion in rats. *Sci Rep* 14: 23420.
- Wei SM, Huang YM (2024b) Safranal ameliorates testicular ischemia-reperfusion injury in testicular torsion-detorsion rat model. *Rev Int Androl* 22: 33-41.
- Wei SM, Huang YM, Qin ZQ (2022) Salidroside exerts beneficial effect on testicular ischemia-reperfusion injury in rats. *Oxid Med Cell Longev* 2022: 8069152.
- Yang J, Li X, Yang H, Long C (2021) Oleanolic acid improves the symptom of renal ischemia reperfusion injury via the PI3K/AKT pathway. *Urol Int* 105: 215-220.
- Yildizhan E, Akkus M, Ülger BV, Asır F, Söker S, Gündüz E, Rençber M, Barçın M (2023) Protective effectiveness of anise against testicular ischemia and reperfusion injury: an experimental study in rats. *Pol J Vet Sci* 26: 249-255.
- Zeynali E, Soleimanzadeh A, Azizi S (2025) Synergistic protection of alpha-glucosyl hesperidin and procyanidin against testicular ischemia-reperfusion injury. *J Food Biochem* 2025: 5634210.
- Zolfaghari S, Soleimanzadeh A, Baqerkhani M (2025) The synergistic activity of fisetin on quercetin improves testicular recover in ischemia-reperfusion injury in rats. *Sci Rep* 15: 12053.