

TOMASZ ISKRA, EWA MIZIA, AGATA MUSIAŁ, ALEKSANDRA MATUSZYK,  
KRZYSZTOF A. TOMASZEWSKI

## CARPAL TUNNEL SYNDROME — ANATOMICAL AND CLINICAL CORRELATIONS

**Abstract:** Carpal tunnel syndrome (CTS) is the most common and widely known of the entrapment neuropathies in which the body's peripheral nerves are compressed. Common symptoms of CTS involve the hand and result from compression of the median nerve within the carpal tunnel. In general, CTS develops when the tissues around the median nerve irritate or compress on the nerve along its course through the carpal tunnel, however often it is very difficult to determine cause of CTS. Proper treatment (conservative or surgical) usually can relieve the symptoms and restore normal use of the wrist and hand.

**Key words:** carpal tunnel syndrome, entrapment neuropathy, median nerve.

### DEFINITION

Carpal tunnel syndrome (CTS) is the most common and widely known of the entrapment neuropathies in which the body's peripheral nerves are compressed [1, 2]. Common symptoms of CTS involve the hand (numbness, pain and, eventually, hand weakness) and result from compression of the median nerve within the carpal tunnel. The median nerve controls sensations to the palm side of the thumb and fingers (except for the little finger), as well as impulses to some muscles in the hand that move the thumb and fingers. The carpal tunnel — a narrow passageway of ligament and bones at the base of the wrist — contains the median nerve and tendons. Numerous factors can cause CTS, including the anatomy of wrist, certain health problems and overloading of hand. Proper treatment usually can relieve the symptoms and restore normal function of the hand.

### ANATOMY

Median nerve is formed by the union of the lateral and medial roots which originate from the lateral and medial cord of the brachial plexus, respectively (on the anterior surface of the axillary artery). It runs down the anteromedial aspect

of the arm in the medial bicipital groove first lateral to the brachial artery, then in the middle of the upper arm the median nerve crosses the artery in front and lies on its medial side (has no muscular branches in the arm). Then passes through the cubital fossa, deep to the bicipital aponeurosis and medial to the brachial artery. In the cubital fossa gives rise to the anterior interosseous nerve, which descends on the interosseous membrane between the flexor digitorum profundus and flexor pollicis longus, and then passes behind the pronator quadratus supplying these three muscles. enters the forearm between the humeral and ulnar heads of the pronator teres muscle and then passes between the flexor digitorum superficialis and the flexor digitorum profundus muscles. In the lower third of the forearm median nerve is located superficially, covered only by the fascia and partly by the tendon of the palmaris longus muscle.

Then median nerve enters the palm of the hand through the carpal tunnel deep to the flexor retinaculum. In the palm of the hand median nerve gives off a muscular branches to the thenar muscles (the abductor pollicis brevis muscle, the opponens pollicis muscle and superficial head of the flexor pollicis brevis muscle) and to the lateral two lumbricals, then terminates by dividing into three common palmar digital nerves, which then divide into the palmar digital branches innervating the skin of the lateral side of the palm, and the palmar side of the index finger, middle finger, and one-half of the ring finger.

There are several anatomic variations in the branching pattern of the median nerve in the forearm and hand, and its communications with various nerves [3–13]. Poisel [3] examined the hands of 100 cadavers and devised a classification system for median nerve variations and the relationship of the branches to the transverse carpal ligament. He described the following three types: extraligamentous (type I), subligamentous (type II), and transligamentous (type III). Lanz [4] recorded a detailed anatomical study of the course of the median nerve in 246 hands during various surgical explorations. The variations can be classified into four types:

- type I — variations of the course of the single thenar branch;
  - type II — accessory branches at the distal carpal tunnel;
  - type III — high division of the median nerve;
  - type IV — accessory branches proximal to the carpal tunnel.
- 1: Usual branching of the median nerve.
  - 2: Thenar branch leaving the median nerve within the carpal tunnel (subligamentous).
  - 3: Transligamentous course of thenar branch.
  - 4: Thenar branch leaving median nerve at its ulnar aspect.
  - 5: Thenar branch crosses over the top of the transverse carpal ligament.
  - 6: Doubled thenar motor branch.
  - 7: High division of the median nerve with a persistent median artery between the two parts.

8: High division of the median nerve with a thinner ulnar part.

9: High division of the median nerve with a thicker ulnar part.

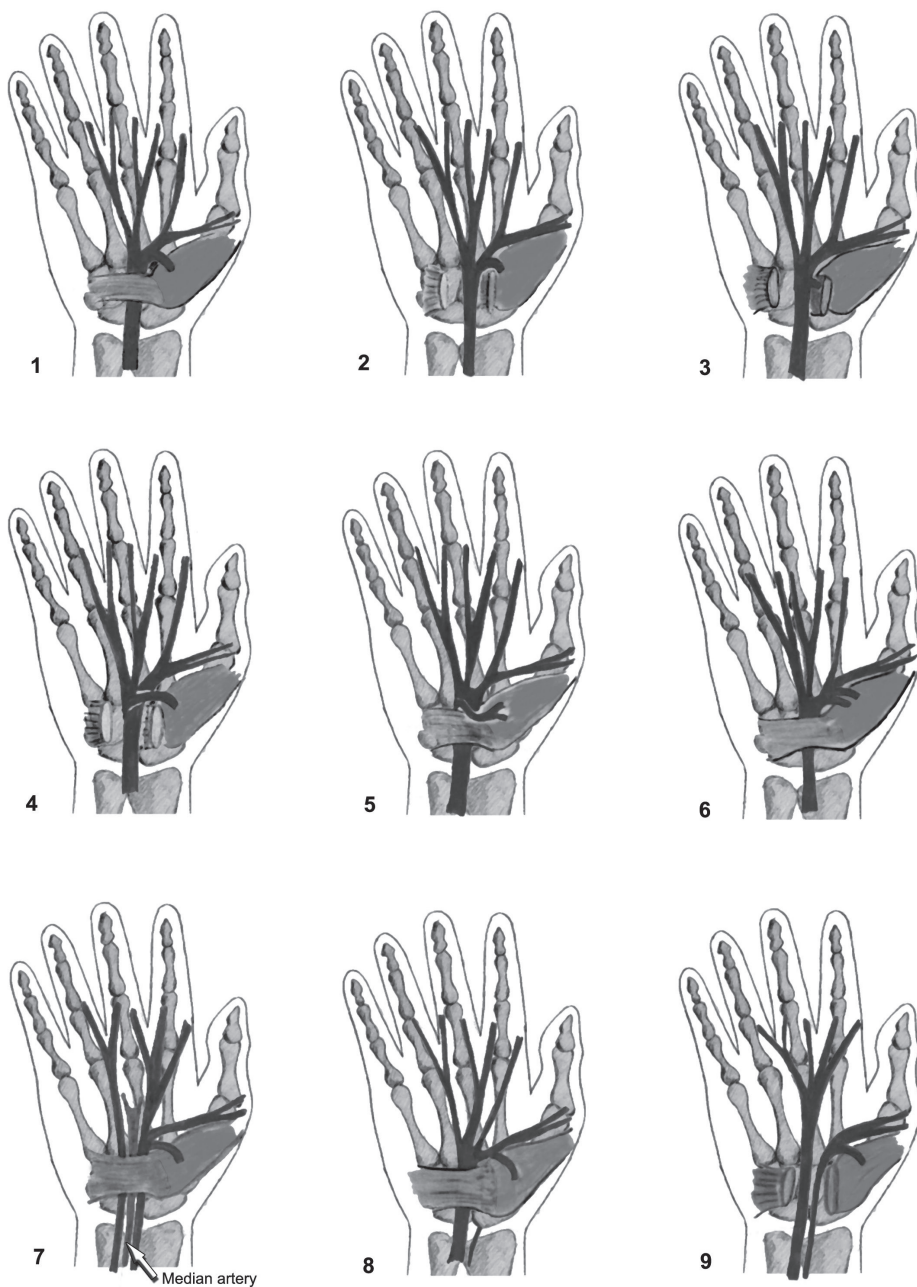


Fig. 1. Redrawn from Lanz, U. Anatomical variations of the median nerve in the carpal tunnel. *J. Hand Surg.* 1977, 2: 44-53.

Barbe *et al.* [5] examined 89 cadaveric forearm-hand hands to determine the frequency of anomalous structures within the carpal tunnels. Twenty-nine percent of all hands examined had two to five anomalies/variations per tunnel, whereas another 27% had one anomaly or variation per tunnel.

Carpal tunnel is a narrow passageway located on the palm side of the wrist. This tunnel protects a median nerve and nine tendons that bend the fingers. This canal is formed anteriorly by the flexor retinaculum and posteriorly by the anterior or palmar surface of the carpus which is convex and is called the carpal sulcus. This sulcus is bounded laterally by the radial carpal eminence formed by the tubercles of the scaphoid and trapezium bones and medially by the ulnar carpal eminence consisting of the pisiform bone and the hook of the hamate bone. Structures inside the carpal tunnel include the median nerve, and one tendon of flexor pollicis longus, four tendons of flexor digitorum profundus and four tendons of flexor digitorum superficialis muscles.

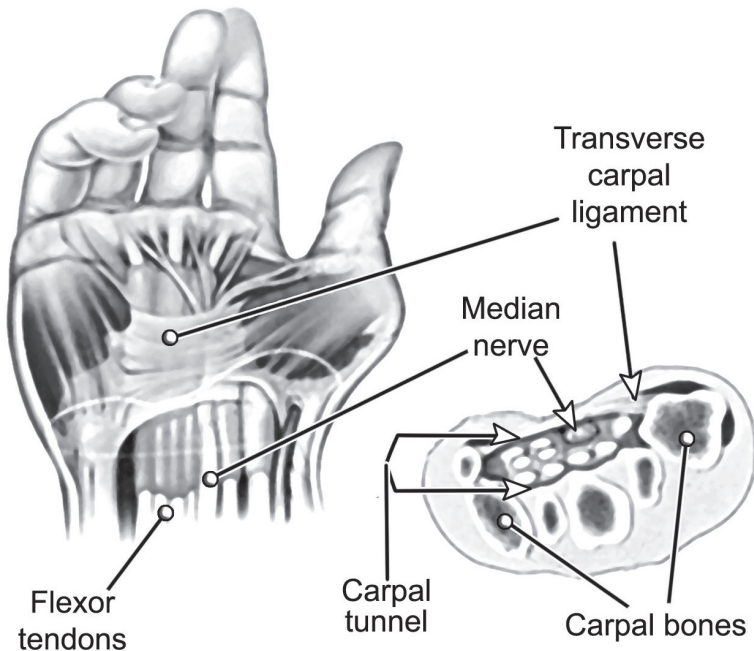


Fig. 2. Carpal tunnel.

## SYMPTOMS

The symptoms of CTS can range from mild to incapacitating and usually progress gradually over weeks and months, or sometimes years. Initially they come and go, but over time they may become constant. In the early stages of CTS, the

patient usually reports pain, numbness, tingling, burning, or some combination of symptoms on the palm side of the thumb, index, middle, and ring fingers (but not the little finger) (Fig. 3). Such sensations may travel up to the forearm or shoulder. Symptoms may occur at any time. Because many people sleep with flexed wrists, symptoms at night are common and may awaken from sleep. During the day, symptoms frequently occur when holding something, like a steering wheel, phone or newspaper. Moving or shaking the hands often relieve symptoms. Over time, the hand may become numb, and patients may lose the ability to feel and may experience sense of weakness in the hand and a tendency to drop objects. If the condition is very severe, muscles at the base of the thumb start to atrophy.

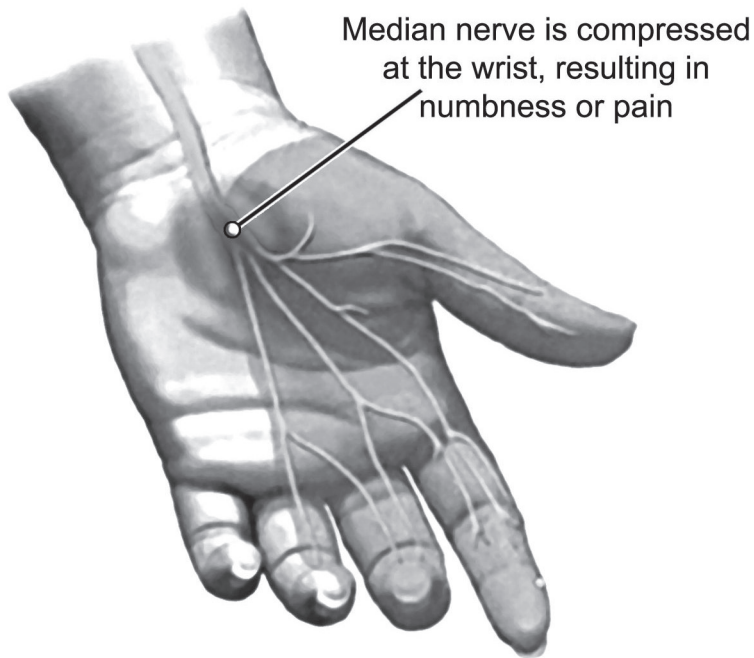


Fig. 3. The area of sensory symptoms in the CTS.

### CAUSES AND RISK FACTORS

In general, CTS develops when the tissues around the median nerve irritate or compress on the nerve along its course through the carpal tunnel. For example, a wrist fracture or swelling of tissue resulting from arthritis or tendonitis can narrow the carpal tunnel and irritate the nerve. In many cases, no single cause can be identified and a combination of risk factors contributes to the development of the CTS. In all probability this condition is owing to a congenital predispo-

sition — the carpal tunnel is narrower in some people than in others [14]. For this reason CTS is also more common in women. Other contributing factors include:

- injury to the wrist (fracture or dislocation), a cyst or tumour in the carpal tunnel compressing on the nerve
- inflammation can affect the tendons or bursa in the carpal tunnel, exerting pressure on median nerve
- disorders that directly affect the nerves and make them more susceptible to compression diabetes, overactivity of the pituitary gland, hypothyroidism, alcoholism. CTS is the most common complication of dialysis-related amyloidosis (DRA) developing in patients on long-term dialysis therapy [15]
- fluid retention (during pregnancy or menopause) may increase the pressure within carpal tunnel, irritating the median nerve
- workplace factors like repeated use of vibrating hand tools or working on an assembly line that requires prolonged or repetitive flexing of the wrist
- it is often very difficult to determine the precise cause of CTS

## TESTS AND DIAGNOSIS

Doctor can use specific tests to try to produce the symptoms of CTS [16]. In the Tinel test, the doctor taps on the median nerve in the patient's wrist. The test is positive when tingling in the fingers occurs. In the Phalen, or wrist-flexion, pressure on the median nerve at the wrist, is produced by bending the patient's wrist. The presence of CTS is suggested if tingling or increasing numbness, is felt in the fingers within 1 minute. If the test lasts for more than a minute, even patients without CTS may develop symptoms. Often it is necessary to use the electrophysiological tests: nerve conduction and less frequently electromyography [17]. Electrodiagnostic tests should be used if clinical or provocative tests are positive and the patient is considering surgery. These tests are the best methods for confirming a diagnosis of CTS. Nerve conduction may show if electrical impulses are slowed in the carpal tunnel. Electromyography determine if muscle damage has occurred. X-ray of the affected wrist can help to exclude other causes of wrist pain, such as arthritis or a fracture. Ultrasound imaging can show impaired movement of the median nerve [18]. Magnetic resonance imaging (MRI) can precisely show the anatomy of the wrist.

## TREATMENTS AND DRUGS

To avoid permanent damage to the median nerve treatments for CTS should begin as early as possible. Non-surgical (conservative) treatment including resting the affected hand and wrist for at least 2 weeks, wrist splinting, stretching

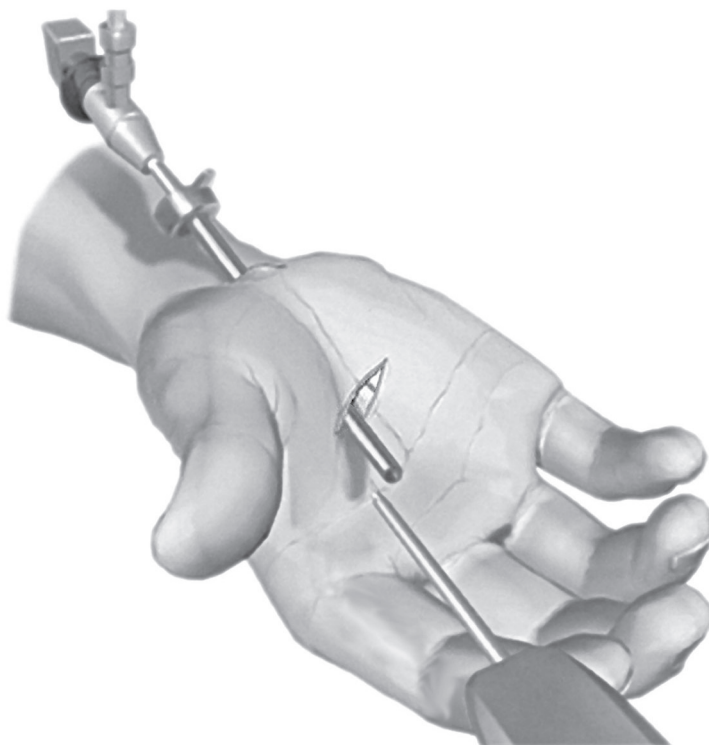


Fig. 4. Endoscopically assisted carpal tunnel release (ECTR).

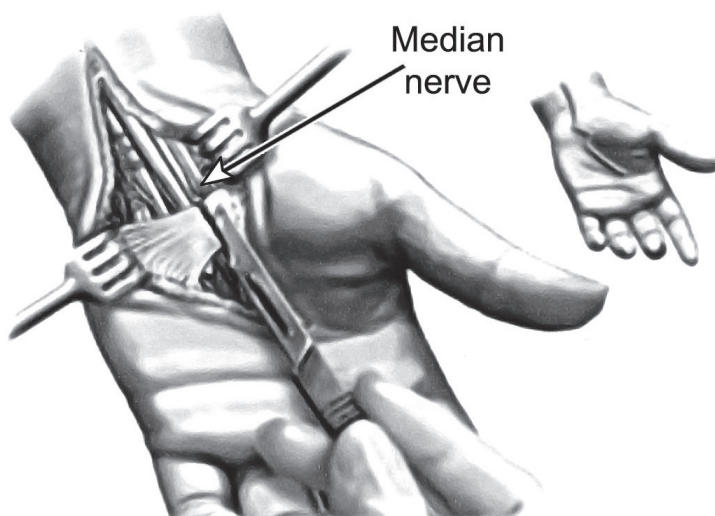


Fig. 5. Open carpal tunnel release (OCTR) – transverse carpal ligament released.



and strengthening exercises and drugs (nonsteroidal anti-inflammatory drugs, corticosteroids, diuretics, vitamin B) is the first step in treating this disorder [19–21]. Surgery is usually an effective treatment choice for people with severe symptoms of CTS who fail conservative treatment. Generally surgical treatment is recommended if symptoms last for 6 months. The surgery may be done in two ways: endoscopic surgery or the traditional procedure — open surgery [22]. Verdugo *et al.* [21] in a systematic review including 2 clinical trials reported that surgery resulted in better symptom relief than nonsurgical management. Fortunately, for most people who develop CTS, proper treatment usually can relieve the symptoms and restore normal use of the wrist and hand.

## REFERENCES

1. Bland J.D.P.: Carpal tunnel syndrome. *BMJ*. 2007; 335: 343–346. — 2. de Krom M.C., Knipschild P.G., Kester A.D., Thijs C.T., Boekkooi P.F., Spaans F.: Carpal tunnel syndrome: prevalence in the general population. *J. Clin. Epidemiol.* 1992; 45: 373–376. — 3. Poisel S.: Ursprung und Verlauf des Ramus muscularis des Nervus digitalis palmaris communis I (N. medianus). *Chir Praxis*. 1974; 18: 471–474. — 4. Lanz U.: Anatomical variations of the median nerve in the carpal tunnel. *J. Hand Surg Am.* 1977; 2(1): 44–53. — 5. Barbe M., Bradfield J., Donathan M., Elmaleh J.: Coexistence of multiple anomalies in the carpal tunnel. *Clin Anat.* 2005; 18: 251–259. — 6. Tountas C.P., Bhrle D.M., MacDonald C.J., Bergman R.A.: Variations of the median nerve in the carpal. *J Hand Surg.* 1987; 12: 708–712. — 7. Hurwitz P.J.: Variation in the course of the thenar motor branch of the median nerve. *J. Hand Surg.* 1996; 21B: 344–346. — 8. Kozin S.H.: The anatomy of the recurrent branch of the median nerve. *J. Hand. Surg.* 1998; 23A: 852–858. — 9. Cavallo A.V., Slattery P.G., Barton R.J.: Endoscopic carpal tunnel release and congenital anomalies of the median nerve. *Hand Surg.* 2003; 8(2): 265–270. — 10. Mizia E., Klimek-Piotrowska W, Walocha J., Rutowski R., Wojtala R.: The median nerve in the carpal tunnel. *Folia Morphol.* 2011; 70(1): 41–46.
11. Mizia E., Gziut T., Kruk S., Golec E., Walocha J.: Anomalous course of thenar motor branch of the median nerve — a case report. *Kwart Ortop.* 2012; 2: 270–273. — 12. Mizia E., Tomaszewski K.A., Goncerz G., Depukat P., Walocha J.: The importance of ulnar side approach in carpal tunnel syndrome surgical treatment — anatomic variations of the median nerve and surrounding structures. *J Orthop Trauma Surg Rel Res.* 2012; 4: 19–24. — 13. Mizia E., Tomaszewski K A., Goncerz G., Kurzydło W., Walocha J.: Median nerve thenar motor branch anatomical variations. *Folia Morphol.* 2012; 71(3): 183–186. — 14. Hakim A.J., Cherkas L., El Zayat S., MacGregor A.J., Spector T.D.: The genetic contribution to carpal tunnel syndrome in women: a twin study. *Arthritis Rheum.* 2002; 47: 275–279. — 15. Kopeć J., Gadek A., Drożdż M., Miśkowiec K., Dutka J., Sydor A., Chowaniec E., Sułowicz W.: Carpal tunnel syndrome in hemodialysis patients as a dialysis-related amyloidosis manifestation-incidence, risk factors and results of surgical treatment. *Med Sci Monit.* 2011; 17(9): CR505–509. — 16. Mondelli M., Passero S., Giannini F.: Provocative tests in different stages of carpal tunnel syndrome. *Clin Neurol Neurosurg.* 2001; 103: 178–183. — 17. Jablecki C.K., Andary M.T., Floeter M.K., Miller R.G., Quartly C.A., Vennix M.J., Wilson J.R.: Practice parameter: electrodiagnostic studies in carpal tunnel syndrome. *Neurology* 2002; 58: 1589–1592. — 18. Wong S.M., Griffith J.F., Hui A.C.F., Lo S.K., Fu M., Wong K.S.: Carpal tunnel syndrome: diagnostic usefulness of sonography. *Radiology* 2004; 232(1): 93–99. — 19. Cook A.C., Szabo R.M., Birkholz S.W., King E.F.: Early mobilization following carpal tunnel release. A prospective randomized study. *J Hand Surg [Br].* 1995; 20: 228–230. — 20. Katz J.N., Simmons B.P.: Carpal Tunnel Syndrome. *N. Engl J Med.* 2002; 346 (23): 1807–1812.



**21.** Verdugo R.J., Salinas R.S., Castillo J., Cea J.G.: Surgical versus non-surgical treatment for carpal tunnel syndrome. Cochrane Database Syst Rev. 2003 (3): CD001552. — **22.** Wong K.C., Hung LK., Ho P.C., Wong J.M.: Carpal tunnel release. A prospective, randomised study of endoscopic versus limited-open methods. J Bone Joint Surg Br. 2003; 85: 863–868.

Department of Anatomy  
Jagiellonian University Medical College  
ul. Kopernika 12, 31-034 Kraków, Poland  
*Head: prof. Jerzy Walocha MD, PhD*

**Corresponding author:**  
Tomasz Iskra MD, PhD  
Department of Anatomy  
Jagiellonian University Medical College  
ul. Kopernika 12, 31-034 Kraków, Poland  
Phone/Fax: +48 12 422 95 11  
E-mail: tomasz.iskra@uj.edu.pl

