

# Application of the temporal bone for sex determination from the skeletal remains

MAGDALENA KOZERSKA, JANUSZ SKRZAT, ANITA SZCZEPANEK

Department of Anatomy, Jagiellonian University, Collegium Medicum  
ul. Kopernika 12, 31-034 Kraków, Poland

**Corresponding author:** Dr hab. Janusz Skrzat, Department of Anatomy, Jagiellonian University Collegium Medicum  
ul. Kopernika 12, 31-034 Kraków, Poland; Phone/Fax: +48 12 422 95 11; E-mail: jskrzat@poczta.onet.pl

**Abstract:** This paper presents state of current knowledge on possibilities and accuracy of sex determination from the temporal bone. Experimental and comparative studies performed on temporal bones derived from different human populations allowed to verify to what extent this bone is valuable source of information on sex of individual. It was figured out that the temporal bone can be used for this purpose and the size of the mastoid process is considered to be one of the best sex discriminator.

**Key words:** sex determination, temporal bone, craniometry.

## Introduction

The anatomical features of the human skulls used in sex determination are related basically with morphology of the following bones: frontal (setting of the squama, eyebrows protuberance, sharpness of the supraorbital edge), zygomatic (the presence of the tuberculum marginale on the frontal process), temporal (size of the mastoid process, the width of the zygomatic process, presence of the supramastoid crest), occipital (degree of corrugation of the occipital squama), mandible (degree of chin protuberance) [1–4]. Also the palatine bones were used for this purpose with reference to the dimensions of the hard palate [5].

The ability to correctly identify sex only from the skull is possible in 80% of cases, but presence of well-preserved mandible rises it to 90% [6]. Some of the mentioned morphological features vary among the ancestral groups, and therefore the identification of a single skull of unknown origin just by observing these features is not always completely reliable [3].

Analysis of the anatomical dimorphic features of the human skulls enable to invent methods which enhanced precision of sexing. Various methods of sex identification (morphological and metrical) are widely used by physical as well as forensic anthropologists.

Morphological features which differentiate sex are usually scored according to grade scale, where extreme values are regarded as markers of male or female sex and intermediate value indicates on undeterminable sex [7, 8]. Particularly, the petrous part of the temporal bone plays a significant role because of compact structure which makes the bone resistant to mechanical loads and other destructive factors (eg. high temperature). These features of the temporal bone enables sexing skeletons even after cremation [9, 10].

### Morphology of the temporal bone

The temporal bone is incorporated into the lateral wall of the skull and and the cranial base. This bone reveals the most complex anatomy from all cranial bones. The temporal bone is composed of four main parts: the squamous, tympanic, petrous, mastoid (Fig. 1). Commonly for the petrous and the mastoid part term the petromastoid part is also widely used. Hence, the zygomatic and styloid processes projecting outwards are constant components of the temporal bone. Each part is distinct from the others varying in size and shape what is partially caused by the sexual dimorphism in human population.

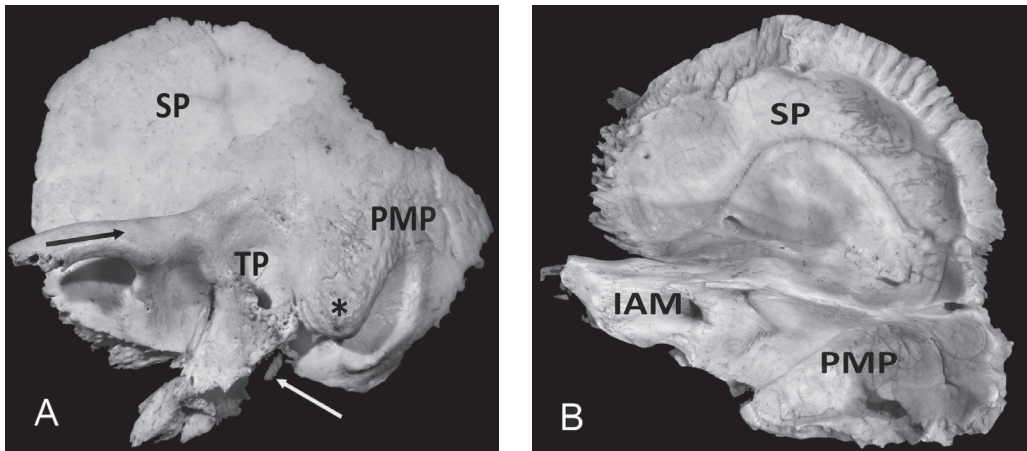


Fig. 1. Lateral view (A) and medial view (B) of the temporal bone; SP — the squamous part; TP — tympanic part; PMP — petromastoid part; IAM — internal acoustic meatus; zygomatic process (black arrow); styloid process (white arrow); asterisk — mastoid process.

The squamous part which is also known as the squama temporalis, is the largest part of the temporal bone. It is flat plate, located superiorly. The outer surface of the squamous bone is moderately convex and covered by the temporal muscle (Fig. 1A).

The tympanic part of the temporal bone is located inferiorly to the squamous, and anteriorly to the petromastoid part. Lateral portion of the tympanic part surrounds the external acoustic opening leading to external acoustic meatus (Fig. 1A).

The petrous part has pyramidal shape and it is directed medially, forward, and a little upward (Fig. 1B). This part of the temporal bone contains the middle and inner ear. Near the center is located the arcuate eminence, an anatomical and surgical landmark that identifies the location of the superior semicircular canal. Anterior and lateral to the eminence, is the thin layer of bone termed as the tegmen tympani which separates the tympanic cavity of the middle ear from the middle cranial fossa. The petrous portion of the temporal bone has natural openings: the internal acoustic meatus, the subarcuate fossa, the vestibular aqueduct and the cochlear aqueduct.

The mastoid part forms posterior portion of the temporal bone and it is located behind the tympanic part. This part includes the mastoid process, situated the most inferiorly and palpable just behind the ear. It is a site of attachment for many muscles, such as the sternocleidomastoid. The mastoid process contains a number of small cavities called the mastoid cells that vary greatly in size and number. In the upper and anterior part of the process, these cells are large and irregular, toward the middle part they diminish in size, and those in the apex of the process frequently are small [11].

The styloid process is located underneath the opening to the external acoustic meatus and posteriorly from the mandibular fossa. It is a place for attachment muscles and ligaments, such as the stylomandibular ligament.

### **Morphological features of the temporal bone used in sex determination**

The temporal bone is one of the cranial bones which often preserves intact among skeletal remnants. Being composed mainly from the compact bone makes that do not undergo natural decomposition for a very long period of time. Its osseous structure causes that the temporal bone is resistant to physical damage and deformation. Therefore, all individual features are easily detectable and not blurred by decay process ongoing after the death.

From the utilitarian point of view the easiest way to score morphological features of the temporal bone is visual inspection of its external surface. This procedure allows differentiate male bones from females, however such method is subjective and strongly depends on the skills of researcher.

#### **Anthroposcopic traits**

The mastoid process is usually regarded as a primary sex indicator. Bigger mastoid process is typical for a male, whereas the smaller and slender appears commonly in female skull. Sexual difference in size of the mastoid process depict statement of Broca [12] and Hoshi [13] that male skulls put on the plane lie on the mastoid processes, whereas the female skulls on the occipital condyles or other parts of the basicranium. This method can be applied to uniform cranial series of the simultaneously living individuals. High intergroup variability of this feature hinder identification of sex of individuals who originate from different populations [14]. Taking into account sex determination — for the mastoid process the percent of misclassifications was lower for males than females. Length of the mastoid process shows

differences between the populations. For example African American females have larger mastoid processes than their English counterparts [15].

One of the significant dimorphic features of the temporal bone is the width of the zygomatic process. In the female skull it is thin, whereas male temporal bones have thick zygomatic process. It was proved that size of the zygomatic process is highly correlated with size of the mastoid process [16]. Another significant feature which differs male and female skulls is the posterior extension of the superior edge of the zygomatic process of the temporal bone forming supramastoid crest [17].

Qualitative aspects of sex determination, such as the size of the skull, roughness of muscular attachment, or mastoid process inclination, are commonly regarded as good indicators of sexual dimorphism. Nevertheless, methods based on morphometric analysis of the temporal bones were also developed for sex determination. Such methods are based on linear measurements performed between selected anthropological points located on the temporal bone.

### Metric traits

Majority of measurements performed on the temporal bone is based on standard landmarks what makes results comparable among different populations. Following craniometric points are used in sex determination from the skull: *porion* (po) — is the point on the human skull located at the upper margin of external acoustic meatus, *mastoidale* (ms) — the lowest point of the mastoid process and *asterion* (ast) — the meeting point of the lambdoid, occipitomastoid and parietomastoid sutures (Fig. 2).

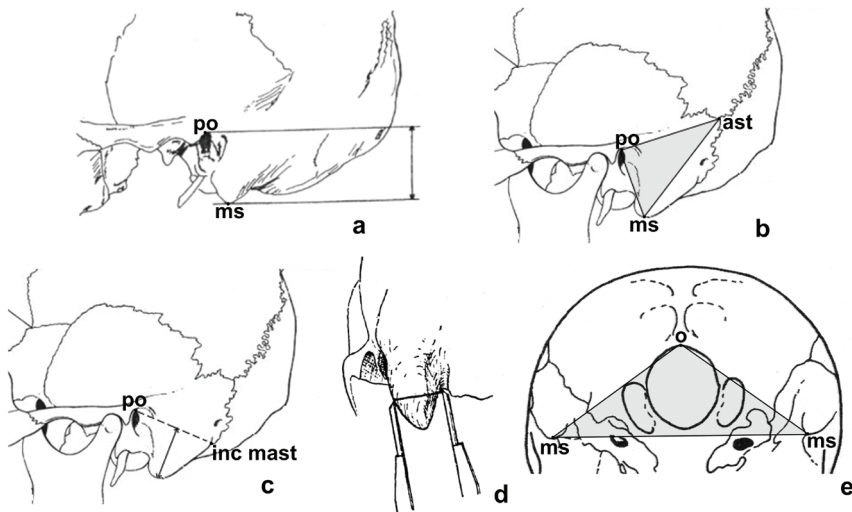


Fig. 2. Measurements of the temporal bone used for sex determination: a — height of the mastoid process (method of Giles & Eliot), b — the mastoid triangle (method of De Paiva & Segre), c — height of the mastoid process (method of Nagaoka), d — width of the mastoid process (method of Nakahashi & Nagai), e — opisthion-bimastoid triangle (method of Deepali); used abbreviations: o — opisthion; ms — mastoidale; ast — asterion; po — porion; inc mast — incisura mastoidale.

In 2003 year De Paiva and Segre [18] described that sex determination from the temporal bone can be based on measurements of the area of the triangle formed by the points porion, mastoidale and asterion. They figured out that the mastoid triangles of males tend to be greater or equal to 1447.40 mm<sup>2</sup>, while those of females tend to be lesser or equal to 1260.36 mm<sup>2</sup>. Five years later their method was verified by Galdames *et al.* [19] who analyzed craniometric traits with aid of discriminant functions of the measurements taken from 50 male skulls and 31 female skulls which belong to the collection of Museum of the Federal University of Sao Paulo (UNIFESP). Obtained results showed lesser accordance in determined sex than reported by De Paiva and Segre.

Similar study performed Kemkes and Göbel [20] who found out also significant differences between male and female mastoid triangles. Hence, their analysis revealed considerable interpopulation variation in position of the asterion what effects on size of the mastoid triangle typical for male and female skulls. Development of the mastoid part and the zygomatic process is also determined by environmental and genetic factors [21].

The method of the mastoid triangle was further developed by Deepali *et al.* [22]. These researchers used additional measurements which demarcated the opisthion-bimastoid triangle (Fig. 2). The point opisthion (o) lies on the posterior margin of the foramen magnum which is intersected by the mid-sagittal plane. Their results indicated that 80% of the crania were correctly identified by asterion-mastoid length of the right side, followed by bimastoid breadth i.e. 75%. Porion-mastoidale length (left), left mastoidale-opisthion length, right mastoidale-opisthion length and the area of the opisthion-bimastoid triangle correctly differentiates up to 70% of the cranium. The three angles of the opisthion-bimastoid triangle identify the sex between 50 and 55% only therefore these cannot be considered as reliable indicator for sex discrimination.

In turn measurements of height, width and length of the mastoid process (Fig. 2), for sexing the skull were applied by Nagaoka *et al.* [23] who used some of the techniques invented by Nakahashi and Nagai [24]. Estimated discriminant function from these measurements allowed on sex classification over 80% using a single variable, and reached 82–92% with two variables: mastoid height and width. The researchers found out that the height and the width are far more useful for sex determination than the length of the mastoid process and confirmed previous reports on variability of position of the asterion which is used as a landmark for measuring mastoid process.

More sophisticated quantitative methods of sex determination from the anatomical features of the skull are based on the geometric morphometric techniques [25]. These techniques in spite of some advantages over visual techniques and traditional morphometry can be only applied to well preserved skulls.

In 2006 year Lynnerup *et al.* [26] presented distinct method of sex determination from the temporal bone. It was based on measuring of the opening of the internal acoustic meatus in the petrous part of the temporal bone. Authors found a statistically significant difference in diameter between males and females (mean values for males = 3.7 mm and for females = 3.4 mm;  $p < 0.009$ ). This method provides only predictive value of 70% for correct sexing and, it can be used for initial analyses of fragmented skeletal remains or even cremated bones. However, for the sex determination from the cremated bones a method of the lateral angle is preferable [27].

The method of lateral angle delivers much better results if unburned bones are subjected to analysis aimed on sex determination. In this case the angle between the internal acoustic meatus and the medial surface of the petrous part of the temporal bone is measured directly on the bone casts or CT scans. The angle lesser than 45° indicate on males, while greater than 45° indicates on females [10, 28–30].

## Conclusions

Knowledge of the anatomy of the temporal bone has vastly increased the accuracy of sex determination. Experimental studies performed on the temporal bones taken from different human populations verified potential use of selected anatomical features of this bone in sex determination. Introduction of quantitative analysis of the temporal bone morphology enabled to estimate to what extent sex determination from the temporal bone is biased with the error. In spite of numerous metrical methods, size of the mastoid process is still considered to be one of the best sex discriminator. The length of the mastoid process determines area of the lateral mastoid triangle. This parameter is a background of the most valuable metric method of sex identification from the temporal bone. Methods based on the temporal bone may be supplementary used for sex determination of adult, subadult and newborn skeletons, as well as cremated remains.

## References

1. White T.D., Folkens P.A.: *The Human Bone Manual*. Elsevier. 2005.
2. Pickering R.B., Bachman D.C.: *The use of forensic anthropology*. 2<sup>nd</sup> ed. Boca Raton: CRC Press. 2009.
3. Byers S.N.: *Introduction to Forensic Anthropology* (4th Edition). Pearson. 2011.
4. Zavando M.D.A., Suazo G.I.C., Smith R.L.: Sexual dimorphism determination from the lineal dimensions of skulls. *Int J Morphol*. 2009; 27 (1): 133–137.
5. Tomaszewska I.M., Frączek P., Gomulska M., Pliczko M., Śliwińska A., Sałapa K., Chrzan R., Kowalski P., Nowakowski M., Walocho J.A.: Sex determination based on the analysis of a contemporary Polish population's palatine bones: a computed tomography study of 1,200 patients. *Folia Morphol*. 2014; 73 (4): 462–468. doi: 10.5603/FM.2014.0069.
6. Scheuer L.: Application of Osteology to Forensic Medicine. *Clin Anat*. 2002; 15 (4): 297–312. PMID: 12112359.
7. Ascádi G., Neméskeri I.: *History of Human Life Span and Mortality*. Budapest: Akademiai Kiado. 1970.
8. Buikstra J.E., Ubelaker D.H.: *Standards for Data Collection from Human Skeletal Remains*. Arkansas Archeological Survey. 1994.
9. Wahl J., Graw M.: Metric sex differentiation of the pars petrosa ossis temporalis. *Int J Legal Med*. 2001; 114 (4–5): 215–223. PMID: 11355398.
10. Norén A., Lynnerup N., Czarnetzki A., Graw M.: Lateral Angle: A Method for Sexing Using the Petrous Bone. *Am J Phys Anthropol*. 2005; 128 (2): 318–323. PMID: 15795892.
11. Som P.M., Curtin H.G.: *Head and Neck imaging*. 2003.
12. Broca P.: *Instructions craniologiques et craniometriques de la Scoieté d'Anthropologie de Paris*. 1875.
13. Hoshi H.: Sex difference in the shape of the mastoid process in norma occipitalis and its importance to sex determination of the human skull. *Okajimas Folia Anat Jpn*. 1962; 38: 309–317. PMID: 13964124.
14. Szczepanek A.: *Archeotanatologia pochówków zbiorowych od pradziejów po czasy współczesne*. 2013.

15. Walker P.L.: Sexing Skulls Using Discriminant Function Analysis of Visually Assessed Traits. *Am J Phys Anthropol.* 2008; 136 (1): 39–50. doi: 10.1002/ajpa.20776.
16. Walrath D.E., Turner P., Bruzek J.: Reliability test of the visual assessment of cranial traits for sex determination. *Am J Phys Anthropol.* 2004; 125: 132–137. PMID: 15365979.
17. Bass W.M.: 4<sup>th</sup> ed. *Human Osteology: A Laboratory and Field Manual of the Human Skeleton.* Missouri Archaeological Society. 1995.
18. De Paiva L., Segre M.: Sexing the human skull through the mastoid process. *Rev Hosp Clin Fac Med Sao Paulo.* 2003; 58 (1): 15–20. PMID: 12754585.
19. Galdames I., Matamala D., Smith R.: Sex Determination Using Mastoid Process Measurements in Brazilian Skulls. *International Journal of Morphology.* 2009; 26: 941–944.
20. Kemkes A., Göbel T.: Metric assessment of the “mastoid triangle” for sex determination: a validation study. *J Forensic Sci.* 2006; 51 (5): 985–989. PMID: 17018073.
21. Suazo G.I.C., Zavando M.D.A., Smith R.L.: Evaluating accuracy and precision in morphologic traits for sexual dimorphism in malnutrition human skull: a comparative study. *Int J Morphol.* 2008; 26 (4): 876–883.
22. Deepali J., Jasuja O.P., Surinder N.: Sex determination of human crania using Mastoid triangle and Opisthion-Bimastoid triangle. *J Forensic Leg Med.* 2013; 20 (4): 255–259. doi: 10.1016/j.jflm.2012.09.020.
23. Nagaoka T., Shizushima A., Sawada J., Tomo S., Hoshino K., Sato H., Hirata K.: Sex determination using mastoid process measurements: standards for Japanese human skeletons of the medieval and early modern periods. *Anthropological Science.* 2008; 116: 105–113.
24. Nakahashi T., Nagai M.: Sex assessment of fragmentary skeletal remains. *Journal of Anthropological Society of Nippon.* 1986; 94: 289–305.
25. Gonzalez P.N., Bernal V., Perez S.I.: Analysis of sexual dimorphism of craniofacial traits using geometric morphometric techniques. *Int J Osteoarchaeol.* 2011; 21: 82–91.
26. Lynnerup N., Schulz M., Madelung A., Graw M.: Diameter of the human internal acoustic meatus and sex determination. *Int J Osteoarchaeol.* 2006; 16: 118–123.
27. Masotti S., Succi-Leonelli E., Gualdi-Russo E.: Cremated human remains: is measurement of the lateral angle of the meatus acusticus internus a reliable method of sex determination? *Int J Legal Med.* 2013; 127 (5): 1039–1044. doi: 10.1007/s00414-013-0822-y.
28. Graw M., Wahl J., Ahlbrecht M.: Course of the meatus acusticus internus as criterion for sex differentiation. *Forensic Sci Int.* 2005; 147 (2–3): 113–117. PMID: 15567614.
29. Gonçalves D., Campanacho V., Cardoso H.F.: Reliability of the lateral angle of the internal auditory canal for sex determination of subadult skeletal remains. *J Forensic Leg Med.* 2011; 18 (3): 121–124. doi: 10.1016/j.jflm.2011.01.008.
30. Morgan J., Lynnerup N., Hoppa R.D.: The lateral angle revisited: a validation study of the reliability of the lateral angle method for sex determination using computed tomography (CT). *J Forensic Sci.* 2013; 58 (2): 443–447. doi: 10.1111/1556-4029.12090.