

## Clinical crown lengthening — a case report

WERONIKA LIPSKA<sup>1</sup>, MARCIN LIPSKI<sup>2</sup>, MAŁGORZATA LISIEWICZ<sup>3</sup>, ANDRZEJ GALA<sup>3</sup>,  
KRZYSZTOF GRONKIEWICZ<sup>3</sup>, DAGMARA DARCUK<sup>1</sup>, MARIA CHOMYSZYN-GAJEWSKA<sup>1</sup>

<sup>1</sup>Department of Periodontology and Oral Medicine, Dental Institute, Jagiellonian University Medical College  
ul. Montelupich 4, 31-155 Kraków, Poland

<sup>2</sup>Department of Anatomy, Jagiellonian University Medical College  
ul. Kopernika 12, 31-034 Kraków, Poland

<sup>3</sup>Department of Prosthodontics Jagiellonian University Medical College  
ul. Montelupich 4, 31-155 Kraków, Poland

**Corresponding author:** Dr n. med. Weronika Lipska, Department of Periodontology and Oral Medicine,  
Dental Institute, Jagiellonian University Medical College  
ul. Montelupich 4, 31-155 Kraków, Poland; Phone +48 12 424 54 20; E-mail: wmm.lipsky@gmail.com

**Abstract:** Maintaining healthy parodontium during teeth restoration procedures is an indispensable condition for obtaining regular functioning and esthetics. Thus, the knowledge of correct anatomy and the influence of filling and complement on parodontium tissue is vital. Difficulty in maintaining appropriate gingival biological width (GBW) is a frequent problem encountered in this type of reconstruction. Preservation of unchanged biological width conditions predictable treatment result and, what is more, lack of inflammatory lesions in marginal parodontium. The ideal situation for parodontium is localizing the filling/complement border supragingivally, which is at least 3 mm from alveolar process edge. In the case, when the above conditions are impossible to fulfil, elongation of clinical crown is a method of choice. The effect is possible to achieve by surgical treatment or combined orthodontic — surgical treatment. Surgical treatment is faster and preferred procedure for indirect reconstruction, where achieving high clinical crown is necessary. Three clinical cases of performing method of surgical clinical crown elongation were presented in the article. Performing the described procedure enables correct tooth crown reconstruction and, what is most important, keeping individual toothhing.

**Key words:** clinical crown lengthening, biological width, periosurgery.

### Introduction

The development of modern dentistry offers numerous methods of restoration of missing teeth. The use of advanced clinical procedures makes it possible to keep teeth once considered a poor prognosis. The increase in aesthetic expectations and the knowledge of the

rules of aesthetics obligates one to perform restorations in harmony with the arrangement of lips, face, homonymous teeth, and with preservation of a healthy periodontitis. A significant increase in the range of periodontal treatments is observed today. In addition to the treatment of periodontal diseases techniques such as recession coating, alveolar defect correction treatments, regeneration treatments, augmentation of an attached gingiva, papilla restoration techniques and change of gum level have emerged.

Maintaining a healthy periodontium during tooth reconstruction procedures is a prerequisite for obtaining aesthetics and function. For this purpose it is necessary to know the correct anatomy and the effects of fillings and prosthetic appliances on periodontium [1]. A common problem encountered with this type of restorations is the difficulty in maintaining adequate biological width. The term “biological width” (gingival biological width, GBW) means the gingival area attached to tooth surface, located coronally in relation to the alveolar ridge (Fig. 1).

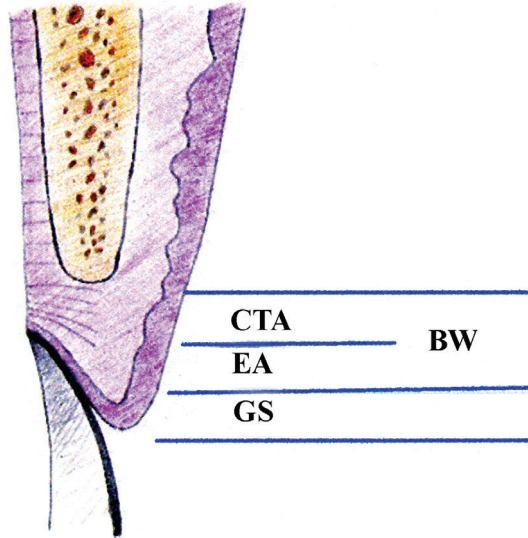


Fig. 1. The approximate value of biological width. It consists of: epithelial attachment — EA (1 mm) and connective tissue attachment — CTA (1 mm) [1, 2].

As early as in 1961 studies were performed which included the measurement of the relationship between the alveolar ridge, connective tissue attachment (CTA), epithelial attachment (EA) and the gingival sulcus (GS). They proved the average value of the epithelial attachment at 0.97 mm and the connective tissue attachment at 1.07 mm. Biological width was calculated as:  $GBW = CTA + EA = 2.04$  mm [3, 4]. Subsequent studies have confirmed a certain stability of the measurement of connective tissue attachment and the average value of biological width: 2 mm [3, 5]. This value can vary with the age, movement of teeth or orthodontic treatment. It was shown that the 2 mm biological width is present in 85% of

the population, in approximately 13% of the population the value is higher and in approximately 2% of the population it is less than 2 mm [6, 7]. In order to precisely determine biological width one must carry out an individual measurement under local anaesthesia, from the edge of the alveolar process to the edge of the gum, passing through the epithelial and connective tissue attachments. The accuracy of measurement is affected by the biotype of the gum, the presence of recessions, the shape of root surface, bone dehiscence and the thickness of alveolar bone [8].

The relative stability of biological width makes any interference in this area cause a defensive reaction of the body and an attempt to restore these relations (Fig. 2).

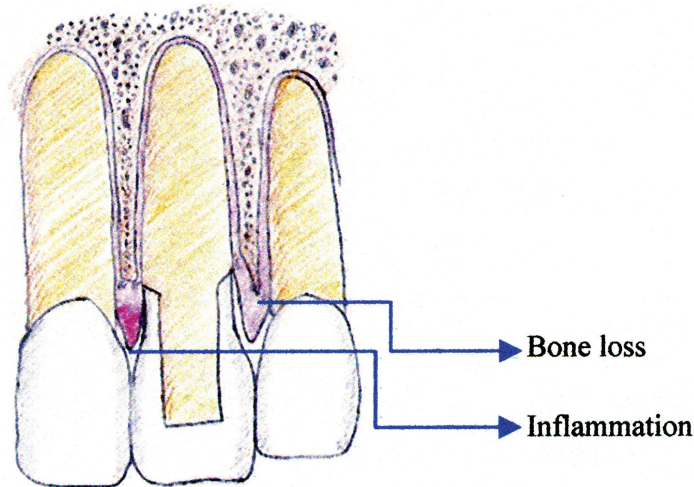


Fig. 2. The consequences of infringing the biological width by badly performed prosthetic reconstruction. On the mesial surface of incisor there is no bone loss and an inflammation is present. On the distal surface, biological width has been restored by way of bone resorption.

The consequences can be different and they are generally related to the biotype of the gum. In both cases, this can lead to retraction of the gum and creation of periodontal pockets. This is the result of bone and attachment loss as a result of inflammation. Thin gingival biotype is characterized by faster horizontal bone resorption. Good oral hygiene stops the inflammatory process and only a recession is formed. Plaque supports this process and there is further bone resorption and formation of periodontal pockets. Thick gingival biotype is a predisposition towards less frequent retraction of the gum and slower bone resorption, but bone defects and adverse remodelling of the bone occurs more often here. This results in impaired cleaning potentiality, formation of periodontal pockets, as well as root caries, exposing the furcation, loosening and loss of the tooth (Fig. 3).

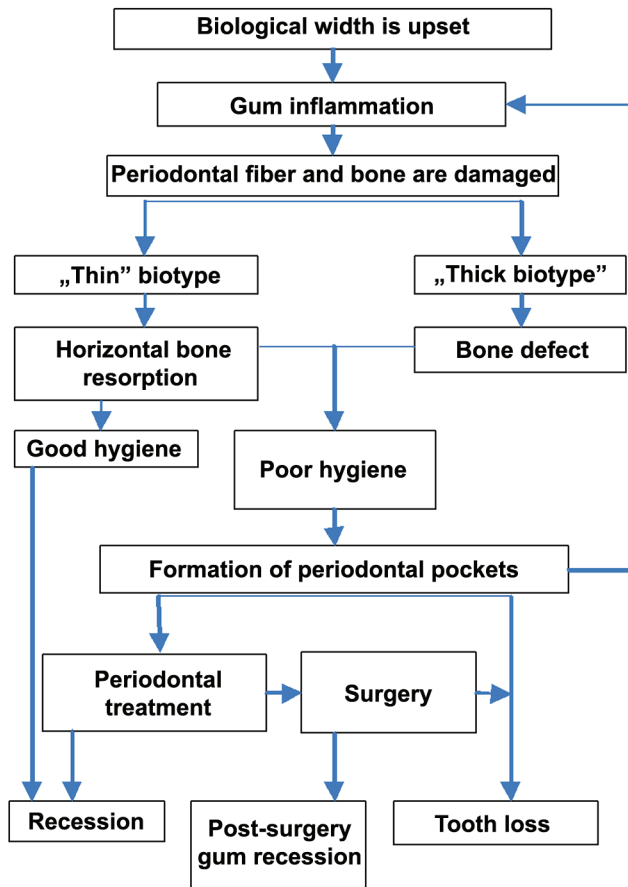


Fig. 3. Diagram showing tissue response and the possible reaction to an upset biological width.

To avoid pathological lesions and obtain predictable outcomes of treatment it is necessary to maintain unchanged biological width [2, 3, 7]. The ideal situation for periodontitis is to locate the border of filling/restoration supragingivally, and therefore at least 3 mm from the alveolar ridge. In the aesthetic zone, where the polishing limit is located subgingivally, the following rules must be observed:

- if  $GS \leq 1.5$  mm, the limit of filling may be located 0.5 mm subgingivally
- if GS is 1.5–2 mm, the limit of filling may be located 0.7 mm subgingivally
- if  $GS > 2$  mm, the limit of filling may be located 0.5 mm subgingivally [2, 3].

If the distance of the expected filling limit from the edge of the bone violates the preservation of biological width, the treatment plan should take into account a clinical crown lengthening surgery. Typical indications for clinical crown lengthening are:

- subgingival tooth fracture
- carious loss located subgingivally
- the presence of a short crown, not providing sufficient retention of prosthetic restoration

- uneven course of the gingival garland
- gingival overgrowth obscuring visibility of anatomical crown
- shortening of tooth crowns in the course of pathological abrasion
- perforations during endodontic or prosthetic treatment
- root resorption
- disorder of tooth eruption (delayed passive eruption) [3, 6].

Lengthening of clinical crown can be achieved by surgery alone, or by combined orthodontic and surgical treatment. Surgical treatment is a faster procedure, preferable for intermediate reconstruction of a tooth, where it is necessary to achieve high clinical crown. The procedure involving a bone resection may adversely affect its prognosis because of the risks of:

- weakened keeping of the tooth
- uncovering of furcation
- obtaining an unfavourable relation of the crown to the root
- periodontal damage to an adjacent tooth
- adverse aesthetic effect (recessions, disruption of the course of the gingival garland, loss of the papilla and opening of interdental space, asymmetry of crown length in relation to adjacent teeth).

These risks must be taken into account already when planning treatment [3].

Procedures of lengthening clinical crowns are divided into two categories, depending on the need for osteotomy.

#### I Gum reduction

##### A. Gingivectomy

##### B. Apical displacement of the flap

#### II Ostectomy with full thickness of flap

##### A. one-step procedures:

1. flap-ostectomy-apical displacement
2. flap-ostectomy-gingivectomy-repositioning
3. gingivectomy-flap-ostectomy-repositioning

##### B. two-step procedure: flap-ostectomy-repositioning-gingivectomy after 4–6 weeks [1, 3].

## Case study

### Case 1

Patient A.S., aged 25 years, referred for periodontal consultation from the Prosthodontics Clinic. Tooth 15 after subgingival fracture of the crown, with significant destruction of hard tissue (Fig. 3) and after endodontic treatment. Underfilled root canal can be seen radiographically (Fig 4).

Treatment plan was prepared, comprising: endodontic retreatment, surgical lengthening of clinical crown and prosthetic reconstruction with the use of individual cast post and prosthetic crown. This treatment plan was accepted by the patient. After completion of re-endodontic treatment the lengthening of clinical crown procedure was performed (Fig. 5). A wide area of gum attached on the buccal surface, distance from the edge of the fracture

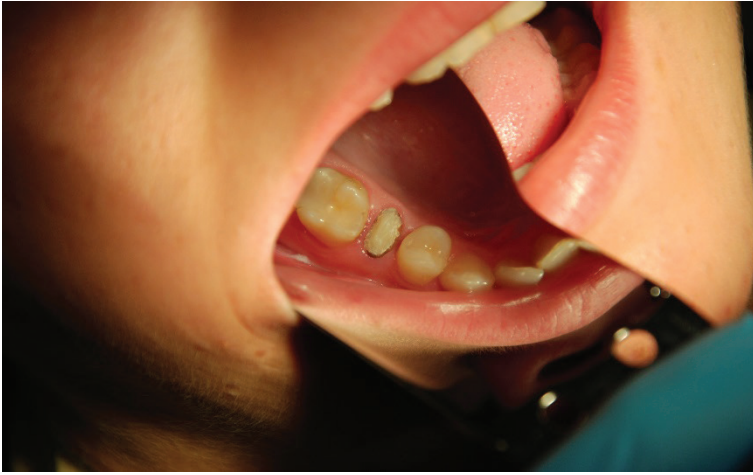

Fig. 3. Clinical tests.

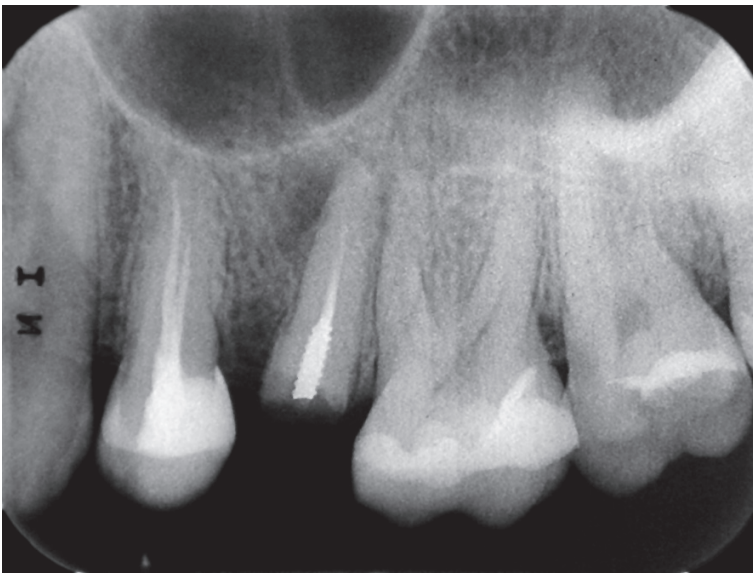


Fig. 4. Radiographic tests.

to the alveolar process  $<3$  mm (palatally and mesially). The surgery with the procedures of producing a full-thickness flap, gingivectomy, ostectomy and reposition was performed under Scandonest infiltration anaesthesia. The wound was secured with non-resorbable sutures and Solcoseryl healing paste. At a follow-up visit after 7 days the wound was found to heal normally and the sutures were removed (Fig. 6). After 6 weeks work on the final prosthetic reconstruction was started.

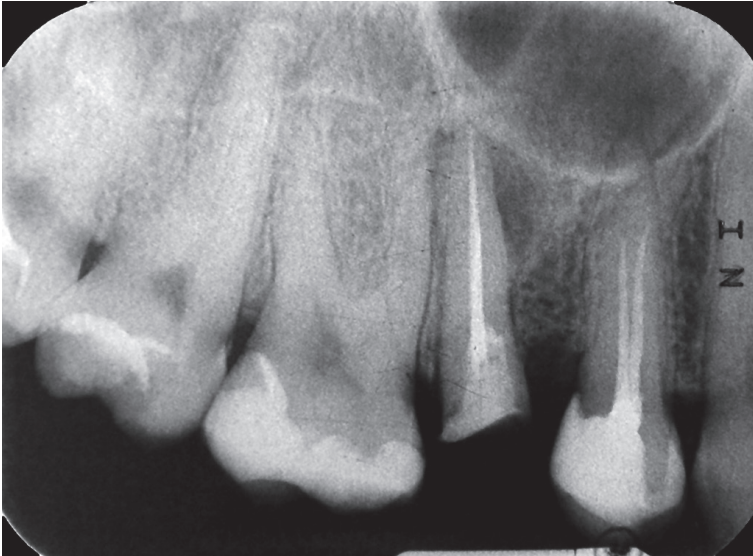

Fig. 5. X-ray image taken after the completion of endodontic treatment.

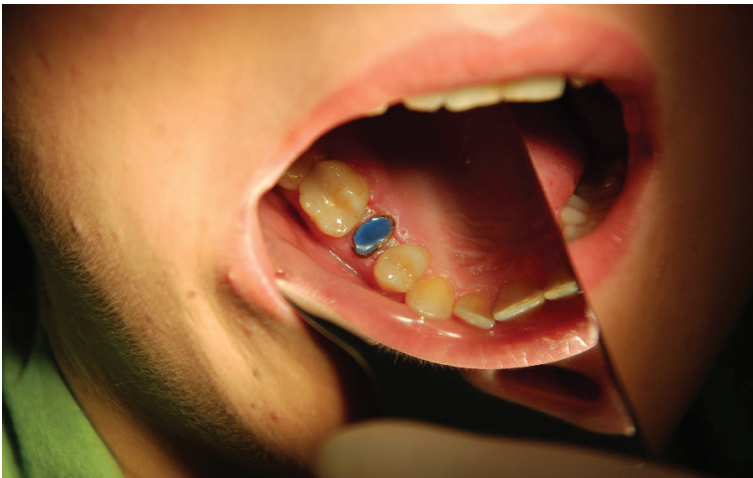

Fig. 6. Visit following the removal of sutures.

### Case 2

Patient B.Ch, aged 27, referred for periodontal consultation. Tooth 25 with a significant loss of hard tissue due to root caries on the palatal side (Fig. 7). Underfilled root canal can be seen radiographically, standard cast post. The root post was removed at the Prosthodontics Clinic. Due to the inability to keep the treatment area clear from saliva in order to carry

out the re-endodontic treatment, performance of the surgical lengthening of the clinical crown was scheduled first.

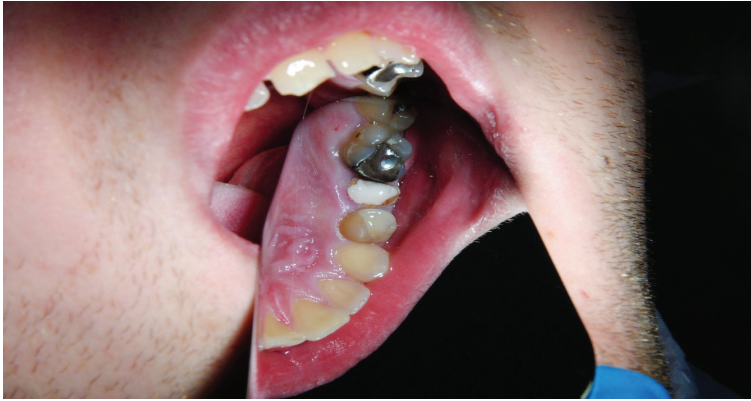

Fig. 7. Image prior to surgery. A cavity extending subgingivally, inflammatory reaction of the gingiva on the palatal side.

The distance to the edge of the tooth cavity from the edge of the bone  $<3$  mm in the palatal and palatal-mesial area. Gingivectomy, ostectomy in the palatal and mesial area and reposition of full-thickness flap were carried out under Scandonest infiltration anaesthesia. The wound was secured with non-resorbable sutures and Solcoseryl healing paste (Fig. 8). At a follow-up visit after 7 days the sutures were removed. Healing by granulation was found in the interdental spaces (Fig. 9). The patient was referred for endodontic retreatment.

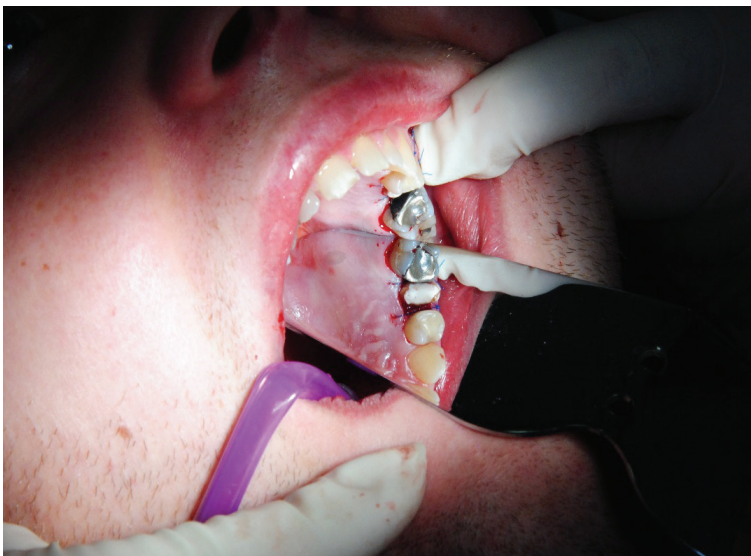

Fig. 8. Condition after surgery.



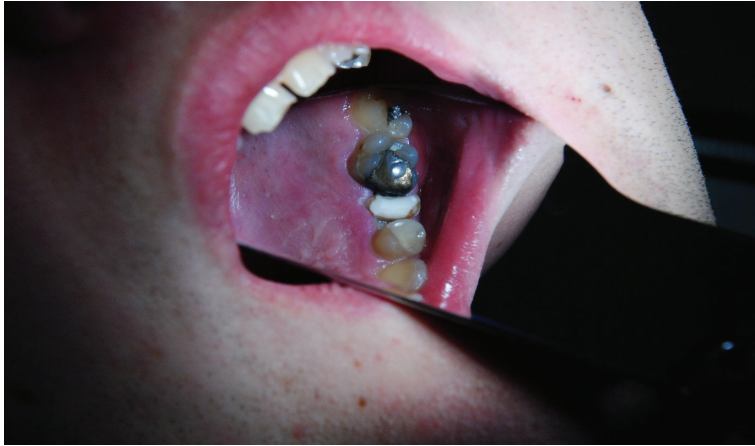

Fig. 9. Image of healing at the follow-up visit after 7 days.

### Case 3

Patient E.Z, aged 68 years, referred for periodontal consultation from the Prosthodontics Clinic. Tooth 26 with extensive composite filling and subgingival fracture of the palatal wall (Fig. 10). Because of the depth of the fracture reconstruction of the tooth with preservation of the biological width was found impossible. Radiographic image of the condition after endodontic treatment (Fig. 11).

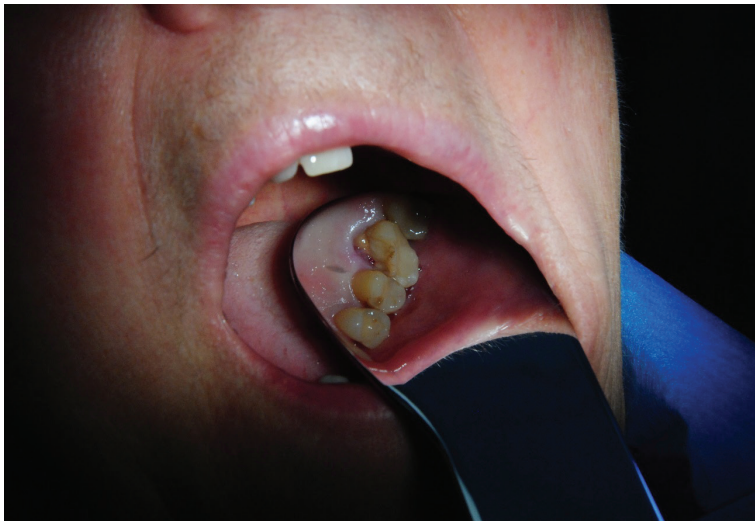

Fig. 10. Fracture of the palatal wall of tooth 26 can be seen.

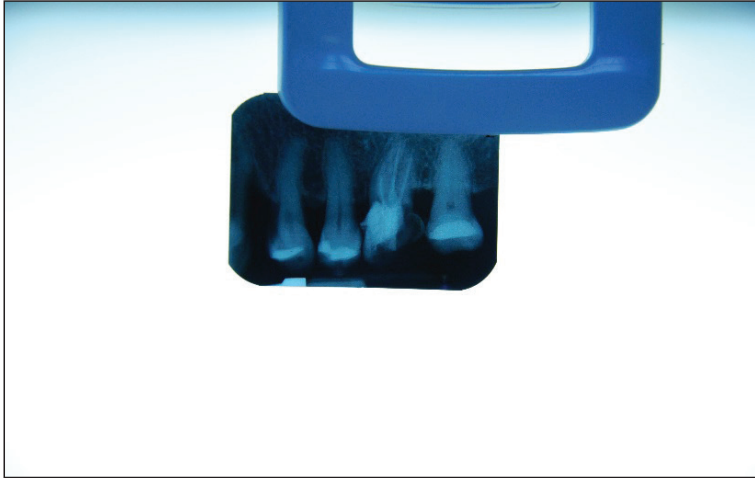

Fig. 11. Radiographic image of the endodontic treatment performed.

Clinical crown lengthening surgery and prosthetic reconstruction in the second stage were proposed. Gingivectomy and ostectomy procedure in the palatal-mesial area with full-thickness flap repositioning were carried out under Mepidont 3% infiltration and conduction anaesthesia. The wound was sutured. The sutures were removed after 7 days. Plaque control and further prosthetic treatment were recommended (Fig. 12).

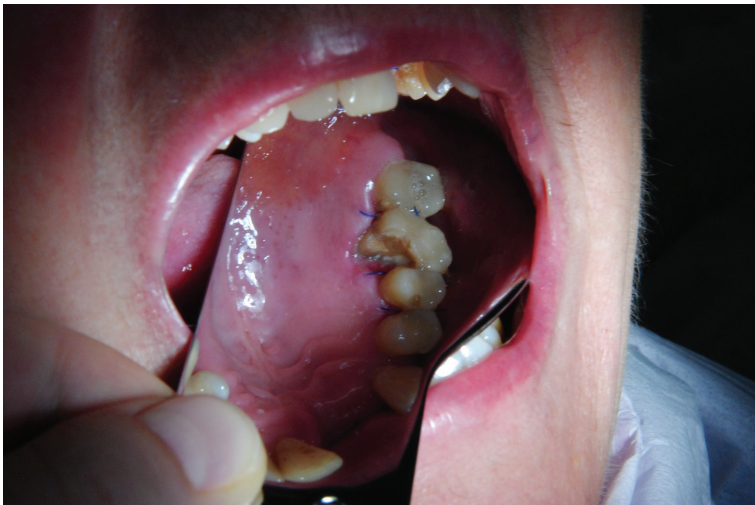

Fig. 12. Condition after 7 days.

## Summary

There are two primary indications for clinical crown lengthening surgery. The first one is an aesthetic indication for increasing the length of clinical crowns. The second indication, and the most common, as practice shows, is the positioning of the tooth preparation border supragingivally or gingivally, in order to avoid the negative impact of dental restorations on the biological width, resulting in chronic inflammation of the periodontium around the applied prosthetic restoration [9]. In addition, supragingival or gingival border of tooth hard tissue preparation creates the right conditions for adhesive cementation. This is particularly important for all-ceramic restorations requiring that treatment area is kept clean and dry during the procedure of adhesive deposition of dental restorations. Lengthening of clinical crowns of teeth is one of the most frequently performed periodontal treatments carried out as part of pre-prosthetic procedure [10–12].

## References

1. *Sonick M.*: Esthetic crown lengthening for maxillary anterior teeth. *Compend Contin Educ Dent.* 1997; 18 (8): 807–819.
2. *Zucchelli G., Mazzotti C., Monaco C.*: A standardized approach for the early restorative phase after esthetic crown-lengthening surgery. *Int J Periodontics Restorative Dent.* 2015; 35 (5): 601–611.
3. *Planciunas L., Puriene A., Mackeviciene G.*: Surgical lengthening of the clinical tooth crown. *Stomatologija.* 2006; 8: 88–95.
4. *Gargiulo A., Wentz F., Orban B.*: Dimensions and relations of the dentogingival junction in humans. *J Periodontol.* 1961, 32: 261–267.
5. *Vacek J., Gerhr M., Asad D., Richardson A., Giambarresi L.*: The dimensions of the human dentogingival junction. *Int J of Periodontics Restorative Dent.* 1994; 14: 154–165.
6. *Camargo P., Melnick P.R., Camargo L.M.*: Clinical crown lengthening in the esthetic zone. *J Calif Dent Assoc.* 2007; 35 (7): 487–498.
7. *Kois J.*: The restorative-periodontal interface: biological parameters. *Periodontol.* 2000, 1996; 11: 29–38.
8. *Lee E.*: Aesthetic crown lengthening: classification, biologic rationale and treatment planning considerations. *Pract Proced Aesthet Dent.* 2004; 16 (10): 769–778.
9. *Bajaj P., Chordiya R., Rudagi K., Patil N.*: Multidisciplinary approach to the management of complicated crown-root fracture: a case report. *Int Oral Health.* 2015; 7 (4): 88–91.
10. *Tomar N., Bansal T., Bhandari M., Sharma A.*: The perio-esthetic-restorative approach for anterior rehabilitation. *J Indian Soc Periodontol.* 2013; 17 (4): 535–538.
11. *Parwani S.R., Parwani R.N.*: Surgical crown lengthening: a periodontal and restorative interdisciplinary approach. *Gen Dent.* 2014; 62 (6): 15–19.
12. *Patel R.M., Baker P.*: Functional crown lengthening surgery in the aesthetic zone; periodontic and prosthodontic considerations. *Dent Update.* 2015; 42 (1): 36–38, 41–42.