

DOI 10.2478/pjvs-2014-0076

Short communication

Effect of 24 hour application of three hemostatic dressings to porcine thigh muscles

Z. Adamiak¹, P. Jastrzębski², A. Pomianowski³, I. Otrocka-Domagala⁴,
P. Holak¹, Y. Zhalniarovich¹, P. Przyborowska¹, J. Głodek¹

¹ Department of Surgery and Radiology, University of Warmia and Mazury,
Oczapowskiego 14, 10-719 Olsztyn, Poland

² Security Fundamentals Unit, Police Academy, Piłsudskiego 111, 12-100 Szczytno, Poland

³ Department of Internal Diseases, University of Warmia and Mazury, Oczapowskiego 14, 10-719 Olsztyn, Poland

⁴ Department of Pathological Anatomy, University of Warmia and Mazury,
Oczapowskiego 13 bl. D, 10-719 Olsztyn, Poland

Abstract

The effectiveness of three types of hemostatic dressings, QuikClot Gauze, ChitoGauze PRO and Celox Gauze, was evaluated in nine pigs. The results indicated a strong influence of all examined dressings on porcine femoral muscle tissue evaluated 24 hours after direct contact. A histopathological analysis revealed pathological changes in muscle tissue specimens collected from all the animals.

Key words: hemostatic dressings, pig, QuikClot Gauze, ChitoGauze PRO, Celox Gauze

Introduction

Hemorrhaging from large blood vessels requires immediate and effective medical attention. The response of soft tissues surrounding the wound to the application of a hemostatic dressing for 24 hours and longer should be determined to maximize treatment efficacy. The objective of this study was to determine the response of porcine muscle tissues surrounding a damaged blood vessel to direct contact with selected hemostatic dressings for 24 hours.

Materials and Methods

The experiment was approved by the local ethics committee. The experimental animals were handled in accordance with the provisions of the Guide for the Care and Use of Laboratory Animals.

The experiment was performed on nine Polish Large White female pigs with a body weight of 30 kg which were divided into three equal groups. QuikClot Gauze (Emergo Europe, NI) hemostatic dressing was applied in the first group, ChitoGauze PRO (Hem-

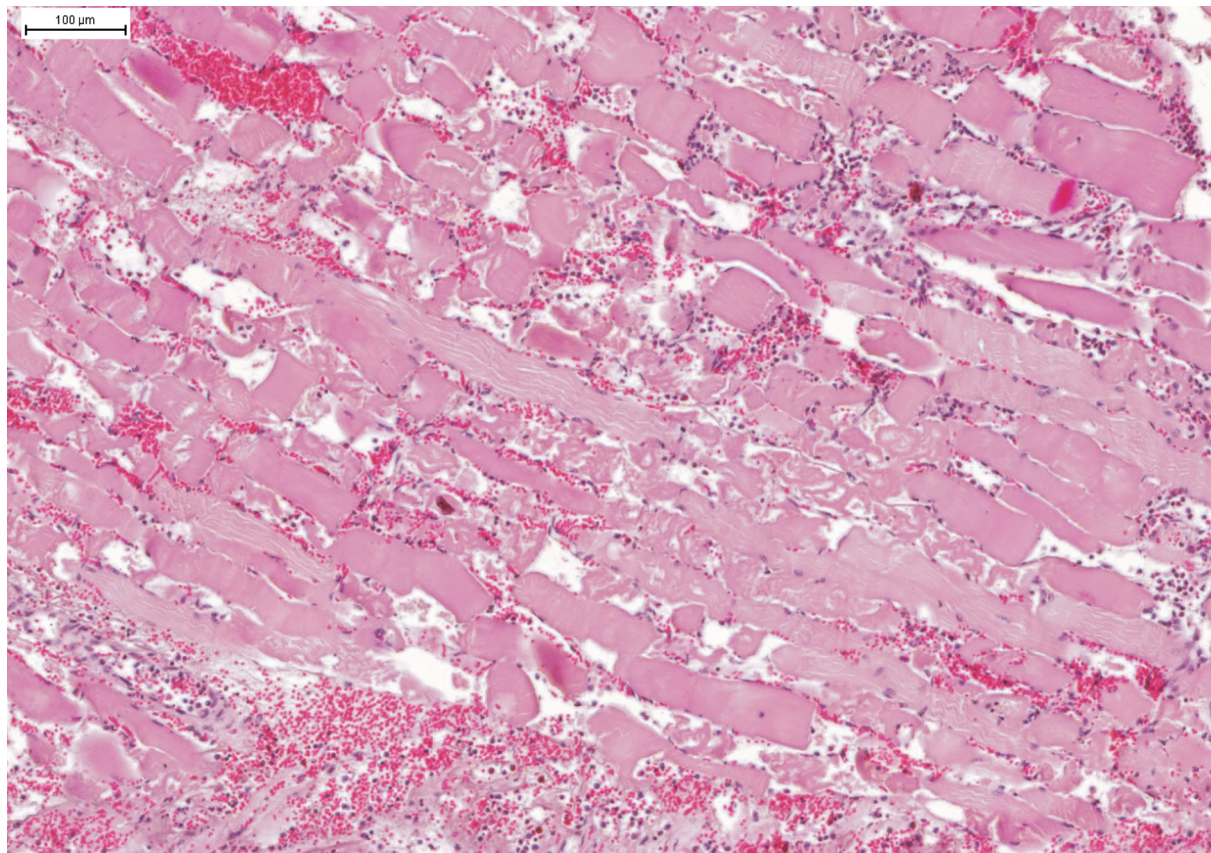


Fig. 1. Histopathological changes in muscle tissue after the application of ChitoGauze PRO in transverse view.

ConMedical Technologies, Inc., USA) was used in the second group, and Celox Gauze (Med Trade Products, UK) was applied in the third group. The animals were premedicated with azaperone (Stresnil) at 2.0 mg/kg BW IM and atropine (Atropinum Sulfuricum, Polfa S.A., Warszawa) at 0.05 mg/kg BW IM and Butorphanol (Butomidol, Rihterfarma ag, Vien) at 0.2 mg/kg BW IV. General anesthesia was induced with ketamine (Bioketan, Biowet, Puławy) at 8 mg/kg BW IM and maintained with thiopental IV to effect. The left femoral artery was injured at groin level. A transverse incision was made across the entire femoral artery. The selected hemostatic dressing was applied to the wound and compressed manually for 3 to 5 minutes. The wound, with hemostatic dressing inside, was closed with a continuous suture. The animals were euthanized 25 hours after the application of the hemostatic agent. The collected tissue specimens were fixed in buffered 10% formalin and embedded in paraffin. The paraffin sections (5 μm) were routinely stained with hematoxylin and eosin (HE). The effect of staining was evaluated in specimens scanned in a digital histology slide scanner (3DHISTECH, Hungary).

Results

The applied dressings effectively controlled bleeding from the femoral artery in all patients and none of them died during the observation period.

Histopathological examinations of tissue samples collected from groups I and II revealed multifocal segmental hypercontraction, hyaline degeneration, coagulation necrosis and fragmentation of muscle fiber cytoplasm with subsequent infiltration of neutrophils and macrophages, arterial and venous thrombi, and perivascular hemorrhages (Fig. 1). The following changes were observed in muscle tissue samples obtained from Celox Gauze group as well.

Discussion

The main objective of hemostatic dressings is to control hemorrhaging until the damaged vessel can be surgically treated. In most cases, the time between dressing application and surgical treatment ranges from several dozen to several hundred minutes.

Dressings are removed when the patient is trans-

ported to a medical facility where surgery can be performed. King (2011), described cases where hemostatic dressings had been removed from human wounds 25-60 minutes after application in the battlefield. In a study evaluating 10 hemostatic dressings applied to control bleeding from injured femoral arteries, Arnaud et al. (2009) described the effects of applying dressings for 180 minutes to tissues in the area of the damaged vessel. Several studies demonstrated that QuikClot powder is capable of producing exothermic reactions (McManus et al. 2007, Arnaud et al. 2008, Rhee et al. 2008, Devlin et al. 2011)

This experiment evaluated the effect of QuikClot Gauze, ChitoGauze PRO and Celox Gauze hemostatic dressings on skeletal muscles that remained in direct contact with the dressings for 24 hours. In all cases, segmental damage to muscle tissue was observed, mainly in the form of hypercontraction, hyaline degeneration and fragmentation of muscle fiber cytoplasm, with subsequent infiltration of neutrophils and macrophages. In the Celox Gauze group, necrosis of muscle fibers was less intense, whereas severe skeletal muscle injury was noted in the ChitoGauze PRO group. The noted changes could result from exothermic reactions triggered by the hemostatic dressing. The results of this study can contribute to a future

search for hemostatic dressings which are safe for soft tissues surrounding injured blood vessels.

References

- Arnaud F, Teranishi K, Tomori T, Carr W, McCarron R (2009) Comparison of 10 hemostatic dressings in a groin puncture model in swine. *J Vasc Surg* 50: 632-639.
- Arnaud F, Tomori T, Carr W, McKeague A, Teranishi K, Prusaczyk K, McCarron R (2008) Exothermic reaction in zeolite hemostatic dressings: QuikClot ACS and ACS +. *Ann Biomed Eng* 36: 1708-1713.
- Devlin JJ, Kircher S, Kozen BG, Littlejohn LF, Johnson AS (2011) Comparison of ChitoFlex®, Celox™, and QuikClot® in control of hemorrhage. *J Emerg Med* 41: 237-245.
- King DR (2011) Thirty consecutive uses of a hemostatic bandage at a US Army Combat Support Hospital and forward Surgical Team in Operation Iraqi Freedom. *J Trauma* 71: 1775-1778.
- McManus J, Hurtado T, Pusateri A, Knoop KJ (2007) A case series describing thermal injury resulting from zeolite use for hemorrhage control in combat operations. *Prehosp Emerg Care* 11: 67-71.
- Rhee P, Brown C, Martin M, Salim A, Plurad D, Green D, Chambers L, Demetriades D, Velmahos G, Alam H (2008) QuikClot use in trauma for hemorrhage control: case series of 103 documented uses. *J Trauma* 64: 1093-1099.